Netherlands
The Journal of Medicine

REVIEW

Clostridium perfringens septicaemia with massive intravascular haemolysis: a case report and review of the literature

C.C. van Bunderen[1], M.K. Bomers[1], E. Wesdorp[2], P. Peerbooms[3], J. Veenstra[1*]

Departments of [1]Internal Medicine, [2]Gastroenterology, [3]Microbiology, Sint Lucas Andreas Hospital, Amsterdam, the Netherlands, *corresponding author: tel.: +31 (0)20-510 89 11, fax: +31 (0)20-683 87 71, e-mail: j.veenstra@slaz.nl

ABSTRACT

We describe the case of a 74-year-old man with cholangitis, complicated by *Clostridium perfringens* septicaemia and massive intravascular haemolysis. *Clostridium perfringens* septicaemia is a rare but well-known cause of massive intravascular haemolysis. Here we review 40 similar cases published since 1990. Most cases involve immunocompromised patients with underlying haematological disorder (22.5%), pancreatic or gastric cancer (12.5%) and/or diabetes (30.0%). Focus of infection is mostly hepatobiliary (45.0%), intestinal or gynaecological after invasive procedure. Eighty percent of reviewed cases did not survive; the median time between admission and death was only eight hours. If an attempt was made to remove the focus of infection (i.e. by drainage of liver abscess, cholecystectomy, hysterectomy or ERCP), this proved to be a strong prognostic indicator of survival. However, in many of the cases the patient had already gone into shock or died before a diagnosis could be made. In severely ill patients with fever and haemolysis on the emergency department *Clostridium perfringens* septicaemia should always be considered, since early antibiotic treatment and if possible removal of the focus of infection can rescue patients from an otherwise fatal outcome.

KEYWORDS

Cholangitis, *Clostridium perfringens*, massive intravascular haemolysis

INTRODUCTION

'This is a disease that begins where other diseases end, with death.'[1]

Clostridium perfringens is capable of inducing a wide variety of clinical manifestations, ranging from asymptomatic patients with an incidental positive blood culture to full-blown infection and death.[2] *C. perfringens* septicaemia is a rare but life-threatening cause of massive intravascular haemolysis. Early recognition and antibiotic therapy is essential to avert an otherwise fatal outcome. We present the case of a patient with massive haemolysis as a result of *C. perfringens* infection and review similar cases published since 1990.

CASE

A previously healthy 74-year-old male was admitted to our hospital because of a six-day history of fever, nausea and vomiting. On arrival at the hospital he appeared ill. His temperature was 40.2 °C, his blood pressure was 171/88 mmHg and he was jaundiced with a tenderness of the upper abdomen. The haemoglobin (Hb) level was 9.8 g/dl (normal range (NR): 13.7 to 17.7 g/dl), haematocrit (Ht) 28% (NR: 40 to 50%), mean cell volume (MCV) 90 fl (NR: 80 to 100 fl), reticulocytes 1.4% (NR: 0.5 to 1.5%), white blood cell (WBC) count 29.8 × 10.9/l (NR: 4 to 10 x 10.9/l) (8% band cells) and platelets 140 × 10.9/l (NR: 150 to 400 x 10.9/l). Other laboratory results included the following: creatinine 3.1 mg/dl (NR: 0.5 to 1.3 mg/dl), serum aspartate transaminase (ASAT) 419 U/l (NR: <35 U/l), serum alanine transaminase (ALAT) 261 U/l (NR: <40 U/l), lactate dehydrogenase (LDH) 2300 U/l (NR: <250U/l), alkaline phosphatase (ALP) 271 U/l (NR: <120 U/l), total bilirubin 23.7 mg/dl (NR: 0.2 to 1 mg/dl),

direct bilirubin 14.6 mg/dl, γ-glutamyltransferase (γGT) 348 U/l (NR: <55 U/l), and creatinine phosphokinase (CK) 107 U/l (NR: <170 U/l).

An ultrasound of the upper abdomen showed sludge and gallstones in the gallbladder without dilatation of the hepatobiliary tree. Computed tomography (CT) of the abdomen revealed no abnormalities. Since no other focus of infection was found, cholangitis was thought to be the origin of sepsis in this severely ill patient. Broad spectrum antibiotics were administered (amoxicillin 6 g/24 h, gentamicin 5 mg/kg) and endoscopic retrograde cholangiopancreaticography (ERCP) was performed. A dilated choledochus duct appeared without stones. After papillotomy impacted bile was seen, but no stones could be removed. In the hours following admission haemoglobin levels decreased to 7.9 g/dl with low haptoglobin (0.1 g/l) (NR: 0.3 to 2.0 g/l) and a negative direct antiglobulin test. Furthermore, haemoglobinuria occurred suggesting intravascular haemolysis. A peripheral blood smear showed spherocytes (*figure 1*). The following day, gas formation was observed in both blood culture bottles. Gram stain revealed large gram-positive rods that were subsequently identified as C. *perfringens*. Since biliary sepsis is usually polymicrobial, we chose to add metronidazole to the antibiotic regimen rather than to narrow therapy to penicillin only.

In conclusion our patient suffered from cholangitis, complicated by *C. perfringens* septicaemia and intravascular haemolysis. In the days following admission his renal function deteriorated, temporarily requiring haemodialysis, yet his condition stabilised and haemolysis ended. Three weeks later he had recovered sufficiently to be discharged with a remaining glomerular flitration rate (GFR) of 33 ml/min.

Figure 1. *Peripheral blood film showing spherocytes*

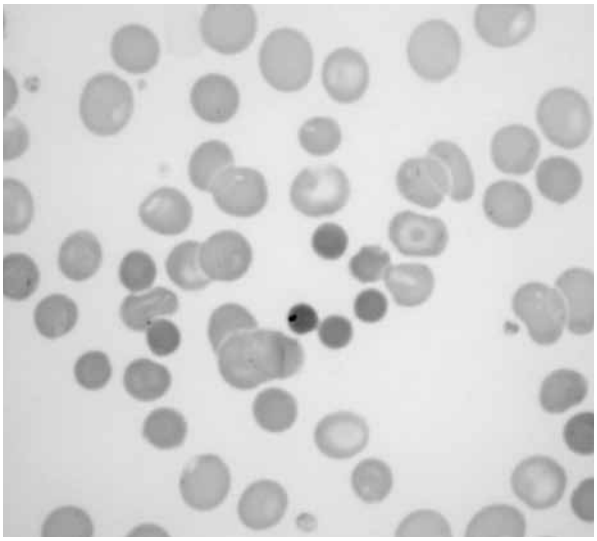

RESULTS AND DISCUSSION

C. perfringens, an anaerobic, gram-positive rod, is a normal inhabitant of the human bowel and genital tract. *C. perfringens* septicaemia is an uncommon but almost invariably fatal condition following clostridial infection mostly from the uterus, colon or biliary tract. In general this occurs in patients with underlying malignancy or diabetes mellitus, or in otherwise healthy individuals with recent abdominal surgery or following abortion.

Massive intravascular haemolysis is a rare but well-known complication of *C. perfringens* septicaemia occurring in 7 to 15% of *C. perfringens* bacteraemias.[3-5] Recently, the current insights into the pathogenesis of bacterial sepsis were reviewed in this journal.[6] Alpha-toxin induced haemolysis is an additional prominent factor in the pathogenesis of *C. perfringens* sepsis. Alpha-toxin can damage the structural integrity of the red cell membrane by means of phospholipase activity.[2] This leads to spherocytosis and subsequent haemolysis. Besides spherocytes a blood smear can show ghost cells, which appear empty because they have a leaky membrane and no longer contain haemoglobin. Alpha-toxin is also the key virulence factor by inducing gas gangrene (or clostridial myonecrosis) in *C. perfringens* infection.[2,7]

The treatment of choice for *C. perfringens* bacteraemia is intravenously administered high-dose penicillin and surgical debridement of all involved gangrenous tissue, which is thought to be crucial in minimising production of toxins. In this case ERCP might have had a comparable effect to surgical debridement, by evacuating and therefore limiting the focus of infection.

We reviewed all 40 cases of *C. perfringens* septicaemia complicated by massive haemolysis published in the English literature since 1990 (*table 1*). Reported cases had a median age of 65 years (range 29 to 84) and 55% were male. No underlying condition was found in 15 of the 40 cases (37.5%); nine (22.5%) had a haematological disorder; five (12.5%) had either pancreatic or gastric cancer; there were two dialysis patients (5.0%) and two liver transplant recipients (5.0%). Diabetes was the only underlying disease in six patients (15.0%), overall 12 of the 40 cases (30.0%) were diabetic. The mean haemoglobin and haematocrit at presentation were 8.9 g/dl (standard deviation (SD) 3.3) and 21.3% (SD 12.1) respectively. Numerous cases mention a second measurement of haemoglobin or haematocrit within 24 hours of admission: in >80% this is less than half of the first blood sample.

Only eight of the 40 patients survived (mortality rate 80%); median time between admission and death was eight hours (range 0 to 96). Focus of infection was unknown in 11 cases (27.5%), hepatobiliary in 18 (45%), intestinal/abdominal in seven (17.5%) or uterine after invasive procedure in four (10%) cases. In eight cases an

Table 1. *Cases of C. perfringens septicaemia and haemolysis published since 1990*

	Author	Year	Age	Sex	Underlying disease	Origin infection	Focus removed	Hb (g/dl)	Ht (%)	WBCs (x10.9/l)	LDH (U/l)	Bili. (mg/dl)	Survival	Hours admission-death
1	Batge	1992	61	M	Pancreatic cancer	Liver abscess	Yes	11.6	32	38.2	7600	44	Yes	
2	Ifthikaruddin	1992	54	F	AML	Unknown	No	10.6		0.8			No	11
3	Hubl	1993	84	F	None	Intestinal	No	10.8	32	16.5	1344	21	No	3
4	Rogstad	1993	61	M	None	Micro abscesses liver	No						No	3
5	Clarke	1994	53	F	None	Necrotising enteritis	Yes	14.5		14		7	Yes	
6	Meyerhoff	1995	66	F	None	Unknown	No		10	28		36.7	No	9
7	Gutierrez	1995	74	M	None	Micro abscesses liver	No	13.1	41	19.8	1250	4.1	No	6
8	Jones	1996	66	F	Liver transplant	Liver abscess	No	11.3		11.2		2.5	No	10
9	Pun	1996	74	M	None	Cholecystitis	No		5	43.6			No	22
10	Bush	1996	58	F	DM	Biliary	No		26.6			9.9	Yes	
11	Singh	1996	73	F	CLL	Unknown	No		0				No	0
12	Singer	1997	55	F	Hodgkin's lymphoma	Unknown	No	3.4	0	0.2	4503	7.9	No	4
13	Alvarez	1999	77	F	None	Abdominal	No	4.8	7	25.6	14255	43.1	No	4
14	Thomas	1999	73	M	DM	Cholecystitis	Yes		33	39	3430	13.8	Yes	
15	Barrett	2002	NR	F	None	Septic abortion	Yes	8.7	23.6	29.7		12	No	NR
16	Halpin	2002	29	F	None	Postcaes. endometritis	Yes		22	28.9		17	Yes	
17	Jimenez	2002	79	M	Pancreatic cancer	Unknown	No	9	25	40	19000	10	No	96
18	Hamoda	2002	39	F	None	Postamn. endometritis	Yes	12.7		23.5		4.1	Yes	
19	Kreidl	2002	80	M	Dialysis	Liver abscess	No		32.1	29		12.6	No	11
20	Vaiopoulos	2004	74	M	AML	Intestinal and biliary	No		21.6				No	20
21	Au	2005	65	M	Dialysis	Liver abscess	No	6.2		25			No	72
22	Pirrotta	2005	50	M	ALL	Unknown	No	3.5					No	4
23	Rodriguez	2005	57	M	Gastric cancer	Biliary	No	5.3	17.1			9.4	No	9.4
24	Kwon	2006	71	F	Pancytopenia	Unknown	No	2.2	1.4	6.2		9.7	No	2
25	Ohtani	2006	78	M	DM	Liver abscess	No	10	21.6	18.6	51382	1.4	No	3
26	McArthur	2006	49	M	Pancreatic cancer	Abdominal	No		6	1			No	1.5
27	Loran	2006	69	F	None	Liver abscess	No	8.7		26			No	6
28	Leeda	2006	59	M	Pancreatic cancer	Postop. intestinal leak	No	6		23.2			No	40
29	Eigenberger	2006	60	M	Liver transplant	Liver abscess	No	8.5		42.5		31.6	No	8
30	Daly	2006	80	M	DM	Liver abscess	No	8.7					No	3
31	Poulou	2007	74	M	DM	Unknown	No	12.6	36.4	17.2	7150	10.1	No	3
32	Poon	2007	64	F	None	Hepatobiliary	No	12.4		39.3			No	9
33	Kapoor	2007	58	M	AML	Unknown	No		25.7			8.4	No	16
34	Egyed	2008	39	F	Haemolytic anaemia	Unknown	No	3.7		10.5	1859		Yes	
35	Nadisauskiene	2008	31	F	Intermittent neutropenia	Postcaes. endometritis	No	9.3	25.5	1		19.7	No	60
36	Hess	2008	81	M	DM	Diverticulitis	No	10	19.7				No	8
37	Merino	2009	83	F	None	Liver abscess	No	12.2	36	26.5	2288	19.6	No	72
38	Boyd	2009	46	M	None	Cholecystitis	Yes	7.5	22	36			No	NR
39	Uppal	2009	61	M	Hepatitis C and cirrhosis	Unknown	No	11.7	32	38		28	No	8
40	Bunderen	2010	74	M	None	Cholangitis	Yes	9.8		29.8	2300	23.7	Yes	

Hb = haemoglobin at time of presentation; Ht = haematocrit at time of presentation; WBCs = white blood cells; LDH = lactate dehydrogenase; Bili. = total bilirubin; M = male; F = female; AML = acute myeloid leukaemia; DM = diabetes mellitus; CLL = chronic lymphoid leukaemia; NR = not reported; Postcaes. = post caesarean; Postamn.= postamniocentesis; ALL = acute lymphoid leukaemia; Postop. = postoperative. References mentioned in this table are available on request.

attempt was made to remove the focus of infection (i.e. by drainage of liver abscess, cholecystectomy, hysterectomy or ERCP), which proved to be a strong prognostic indicator of survival. Only two out of these eight cases that underwent intervention died, compared with 30 out of 32 cases in which an invasive procedure was not attempted (relative risk (RR) of mortality associated with attempted intervention: 0.27 (95% confidence interval (CI) 0.08 to 0.89)). The presence of severe anaemia at presentation (defined as Hb <8 g/dl or Ht <24%) was not significantly associated with mortality (RR 1.24 (CI 0.91 to 1.71)), nor was age >65 years (RR 1.22 (CI 0.90 to 1.66)). Obviously the decision to operate on a severely ill patient will depend on the type and extensiveness of the infection, comorbidity and clinical condition. In many of the reviewed cases the patient had already gone into shock or died before a diagnosis could be made. However, if there is an apparent focus that can be removed, our case and this review illustrate that an attempt to do so will likely improve outcome.

In summary, *C. perfringens* septicaemia is a rare but well-known cause of massive intravascular haemolysis. In severely ill patients with fever and haemolysis on the emergency department it should always be considered, since early antibiotic treatment and if possible removal of the focus of infection can rescue patients from an otherwise fatal outcome.

REFERENCES

1. Case records of the Massachusetts General Hospital. Weekly clinicopathological Exercises. Case 49-1979. N Engl J Med. 1979;301(23):1276-81.
2. Hatheway CL. Toxigenic clostridia. Clin Microbiol Rev. 1990;3(1):66-98.
3. Caya JG, Truant AL. Clostridial bacteremia in the non-infant pediatric population: a report of two cases and review of the literature. Pediatr Infect Dis J. 1999;18(3):291-8.
4. Rechner PM, Agger WA, Mruz K, Cogbill TH. Clinical features of clostridial bacteremia: a review from a rural area. Clin Infect Dis. 2001;33(3):349-53.
5. Bodey GP, Rodriguez S, Fainstein V, Elting LS. Clostridial bacteremia in cancer patients. A 12-year experience. Cancer. 1991;67(7):1928-42.
6. Anas AA, Wiersinga WJ, de Vos AF, van der Poll T. Recent insights into the pathogenesis of bacterial sepsis. Neth J Med. 2010;68(4):147-52.
7. Awad MM, Bryant AE, Stevens DL, Rood JI. Virulence studies on chromosomal alpha-toxin and theta-toxin mutants constructed by allelic exchange provide genetic evidence for the essential role of alpha-toxin in Clostridium perfringens-mediated gas gangrene. Mol Microbiol. 1995;15(2):191-202.