LETTER TO THE EDITOR

Hydatid liver cyst ruptured into vena cava inferior

Dear sir,

I have read the paper entitled 'Embolisation of hydatid cysts in the pulmonary artery presenting with haemoptysis'[1] and thank you for your study. I want to present a similar case[2] and ask some questions.

A woman (32 years) with dyspnoea, cough and haemoptysis had an abdominal mass and the diagnosis of hydatid liver cyst was made by ultrasound. Computed tomography reported that the cyst was 12 x 8 cm in diameter, multiloculated and invading segments I, IV and VIII of the liver and possibly ruptured into the vena cava. MRI, Doppler ultrasound and cavagraphy confirmed cystic lesions in the retrohepatic vena cava and also in the pulmonary artery (*figure 1*). At first, treatment of the main hydatid focus in the liver was planned. Abdominal exploration demonstrated a hydatid liver cyst and because of the diagnosis of rupture into the inferior vena cava, the cyst was opened with caution after a control puncture with an angiocath. There was no blood in the cyst cavity, the cyst was opened and the membranes were removed. The inner surface of the cyst cavity was examined gently with a probe and during that meticulous examination a communication, 3 mm in a diameter, was found posterior to the vena cava. The communication was closed with sutures. We concluded that the higher intra-cystic pressure[3] and the valvular functions of the pericystic folds prevented blood from the vena cava filling the cyst. An additional cystobiliary communication was sutured and the procedure was concluded with an omentopexy into the cyst. The postoperative course of liver surgery was uneventful and four months later she underwent surgery for pulmonary artery hydatid embolism. After pulmonary arteriotomy, a hydatid cyst, 5 x 5 cm in a diameter, was removed and there was no need for pnemonectomy. After a follow-up of 18 months, she still had symptoms of chronic pulmonary embolism.

Figure 1. *Upper abdominal CT scan revealing calcified sequel of operated hydatid cysts in the medial segment of the left hepatic lobe*

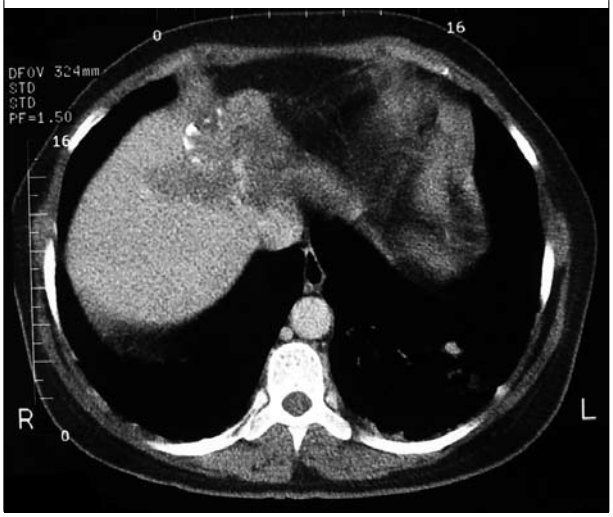

Hydatid pulmonary embolism from fistulisation or rupture of hydatid liver cysts is very rare. My questions are: What was the location, type and diameter of liver hydatid cyst? Was there any blood in the cyst cavity in the liver when it was opened. Is pneumonectomy necessary in those cases or is embolectomy alone enough. And, lastly, what was the primary focus (liver) in your patient when you operated the lung.

C. Kayaalp
Department of General Surgery, Staff Surgeon of Gastrointestinal Surgery, Turgut Ozal Medical Centre, Inonu University, Malatya, Turkey, tel.: +90 422-341 06 60/37 06, fax: +90 422-341 02 29, e-mail: cuneytkayaalp@hotmail.com, e-mail: ckayaalp@inonu.edu.tr

REFERENCES

1. Aribas OK, Kanat F, Turk-Aribas E, Erayman I, Yuksek T. Embolisation of hydatid cysts in the pulmonary artery presenting with haemoptysis. Neth J Med 2007;65:109-11.
2. Kayaalp C, Akoğlu M, Koca İ, Aydın C, Bostancı EB. Hydatid liver cyst ruptured into vena cava inferior. Turkish Surgical Congress, Poster No: P241, 2004, Antalya, Turkey.
3. Yalin R, Aktan AO, Yegen C, Dosluoglu HH. Significance of intracystic pressure in abdominal hydatid disease. Br J Surg 1992;79:1182-3.

Response from the authors

Ruptured hepatic cysts adjacent to the hepatic vein or the inferior vena cava may cause development of hydatid cysts either in pulmonary parenchyma or rarely pulmonary arteries.[1,2] Our patient had a history of surgery for a hepatic hydatid cyst five years ago. Unfortunately, we did not have an opportunity to get a preoperative abdominal CT of the patient. However, a recently taken upper abdominal CT revealed that the patient most probably had multiple giant hepatic cysts neighbouring the inferior vena cava, because the lateral segment of the left liver lobe was totally resected, there was some calcification and residual cystic spaces were seen in the medial segment of the left liver lobe. *Figure 1* demonstrates the calcified degenerative type V hydatid cyst in the primary focus. We had no information on whether there was any blood in the cyst cavity when it was opened.

Embolectomy and/or enucleation are generally accepted surgical procedures, especially for an isolated hydatid cyst, which is diagnosed early and causing proximal or distal pulmonary artery occlusion without any irreversible parenchymal or intimal arterial wall degeneration.[1] Otherwise, lobectomy or pneumonectomy may be needed.[1,3]

O.K. Aribas[1], F. Kanat[2], E. Turk-Aribas[3]
Departments of [1]Thoracic Surgery, [2]Chest Diseases and [3]Infectious Diseases, Meram Medical School of Selcuk University, Konya, Turkey, Selcuk Universitesi, Meram Tip Fakultesi, 42080, Konya, Turkey, tel.: +90 332-223 68 44, fax: +90 332-223 66 43, e-mail: olgun@selcuk.edu.tr

REFERENCES

1. Aribas OK, Kanat F, Turk-Aribas E, Erayman I, Yuksek T. Embolisation of hydatid cysts in the pulmonary artery presenting with haemoptysis. Neth J Med 2007;65:109-11.
2. Rothlin MA. Fatal intraoperative pulmonary embolism from a hepatic hydatid cyst. Am J Gastroenterol 1998;93:2606-7.
3. Koksal C, Baysungur V, Okur E, Sarikaya S, Halezaroglu S. A two-stage approach to a patient with hydatid cysts inside the right pulmonary artery and multiple right lung involvement. Ann Thorac Cardiovasc Surg 2006;12:349-51.