Netherlands
The Journal of Medicine

PHOTO QUIZ

Melaena in a liver transplant recipient

J.J. Koornstra[1*], P.M.J.G. Peeters[2], A.P. van der Berg[1] E.J. van der Jagt[3]

Departments of [1]Gastroenterology and Hepatology, [2]Hepatobiliary Surgery and [3]Radiology, University Medical Centre Groningen, PO Box 30001, 9700 RB Groningen, the Netherlands, [*]corresponding author: tel.: +31 (0)50-361 33 54, fax: +31 (0)50-361 93 06

A 25-year-old female presented with melaena. At birth, she had been diagnosed with biliary atresia, initially treated with Kasai hepatic portoenterostomy. At the age of 5, she required liver transplantation with Roux-en-Y biliary anastomosis. For 20 years following transplantation, her medical history had been uneventful. On admission, the patient was haemodynamically unstable and was admitted to the intensive care unit. The haemoglobin level was 6.2 mmol/l. Subsequent evaluation including upper and lower gastrointestinal endoscopy, angiography and bleeding scans did not reveal the source of the bleeding. An abdominal CT was performed with intravenous contrast and selected images are shown (*figures 1* and *2*).

WHAT IS YOUR DIAGNOSIS? WHAT ARE THE TREATMENT OPTIONS?

See page 30 for the answer to this photo quiz.

Figure 1.

Figure 2.

ANSWER TO PHOTO QUIZ (ON PAGE 28)

MELAENA IN A LIVER TRANSPLANT RECIPIENT

Following the CT, percutaneous transhepatic venography was performed (*figure 3*) and portal venous pressure measurements were obtained.

The CT scan in the portal venous phase showed a dilated portal vein and contrast extravasation in the Roux-Y limb (*figure 1*, arrow) and downstream in the gut lumen (*figure 2*, arrow). A bleeding focus was suspected at the Roux-en-Y site, probably associated with portal hypertension. Percutaneous transhepatic venography showed the presence of a portal vein stenosis (*figure 3*, white arrow) with portal hypertension illustrated by marked dilatation of the coronary vein (*figure 3*, black arrow). The portal venous pressure gradient across the stenosis was 10 mmHg. The stenosis was treated by transhepatic balloon venoplasty (*figure 4*), after which the coronary vein dilation disappeared (*figure 5*). The gradient completely resolved following the intervention. After the procedure, the bleeding stopped and further recovery was uneventful.

Upper gastrointestinal bleeding is a common complication following liver transplantation. In a series of 92 gastrointestinal bleeding episodes in liver transplant recipients with endoscopic diagnoses the most common causes were ulcers (n=25), enteritis (n=24), oesophageal or gastric varices (n=15) and Roux-en-Y bleeds (n=6).[1] In the patients with Roux-en-Y bleeds, endoscopic investigations were nondiagnostic and the diagnosis was established by laparotomy.[1] In the setting of gastrointestinal bleeding and portal hypertension, one should be aware of bleeding sources not only from the oesophagus or stomach, but also uncommon sites with possible varices, such as duodenum, Roux-en-Y limb, gallbladder or colorectum.[2] In liver transplant recipients with an anastomotic portal vein stenosis, treatment with percutaneous transhepatic balloon venoplasty has been shown to be effective, eliminating the need for surgical revision, portacaval shunting, or retransplantation.[3,4]

REFERENCES

1. Tabasco-Minguillan J, Jain A, Naik M, et al. Gastrointestinal bleeding after liver transplantation. Transplantation 1997;63:60-7.
2. Kotfila R, Trudeau W. Extraesophageal varices. Dig Dis 1998;16:232-41.
3. Zajko AB, Sheng R, Bron K, Reyes J, Nour B, Tzakis A. Percutaneous transluminal angioplasty of venous anastomotic stenoses complicating liver transplantation: intermediate-term results. J Vasc Interv Radiol 1994;5:121-6.
4. Funaki B, Rosenblum JD, Leef JA, et al. Percutaneous treatment of portal venous stenosis in children and adolescents with segmental hepatic transplants: long-term results. Radiology 2000;215:147-51.

Figure 3.

Figure 4.

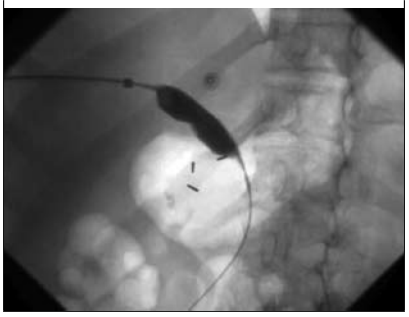

Figure 5.