

# Benign uterine uptake of FDG: a case report and review of literature

D. Vriens<sup>\*</sup>, L.F. de Geus-Oei<sup>†</sup>, U.E. Flucke<sup>‡</sup>, A.J. van der Kogel<sup>§</sup>, W.J.G. Oyen<sup>¶</sup>, M.E. Vierhout<sup>¶</sup>,  
J.W.M. van der Meer<sup>¶</sup>

<sup>\*</sup>Departments of <sup>†</sup>Nuclear Medicine, <sup>‡</sup>Pathology, <sup>§</sup>Radiation Oncology, <sup>¶</sup>Obstetrics and Gynaecology and <sup>¶</sup>General Internal Medicine, Radboud University Nijmegen Medical Centre, Nijmegen, the Netherlands, <sup>\*</sup>corresponding author: tel.: +31 (0)24-361 40 48, fax: +31 (0)24-361 89 42, e-mail: D.Vriens@nucmed.umcn.nl

Dear Editor,

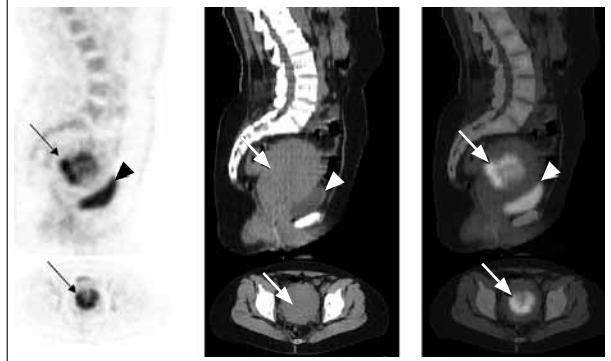
We observed very high uterine [<sup>18</sup>F]-fluorodeoxyglucose (FDG) uptake on positron emission tomography (PET) in what proved to be a benign uterine leiomyoma. Although clinically apparent in 25% of women<sup>1</sup> and prevalent in up to 77%,<sup>2</sup> this phenomenon is only incidentally described. Here we present a case of a 49-year-old woman. Our patient underwent an FDG-PET/CT for follow-up of an infectious focus on the lower back. Apart from a metabolically active lymph node and bone marrow, it revealed a ~9.6 cm large, inhomogeneous but sharply demarcated FDG-avid lesion in the posterior uterine wall (figure 1). The lesion was ultrasonographically a typical large leiomyoma.

An abdominal hysterectomy was performed for lumbago and anaemia due to menometrorrhagia. Histopathological examination revealed an enlarged uterus with an intramural leiomyoma of 7.8 cm in diameter and multiple small subserosal leiomyomas, the size below the resolution of the PET/CT scanner. Microscopy showed the typical image of a leiomyoma, without signs of necrosis, haemorrhage, atypia or inflammation. There was no cervical atypia and the endometrium was thin (<1 mm) and showed some changes corresponding to progestagen suppletion.

In search of an explanation for the high FDG uptake, sections of the anterior – on PET normal – uterine myometrium were compared with sections of the leiomyoma. Immunohistochemical staining of markers for proliferation, inflammation, hypoxia, apoptosis, vascularity, glucose metabolism and glycogen content was quantified. This quantification demonstrated a slight increase in proliferation and glycogen content.

Incidentally found leiomyomas are occasionally reported to have elevated FDG uptake (standardised uptake value (SUV)

**Figure 1.** [<sup>18</sup>F]-fluorodeoxyglucose (FDG) positron emission tomography with nondiagnostic, low-dose x-ray computed tomography performed in a 49-year-old woman with a history of soft tissue infection of the lower back. Arrow: intense FDG uptake (max SUV: 12.7, mean SUV: 8.4) in the enlarged uterus, posterior wall. Arrowhead: urinary bladder. SUV = standardised uptake value, parameter representing the relative increase of the regional uptake of the tracer above expected from homogenous distribution over the body.



6.0 to 16).<sup>3,4</sup> Retrospective analysis of screening FDG-PET in 589 healthy women found increased FDG-uptake due to leiomyomas in 22 females of which only 14% showed FDG uptake higher than the liver.<sup>5</sup> A screening FDG-PET in 1357 healthy women found an SUV larger than 3.0 in 10% of the leiomyomas in premenopausal women and in only 1.2% in postmenopausal women.<sup>6</sup> A prospective study of 61 proven leiomyomas showed that 17% have an SUVmax higher than 2.5, but only one had an SUV larger than 5.0.<sup>7</sup> The differential diagnosis of increased uterine FDG-uptake should include the menstrual and ovulation phase of the

menstrual cycle, menorrhagia, postpartum changes, atypical polypoid adenomyomas and intrauterine devices. The SUV in leiomyosarcoma is significantly higher than in leiomyomas but the overlap limits its ability to distinguish these in individual patients.<sup>8</sup> The reason for enhanced FDG uptake in leiomyomas is suggested to be related to the high levels of cervical and endometrial tissue glycogen in a myomatous uterus, the increased blood fraction and the proliferation of the smooth muscle cells due to increased metabolic need. Finally, it has been established that leiomyomas may experience severe hypoxia, even though a stress reaction with HIF-1 $\alpha$ , CAIX or GLUT1 has never been quantified.<sup>9</sup>

To clinicians and nuclear medicine specialists it is important to be aware of the fact that benign leiomyomas of the uterus may rarely show high FDG uptake. Although leiomyosarcomas show higher FDG uptake than leiomyomas, it does not distinguish benign and malignant disease.

#### ACKNOWLEDGEMENTS

Immunohistochemical staining was performed by W.J.M. Peeters (hexokinase isoenzymes), C. Frielink (HIF-1 $\alpha$ , CAIX and GLUT1) and C.N. Maass (CD3, CD31 and caspase-3). This study was funded by internal resources only. All authors declare not to have any conflicts of interest.

#### REFERENCES

1. Buttram VC, Jr, Reiter RC. Uterine leiomyomata: etiology, symptomatology, and management. *Fertil Steril.* 1981;36(4):433-45.
2. Cramer SF, Patel A. The frequency of uterine leiomyomas. *Am J Clinical Pathol.* 1990;94(4):435-8.
3. Ak I, Ozalp S, Yalcin OT, Zor E, Vardareli E. Uptake of 2-[18F]fluoro-2-deoxy-D-glucose in uterine leiomyoma: imaging of four patients by coincidence positron emission tomography. *Nuclear Med Comm.* 2004;25(9):941-5.
4. Chura JC, Truskinovsky AM, Judson PL, Johnson L, Geller MA, Downs LS, Jr. Positron emission tomography and leiomyomas: clinicopathologic analysis of 3 cases of PET scan-positive leiomyomas and literature review. *Gynecol Oncol.* 2007;104(1):247-52.
5. Lin CY, Ding HJ, Chen YK, Liu CS, Lin CC, Kao CH. F-18 FDG PET in detecting uterine leiomyoma. *Clin Imaging.* 2008;32(1):38-41.
6. Nishizawa S, Inubushi M, Kido A, Miyagawa M, Inoue T, Shinohara K, et al. Incidence and characteristics of uterine leiomyomas with FDG uptake. *Ann Nuclear Med.* 2008;22(9):803-10.
7. Kitajima K, Murakami K, Yamasaki E, Kaji Y, Sugimura K. Standardized uptake values of uterine leiomyoma with 18F-FDG PET/CT: variation with age, size, degeneration, and contrast enhancement on MRI. *Ann Nuclear Med.* 2008;22(6):505-12.
8. Tsujikawa T, Yoshida Y, Mori T, Kurokawa T, Fujibayashi Y, Kotsuji F, et al. Uterine tumors: pathophysiologic imaging with 16alpha-[18F] fluoro-17beta-estradiol and 18F fluorodeoxyglucose PET--initial experience. *Radiology.* 2008;248(2):599-605.
9. Shida M, Murakami M, Tsukada H, Ishiguro Y, Kikuchi K, Yamashita E, et al. F-18 fluorodeoxyglucose uptake in leiomyomatous uterus. *Int J Gynecol Cancer.* 2007;17(1):285-90.