

Recurrent pericardial effusion with a common clinical disorder

A.W.F.T. Toorians^{1*}, W.A.A.J. van Ekelen²

Departments of ¹Internal Medicine and ²Cardiology, Sint Anna Hospital, Geldrop, the Netherlands, *corresponding author: tel.: +31 (0)40-286 48 30, fax: +31 (0)40-286 43 30, e-mail: a.toorians@st-anna.nl

ABSTRACT

We present a case of recurrent pericardial effusion in a patient with Down's syndrome in whom the underlying cause was not considered because of unfamiliarity with the care of people with Down's syndrome. The diagnosis hypothyroidism only became apparent by means of a routine panel of biochemical tests.

KEYWORDS

Down's syndrome, hypothyroidism, pericardial effusion

CASE REPORT

A 34-year-old man with Down's syndrome was referred by his general practitioner to a cardiologist because of cardiomegaly on an X-ray of the chest (*figure 1*). After having had a cold, he complained of fatigue and shortness of breath present for several months. On physical examination the patient had

a normal body temperature, his resting heart rate was 60 beats/min. There were no murmurs, no signs of heart failure, blood pressure was 110/80 mmHg and no pulsus paradoxus. Electrocardiography showed low QRS voltages compatible with pericardial effusion (*figure 2A*). Echocardiography revealed a large amount of pericardial fluid, with normal function of the left ventricle and valves. The right atrium was not collapsed (*figure 3*). He was then treated with acetylsalicylic acid 1200 mg three times a day, without

Figure 1. Anteroposterior view of the chest showing cardiomegaly

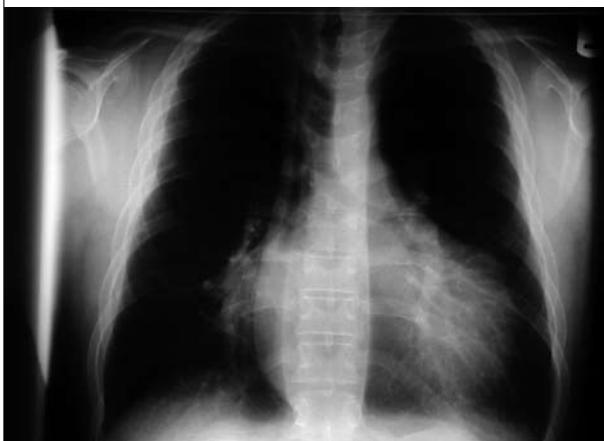

Figure 2A. ECG on presentation with low QRS voltages compatible with pericardial effusion

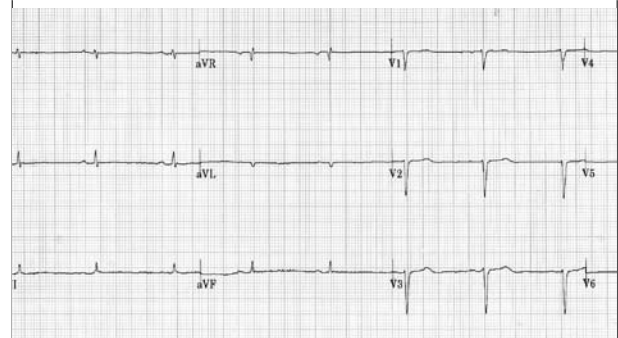
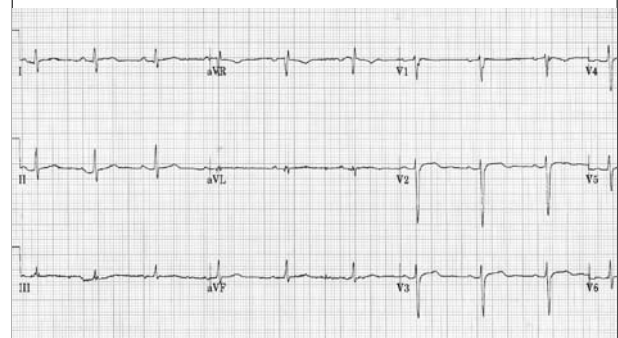


Figure 2B. After two months of treatment with levothyroxin, disappearance of pericardial effusion and normalisation of ECG



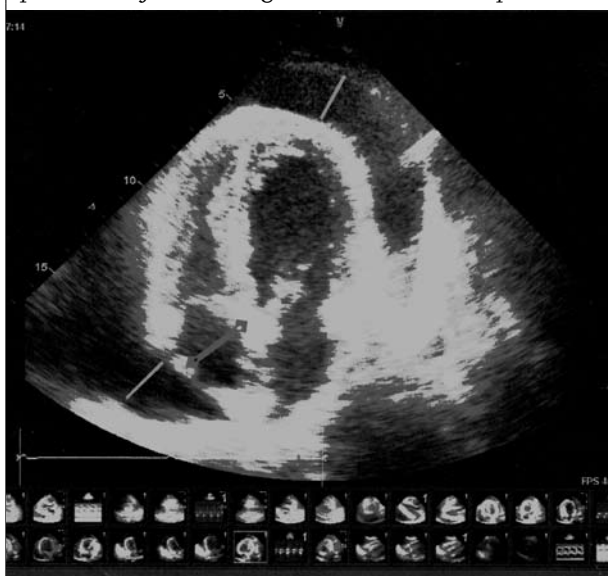response. The next step was pericardial drainage; 1000 ml transsudate was obtained. Cytological and microbiological examination showed no malignant cells, neither bacterial growth, nor information supporting possible tuberculosis. Autoimmune markers were examined. Data of routine blood and biochemical examination are summarised in *table 1*. Within two weeks the pericardial effusion reoccurred and the patient started prednisolone, 60 mg/day.

This strategy did not improve the course since the patient developed progressive pericardial effusion for which a new drainage procedure was performed, seven weeks after the first procedure. Four weeks hereafter pericardial

effusion recurred for which pericardial fenestration was considered. For this procedure the patient was referred to a thorax centre. Surprisingly, on admission the diagnosis of a pronounced primary hypothyroidism (TSH > 150mU/l, FT4 <1.3 pmol/l) was made by means of routine standardised biochemical tests. This routine screening included metabolic causes of pericardial diseases such as uraemia and hypothyroidism.¹ This latter differential diagnostic possibility had not been considered previously.

The patient was then treated by levothyroxine with a starting dose of 50 µg/day. An improvement in symptoms, normalisation of the ECG (*figure 2B*), as well as the cardiac silhouette on chest X-ray developed after two months and the pericardial fluid disappeared.

Figure 3. Echocardiograph showing large amount of pericardial fluid; the right atrium is not collapsed



DISCUSSION

This patient with Down's syndrome had an unusual presentation of hypothyroidism: an impressive amount of pericardial effusion. Other signs such as myxoedema, mild macrocytic anaemia, elevated creatine kinase² and symptoms of hypothyroidism such as fatigue may have been overlooked in this situation. Other clinical findings, which previously did not draw much attention, can in retrospect be judged in favour of a metabolic cause, in particular hypothyroidism. The first working diagnosis was postviral pericardial effusion because the history started with a cold, two months before admission. During his stay in the department of cardiology the patient had normal body temperature. CRP was only marginally elevated and there was a normal leucocyte count, making an infectious cause of pericardial effusion unlikely. In our

Table 1. Results of blood and biochemical examination

	Normal values	On admission to hospital	In thorax centre 16 weeks after initial presentation	Ten weeks after start of levothyroxine treatment
TSH	0.3-5.2 mU/l	-	>150	1.2
FT4	12.0-28.0 pmol/l	-	<1.3	17
CRP		16		
Haemoglobin	8.8-11.2 mmol/l	7.3		7.5
MCV	82-92 fl	99		99
Leucocytes	4-11 /nl	7.3		5.9
CRP	0-5 mg/l	16		13
Sodium	135-145 mmol/l	128		143
Potassium	3.5-5.0 mmol/l	4.4		3.6
Creatinine	70-115 µmol/l	114		89
ASAT	0-40 U/l	86		17
ALAT	0-45 U/l	35		20
CK	0-200 U/l	1003		22
Troponin	0-0.1 µg/l	0.08		
A-TPO	0-35 kU/l			50
RF	0-20 U/ml	6		
ANA	Negative	Negative		

patient pericardial fluid was accompanied with bradycardia, an odd combination of signs since one would expect tachycardia instead. The combination of pericardial effusion and bradycardia might suggest hypothyroidism. The low voltage in the ECG (*figure 2A*) was interpreted as a sign of pericardial effusion. However, it can also be seen in hypothyroidism. It remains speculative if the low-voltage ECG in hypothyroidism is caused by hypothyroidism per se or by its very frequently accompanying, but undetected, pericardial effusion.^{3,4} Unfortunately, we have no ECG shortly after pericardial drainage in order to disentangle these two possibilities. Low QRS voltage is a common finding in patients with severe pericardial effusion. Mechanisms to explain the origin of this low voltage are mechano-electrical alteration of the myocardium, distance of the heart to the body surface electrodes, reduction of cardiac size and volume. Other investigators have found arguments in favour of inflammation and electrical alterations of the myocardium but not pericardial effusion per se. Their arguments are supported by the findings that QRS voltage does not increase one day after pericardiocentesis.⁵ When our patient became euthyroid and when the pericardial effusion had resolved, the ECG voltages normalised (*figure 2B*) and his resting heart rhythm became 68 beats/min.

Although there were no significant signs of inflammation and while results of autoimmune markers were examined, it was decided to start prednisolone therapy because of the recurrence of pericardial fluid. In retrospect, this decision can be deemed as an aggressive one since we had no clear working hypothesis in which a systemic autoimmune process was likely. The relapsing character of large amounts of pericardial effusion, although without signs indicating development of cardiac tamponade, in a young man with Down's syndrome made us decide that an immune suppressive therapy by means of corticosteroids was justifiable. In retrospect, the decision to start with high-dose prednisone may be seen as a relatively aggressive therapy.

Patients with trisomy of chromosome 21 have a prevalence of 15 to 20% of autoimmune hypothyroidism.^{6,7} Although it is recommended to screen patients with Down's syndrome on an annual basis for thyroid function, this patient had never been screened.

Pericardial effusions occur in a variable frequency in patients with hypothyroidism.^{8,9} The effusions are usually small and escape detection, but occasionally patients with severe long-standing hypothyroidism have large effusions.³ Myxoedema may be accompanied with pericardial effusion. Occasionally, the pericardial effusions are quite large, causing the appearance of cardiomegaly on routine chest radiographs. Echocardiography demonstrates small to moderate effusions in as many as 30% of overtly

hypothyroid patients. The presence of pericardial fluid in hypothyroid patients does not compromise cardiac output, cardiac tamponade is exceedingly rare, and the effusion resolves over a period of weeks to months after initiation of thyroid hormone replacement.^{1,4}

That the common clinical disorder of hypothyroidism was not considered in this 'unexplained' pericardial effusion may be influenced by the uncommon magnitude of it and by the fact that the patient has Down's syndrome, which made the estimation of his clinical condition difficult.

In this case hypothyroidism became apparent by means of a routine panel of examinations when pericardiocentesis was scheduled. Furthermore, blood and biochemical tests also showed less common signs of hypothyroidism: a mild macrocytic anaemia, elevated levels of CK.² These markers normalised with supplementation with levothyroxine.

In conclusion, patients with trisomy of chromosome 21 should be regularly monitored for hypothyroidism and thyroid function should be tested in patients with unexplained pericardial effusions. In the Netherlands guidelines for medical follow-up of children with Down's syndrome are available for paediatricians. Internists have to be familiar with these guidelines because we can expect an increasing number of patients with Down's syndrome who will be transferred from their paediatrician to an internist.^{10,11}

REFERENCES

1. Soler-Soler J, Corey GC, Shabetai R. Diagnosis and treatment of pericardial effusion. 2006 UpToDate version 14.3.
2. Klein I, Levey GS. Unusual Manifestations of Hypothyroidism. *Arch Intern Med* 1984;144:123-8.
3. Levy PY, Corey R, Berger P, et al. Etiologic diagnosis of 204 pericardial effusions. *Medicine (Baltimore)* 2003;82:385-91.
4. Klein I. Endocrine Disorders and Cardiovascular Disease. In: Zipes: Braunwald's Heart Disease: A Textbook of Cardiovascular Medicine. 7th edition. Philadelphia: Saunders 2005; p. 2051-66.
5. Bruch C, Schmermund A, Dages N, et al. Changes in QRS voltage in cardiac tamponade and pericardial effusion: reversibility after pericardiocentesis and after anti-inflammatory drug treatment. *J Am Coll Cardiol* 2001;38:219-26.
6. Friedman DL, Kastner T, Pond WS, O'Brien DR. Thyroid dysfunction in individuals with Down syndrome. *Arch Intern Med* 1989;149:1990-3.
7. Murdoch JC, Ratcliffe WA, McLarty DG, Rodger JC, Ratcliffe JG. Thyroid function in adults with Down's syndrome. *J Clin Endocrinol Metab* 1977;44:453-8.
8. Kabadi UM, Kumar SP. Pericardial Effusion in primary hypothyroidism. *Am Heart J* 1990;120:1393-5.
9. Zimmerman J, Yahalom J, Bar-On H. Clinical Spectrum of pericardial effusion as the presenting feature of hypothyroidism. *Am Heart J* 1983;106:770-1.
10. Smith DS. Health care management of adults with Down syndrome. *Am Fam Physician* 2001;64:1031-8.
11. Borstlap R (ed). Leidraad voor de medische begeleiding van kinderen met het Down syndroom. April 1998.