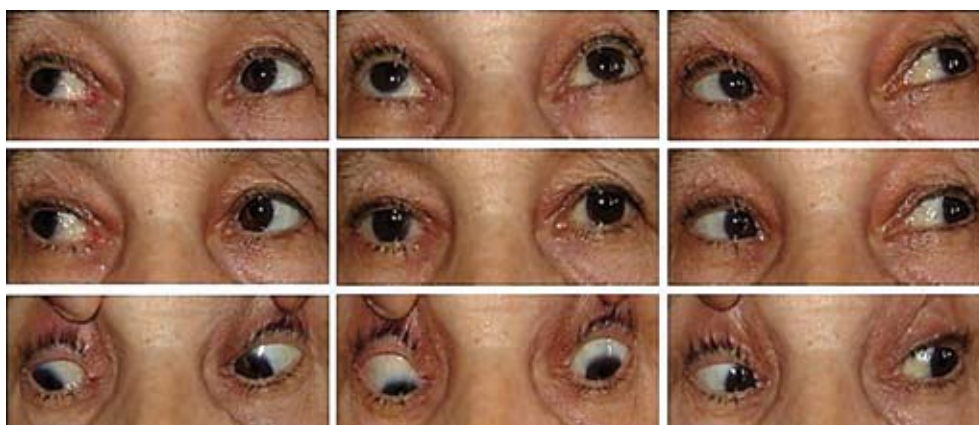

Netherlands
The Journal of Medicine

PUBLISHED IN COLLABORATION WITH THE NETHERLANDS ASSOCIATION OF INTERNAL MEDICINE



*PHOTO QUIZ: Binocular vertical double vision in a diabetic patient,
see page 309*

GUIDELINES FOR CHRONIC HEPATITIS B- AND C-VIRUS INFECTION

DOUBLE BALLOON SCOPE FOR ERCP

ENCAPSULATING PERITONEAL SCLEROSIS

50 YEARS *Netherlands Journal of Medicine*

JULY-AUGUST 2008, VOL. 66, No. 7, ISSN 0300-2977

VAN ZUIDEN COMMUNICATIONS

IF 1.548

Netherlands The Journal of Medicine

PUBLISHED IN COLLABORATION WITH THE NETHERLANDS ASSOCIATION OF INTERNAL MEDICINE

MISSION STATEMENT

The mission of the journal is to serve the need of the internist to practise up-to-date medicine and to keep track with important issues in health care. With this purpose we publish editorials, original articles, reviews, controversies, consensus reports, papers on speciality training and medical education, book reviews and correspondence.

EDITORIAL INFORMATION

Editor in chief

Anton F.H. Stalenhoef, Radboud University Nijmegen
Medical Centre, Department of General Internal
Medicine, Nijmegen, the Netherlands

Associate editors

Joost P.H. Drenth, Nijmegen, the Netherlands
Jack F.M. Wetzels, Nijmegen, the Netherlands
Theo Thien, Nijmegen, the Netherlands

Editorial board

J.V. Bonventre, Massachusetts, USA
H. Brunner, Nijmegen, the Netherlands
S.A. Danner, Amsterdam, the Netherlands
J.T. van Dissel, Leiden, the Netherlands
J.P. Droz, Lyon, France
R.O.B. Gans, Groningen, the Netherlands
A.R.J. Girbes, Amsterdam, the Netherlands
D.E. Grobbee, Utrecht, the Netherlands
D.L. Kastner, Bethesda, USA
R.B.M. Landewé, Maastricht, the Netherlands
M.M. Levi, Amsterdam, the Netherlands
B. Lipsky, Seattle, USA
R.L.J.F. Loffeld, Zaandam, the Netherlands

Ph. Mackowiak, Baltimore, USA

J.W.M. van der Meer, Nijmegen, the Netherlands

G. Parati, Milan, Italy

A.J. Rabelink, Leiden, the Netherlands

D.J. Rader, Philadelphia, USA

J.A. Romijn, Leiden, the Netherlands

J.L.C.M. van Saase, Rotterdam, the Netherlands

P. Speelman, Amsterdam, the Netherlands

C.D.A. Stehouwer, Maastricht, the Netherlands

E. van der Wall, Utrecht, the Netherlands

R.G.J. Westendorp, Leiden, the Netherlands

Editorial office 'The Netherlands Journal of Medicine'

Geeralien Derksen-Willemsen

Radboud University Nijmegen Medical Centre

Department of General Internal Medicine 463

PO Box 9101

6500 HB Nijmegen

The Netherlands

Tel.: +31 (0)24-361 04 59

Fax: +31 (0)24-354 17 34

E-mail: g.derksen@aig.umcn.nl

<http://mc.manuscriptcentral.com/nethjmed>

CITED IN

Biosis database; embase/excerpta medica; index medicus (medline) science citation index, science citation index expanded, isi alerting services, medical documentation services, current contents/clinical medicine, PubMed.



Contents

Copyright

© 2008 Van Zuiden Communications B.V. All rights reserved. Except as outlined below, no part of this publication may be reproduced, stored in a retrieval system or transmitted in any form or by any means, electronic, mechanical, photocopying, recording or otherwise, without prior written permission of the publisher. Permission may be sought directly from Van Zuiden Communications B.V.

Photocopying

Single photocopies of single articles may be made for personal use as allowed by national copyright laws. Permission of the publisher and payment of a fee is required for all other photocopying, including multiple or systematic copying, copying for advertising or promotional purposes, resale, and all forms of document delivery. Special rates are available for educational institutions that wish to make photocopies for non-profit educational classroom use.

Derivative works

Subscribers may reproduce tables of contents or prepare lists of articles including abstracts for internal circulation within their institutions. Permission of the publisher is required for resale or distribution outside the institution. Permission of the publisher is also required for all other derivative works, including compilations and translations.

Electronic storage

Permission of the publisher is required to store or use electronically any material contained in this journal, including any article or part of an article.

Responsibility

No responsibility is assumed by the publisher for any injury and/or damage to persons or property as a matter of product liability, negligence or otherwise, or from any use or operation of any methods, products, instructions or ideas contained in the material herein. Because of the rapid advances in the medical sciences, independent verification of diagnoses and drug dosages is advised.

Although all advertising material is expected to conform to ethical (medical) standards, inclusion in this publication does not constitute a guarantee or endorsement of the quality or value of such product or of the claims made of it by its manufacturer.

Subscriptions

General information

An annual subscription to The Netherlands Journal of Medicine (ISSN 0300-2977) consists of 11 issues. Issues within Europe are sent by standard mail and outside Europe by air delivery. Cancellations should be made, in writing, at least two months before the end of the year.

Subscription fee

The annual subscription fee within Europe is € 670, for the USA € 698 and for the rest of the world € 803. Subscriptions are accepted on a prepaid basis only and are entered on a calendar year basis.

Payment method

Please make your cheque payable to Van Zuiden Communications B.V., PO Box 2122, 2400 CC Alphen aan den Rijn, the Netherlands or you can transfer the fee to ING Bank, account number 67.89.1 0.872, Castellumstraat 1, Alphen aan den Rijn, the Netherlands, swift-code: ING BNL 2A. Do not forget to mention the complete address for delivery of the journal.

Claims

Claims for missing issues should be made within two months of the date of dispatch. Missing issues will be mailed without charge. Issues claimed beyond the two-month limit must be prepaid at back copy rates.

Orders, preprints, advertising, changes in address, author or general enquiries

Please contact the publisher.

Van Zuiden Communications B.V.

PO Box 2122
2400 CC Alphen aan den Rijn
The Netherlands
Tel.: +31 (0)172-47 61 91
Fax: +31 (0)172-47 18 82
E-mail: njm@zuidencom.nl
Internet: www.njm-online.nl

EDITORIAL

- Double balloon scope for endoscopic retrograde cholangio-pancreatography 267

M. Bruno

REVIEW

- Encapsulating peritoneal sclerosis in patients on peritoneal dialysis 269

M.P. Hendriks, R.G.L. de Sévaux, L.B. Hilbrands

ORIGINAL ARTICLE

- Double balloon enteroscopy for endoscopic retrograde cholangio-pancreaticography after Roux-en-Y reconstruction: case series and review of the literature 275

J.J. Koornstra

CASE REPORTS

- Liver transplantation in a patient with encapsulating peritoneal sclerosis 280

W.H. de Vos tot Nederveen Cappel, J. Dubbeld, S.M. Willems, J. Ringers, B. van Hoek

- Myomatous erythrocytosis syndrome: further proof for the pathogenic role of erythropoietin 283

L.T. Vlasveld, C.W.M. de Wit, R.A. Verweij, A. Castel, P.M. Jansen, A.A.W. Peters

- Two rare complications of glioblastoma multiforme: persistent hiccup and acquired haemophilia A 286

C.M.P.G. van Durme, R.N. Idema, C. van Guldener

SPECIAL REPORTS

- Case reports: added value counts 289

J.P.H. Drenth

- The *Netherlands Journal of Medicine*: 1998-2002, what came out of it? 291

A.I.M. Hoepelman

- Treatment of chronic hepatitis B virus infection – Dutch national guidelines 292

E.H.C.J. Buster, K.J. van Erpecum, S.W. Schalm, H.L. Zaaijer, J.T. Brouwer, H.C. Gelderblom, R.J. de Knecht, C. Minke Bakker, H.W. Reesink, H.L.A. Janssen, for the Netherlands Association of Gastroenterologists and Hepatologists

- Treatment of chronic hepatitis C virus infection – Dutch national guidelines 311

J. de Bruijne, E.H.C.J. Buster, H.C. Gelderblom, J.T. Brouwer, R.J. de Knecht, K.J. van Erpecum, S.W. Schalm, C.M. Bakker, H.L. Zaaijer, H.L.A. Janssen, H.W. Reesink, for the Netherlands Association of Gastroenterologists and Hepatologists

PHOTO QUIZZES

- Sudden onset of dorsal swelling of hands and feet 307

Y-C. Chao, C-Y. Ma, L-H. Lin

- Binocular vertical double vision in a diabetic patient 309

D. Ilhan, S.Aydin, E. Gulcan

MONTHLY NJM ONLINE HITLIST

- For all articles published in April 2008 324

Double balloon scope for endoscopic retrograde cholangiopancreatography

M. Bruno

Department of Gastroenterology and Hepatology, Erasmus Medical Centre, Rotterdam, the Netherlands

In this issue of the *Netherlands Journal of Medicine*, Koornstra reports on the experience with a rather unconventional use of the double balloon enteroscope.¹ Instead of using it for what it was originally designed, i.e. luminal inspection of the small intestine in search of mucosal abnormalities such as angiodysplasia, Crohns' ulcers or polyps, they looked beyond this. Koornstra et al. utilised the double balloon enteroscope, with a diagnostic and therapeutic intent, solely as a vehicle to reach a distant target beyond the small intestine, namely the papilla of Vater and the biliary tract, in patients with surgically altered anatomy, in whom a regular side-viewing endoscopic retrograde cholangiopancreatography (ERCP) scope was impossible to use or failed.

In the normal anatomical situation, that is when no surgical diversion of the upper gastrointestinal tract is present, the distance from the incisors to the papilla of Vater in humans is approximately 55 to 60 cm (so-called short scope position). After Billroth II (BII) gastrectomy, even after surgical resection of the distal stomach and diversion of the small intestine with the creation of an afferent and efferent loop, the distance is still such that, at least in theory, the papilla can be reached by a conventional scope (either forward or side viewing) in the majority of patients. In practice, there are patients in whom the surgeon created an afferent loop that is too long for a conventional scope to reach the papilla. Moreover, in some cases there is a sharp angulation between the stomach remnant and the entry to the afferent loop, preventing safe cannulation of the afferent loop with a side-viewing scope. Importantly, some series of ERCP in patients with a BII gastrectomy report over 10% of perforations, a percentage which is exceedingly high compared with ERCP in patients with a normal anatomy.^{2,3} All this can be attributed to the use of a side-viewing endoscope in an anatomically unfavourable situation and to a relative lack of experience of the majority of endoscopists in this particular situation. Indeed, patients after BII gastrectomy are becoming a rarity in this day and age of medical treatment of ulcer disease and the discovery of *Helicobacter pylori*. Instead, a

new category of patients are emerging who have undergone complicated and extensive upper abdominal surgery. Importantly, after these complex procedures such as hepaticojejunostomy, Whipple's or pylorus-preserving pancreaticoduodenectomy, reaching the papilla of Vater by peroral endoscopy with conventional endoscopes is virtually impossible. In these patients ERCP by means of double balloon enteroscopy is a valuable option, as is elegantly demonstrated in this issue of the *Netherlands Journal of Medicine* by Koornstra.¹

Once the ampulla is reached with the double balloon enteroscope, the 'ERCPist' has to deal with some factors that are significantly different from the situation when performing a 'standard' ERCP. For one, instead of a side view, the double balloon enteroscope provides a forward endoscopic view. More importantly, the lack of an elevator may seriously hamper the therapeutic capabilities one has. Nevertheless, several series have now shown that papillotomy, stone extraction and stent placement can all be performed safely and effectively through a double balloon enteroscope in a substantial number of patients without the use of an elevator.⁴⁻⁷ Undoubtedly, as is the case in all complex therapeutic interventions, operator experience will contribute to a higher success rate of double balloon ERCP. At present, an important drawback is the lack of accessories that have been specifically designed for use through a double balloon forward-viewing scope. It would do the endoscopic instrument and devices companies credit if, despite the fact that these are not mainstream indications and represent a niche market, they were to offer continued support in designing and manufacturing such dedicated instruments and accessories to improve the efficacy and safety of these 'orphan' ERCP procedures for the benefit of our patients.

REFERENCES

1. Koornstra JJ. Double balloon enteroscopy for endoscopic retrograde cholangiopancreatography after Roux-en Y construction: case series and review of the literature. *Neth J Med* 2008;66:275-9.

2. Faylona JM, Quadir A, Chan AC, et al. Small-bowel perforations related to endoscopic retrograde cholangiopancreatography (ERCP) in patients with Billroth II gastrectomy. *Endoscopy* 2000;32:589-90.
3. Çiçek B, Parlak E, Dişibeyaz S, et al. Endoscopic retrograde cholangiopancreatography in patients with Billroth II gastroenterostomy. *J Gastroenterol Hepatol* 2007;22:1210-3.
4. Moreels TG, Roth B, van der Vliet EJ, et al. The use of the double-balloon enteroscope for endoscopic retrograde cholangiopancreatography and biliary stent placement after Roux-en-Y hepaticojejunostomy. *Endoscopy* 2007;39:196-7.
5. Chu YC, Su SJ, Yang CC, et al. ERCP plus papillotomy by use of double-balloon enteroscopy after Billroth II gastrectomy. *Gastrointest Endosc* 2007;66:1234-6.
6. Aabakken L, Bretthauer M, Line PD. Double balloon enteroscopy for endoscopic retrograde cholangiography in patients with a Roux-en Y anastomosis. *Endoscopy* 2007;39:1068-71.
7. Maaser C, Lenze F, Bokemeyer M, et al. Double balloon enteroscopy; a useful tool for diagnostic and therapeutic procedures in the pancreaticobiliary system. *Am J Gastroenterol* 2008;103:894-900.

Encapsulating peritoneal sclerosis in patients on peritoneal dialysis

M.P. Hendriks^{1*}, R.G.L. de Sévaux², L.B. Hilbrands²

Departments of ¹Internal Medicine and ²Nephrology, Radboud University Nijmegen Medical Centre, Nijmegen, the Netherlands, *corresponding author: tel.: +31 (0)24-361 88 19, fax: +31 (0)24-354 17 34, e-mail: m.hendriks@aig.umcn.nl

ABSTRACT

Encapsulating peritoneal sclerosis (EPS) is an uncommon but one of the most serious complications in patients on long-term peritoneal dialysis. EPS is characterised by a diffuse thickening and/or sclerosis of the peritoneal membrane which leads to a decreased ultrafiltration and ultimately to bowel obstruction. We present four cases of EPS and discuss the clinical manifestations, multifactorial aetiology, diagnosis, treatment, prognosis, and prevention. We end with a proposal for the development of an EPS prevention guideline.

KEYWORDS

Encapsulating peritoneal sclerosis, peritoneal dialysis, peritonitis, renal failure

INTRODUCTION

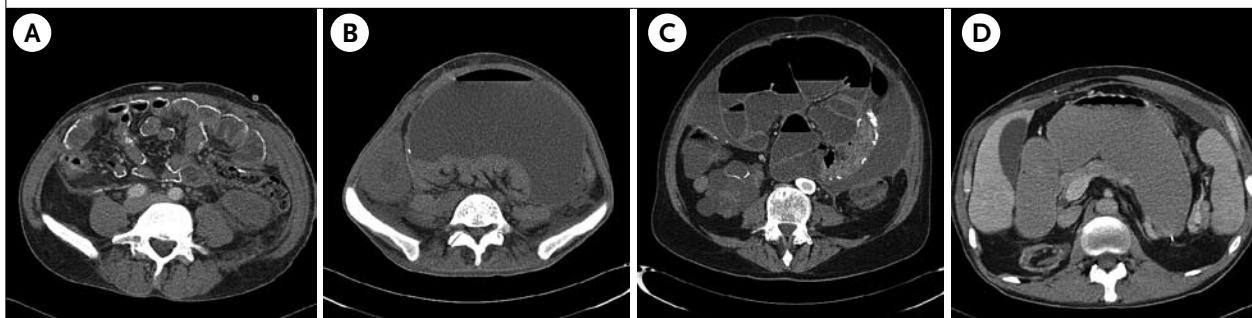
Encapsulating peritoneal sclerosis (EPS, or abdominal cocooning) is a serious, life-threatening complication in patients on long-term peritoneal dialysis (PD).^{1,2} This clinical syndrome was first described by Ghandi *et al.* in 1980.³ EPS involves thickening and sclerosis of the peritoneal membrane with extensive adhesion of the intraperitoneal organs, which results in decreased ultrafiltration and eventually in bowel obstruction with ileus symptoms. Possible causes of EPS in PD patients are recurrent episodes of peritonitis and exposure of the peritoneum to hypertonic, bioincompatible PD solutions.

CASE REPORTS

Patient A, a 53-year-old man with end-stage renal disease due to Henoch-Schönlein nephritis, underwent a second renal transplantation after a first graft had failed 17 years before. He had been treated with PD for the last 13 years with only three episodes of bacterial peritonitis. For many years he refused a second transplant because he had experienced major problems after the first transplantation. During the second transplantation procedure the surgeon noted a greenish, thickened peritoneum. A biopsy showed extensive fibrosis. From the third day after transplantation, the patient had severe nausea and vomiting. A nasogastric tube produced more than two litres of bilious fluid per day. Computed tomography (CT) of the abdomen showed extensive linear calcification of the thickened visceral peritoneum (*figure 1A*), fitting with the presence of peritoneal sclerosis. Treatment with tamoxifen was added to the immunosuppressive regimen consisting of tacrolimus, mycophenolate mofetil, and corticosteroids. His abdominal symptoms disappeared, but a severe acute rejection developed, which was unresponsive to treatment with high-dose corticosteroids. Since he refused anti-T cell therapy, the graft was removed and he started haemodialysis. One year later he died after he had decided to stop any further treatment.

Patient B, a 28-year-old man with end-stage renal failure from medullary cystic kidney disease, underwent renal transplantation. During the preceding six years he had been treated with PD, with only two episodes of bacterial peritonitis. Shortly after removal of the PD catheter six months after transplantation, the patient complained of nausea, vomiting, and an increase in abdominal circumference. Physical examination indicated the presence of ascites. Biochemically, this ascites was an exsudate, and cultures remained negative. CT showed a

Figure 1. Computed tomography of the abdomen shows (A) extensive linear calcification of the visceral peritoneum in patient A, (B) a large amount of ascites with dorsal fixation of the bowel mass in patient B, (C) a large intraperitoneal fluid collection, strongly dilated bowel loops, and multiple calcifications of the peritoneum in patient C, and (D) a large collection of free fluid in patient D



large amount of ascites with dorsal fixation of the bowel mass, suggestive of EPS (*figure 1B*). Laparoscopy showed a thick fibrous mass that completely covered the bowel walls. A peritoneal biopsy confirmed the diagnosis of peritoneal sclerosis. Treatment with tamoxifen was started, but eventually complete bowel obstruction necessitated the intravenous administration of fluids, medication, and nutrition. Because of ongoing ascites production a drain was inserted into the abdominal cavity. The ascitic fluid proved to be contaminated with faecal material, which was caused by a perforation of the small bowel wall. Surgical treatment of this perforation was judged impossible. Secondary to the bowel perforation, several episodes of peritonitis occurred. Almost three years after transplantation this patient is alive with a functioning renal graft and in relatively good condition, albeit dependent on total parenteral nutrition and continuous abdominal drainage.

Patient C, a 47-year-old male, received a kidney transplant because of end-stage renal failure due to polycystic kidney disease. Previously, he had been treated with PD for six years with only one episode of bacterial peritonitis. Shortly after transplantation, he developed abdominal discomfort. Initially, this was explained by the use of mycophenolate mofetil, but after discontinuation of this drug, he increasingly complained about a loss of appetite, nausea, vomiting, and swelling of the abdomen with discomfort. He noticed high-pitched bowel sounds and had frequent, watery stools. At six months after transplantation the abdominal discomfort worsened and the patient had lost 17 kg of body weight since transplantation. CT showed a large collection of intraperitoneal fluid, strongly dilated bowel loops, and multiple calcifications of the peritoneum (*figure 1C*). These findings were compatible with an ileus due to EPS. Cultures of ascites remained negative. Treatment consisted of replacing tacrolimus by azathioprine with

continuation of the corticosteroids, addition of tamoxifen, and total parenteral nutrition. He did well until one year after transplantation, when he was admitted because of nausea and vomiting, possibly due to progression of the peritoneal sclerosis. Cultures of the ascitic fluid now grew *E. coli* and *Pseudomonas peruginosa*, for which he was treated with intravenous meropenem. After an initial good response to treatment, the patient developed recurrent infectious episodes, complicated by acute renal failure. At a visit to the clinic he declared that no further treatment should be instituted. Eventually, he died from additional infectious complications.

Patient D, a 41-year-old man with end-stage renal disease due to IgA nephropathy, underwent two renal transplantations. At the age of 34 years, PD was restarted and in the following five years, four episodes of PD peritonitis occurred. Therefore, PD was discontinued and chronic intermittent haemodialysis was started. Six months later, he complained of vomiting without abdominal pain, and loose stools. CT of the abdomen showed a large collection of free fluid (*figure 1D*). Because EPS was suspected, a laparoscopy was performed. The surgeon noticed a clearly thickened peritoneum as well as a thick fibrinoid layer covering the bowel mass. Peritoneal biopsy showed a thickened connective tissue layer without any signs of acute inflammation, fitting with EPS. Treatment with tamoxifen, prednisone, and total parenteral nutrition was started. The latter could be stopped within a few weeks due to recovery of bowel passage. In the subsequent years he was admitted twice with a mechanical ileus and once with a peritonitis and abscess formation between the bowel loops, for which he was treated with colistin intravenously for several months. Almost three years after the diagnosis of EPS the patient is in a good clinical condition, being treated with haemodialysis and prednisolone, and working several days a week.

DISCUSSION

EPS is a rare but serious, life-threatening complication in patients undergoing long-term PD. Estimates of prevalence range from 0.54 to 7.3%.⁴ Japanese experience suggests that the overall incidence of EPS is 2.5% and a large British single-centre study reported an incidence of 3.3%.¹⁵ It appears that the incidence of EPS in patients on PD has been rising in the last few years.^{6,7} As demonstrated by three of the cases described above, EPS can also become manifest after kidney transplantation and discontinuation of PD.⁷ In addition, EPS is not exclusively a complication of PD, but is also associated with various diseases of the abdominal organs, abdominal surgery, and the use of some drugs (particularly β -blockers).⁸

Aetiology

The aetiology of EPS is poorly understood but is believed to be multifactorial (table 1).⁹ There is a correlation between the duration of PD and the likelihood of manifesting EPS. Rigby *et al.* showed an incidence of 1.9, 6.4, 10.8 and 19.4% after 2, 5, 6, and 8 years of PD, respectively.² Long-term PD may lead to peritoneal membrane failure resulting in loss of ultrafiltration. The latter is associated with an increased number of peritoneal blood vessels, fibrotic alterations, and loss of mesothelium. Continuous exposure of the peritoneum to a fluid with a nonphysiological composition is likely involved in the pathogenesis of these alterations. Glucose and glucose degradation products (GDPs) are toxic to peritoneal cells and induce the formation of advanced glycosylation end-products (AGEs) which are deposited in peritoneal tissue.¹⁰ It has been shown that the use of hypertonic glucose solutions precedes increases in solute transport over the peritoneal membrane, which is associated with ultrafiltration failure.¹¹ As a consequence, a further increase in glucose exposure is needed to achieve sufficient fluid removal. This leads to a vicious circle with the risk of progressive peritoneal sclerosis. Other important factors are the buffer that is used

in the dialysate (lactate vs bicarbonate) and the acidity of the solution. From *in vitro* and animal experiments, it can be concluded that biocompatible solutions, characterised by a physiological pH, more bicarbonate vs lactate, and fewer GDPs, are less toxic to the peritoneal membrane.¹² So far, the superiority of these solutions with regard to the occurrence of EPS has not been demonstrated in clinical trials. Because of the apparent rise in the incidence of EPS during recent years, an association with the more widespread use of the glucose polymer icodextrin as osmotic agent in PD solutions has been suggested.⁶ Although the use of icodextrin has been associated with an increased peritoneal inflammatory response,¹³ there are insufficient data to draw a strong conclusion on this subject.

A second risk factor for the development of EPS is the occurrence of refractory and recurrent PD peritonitis.^{2,4,14} *Staphylococcus aureus* and coagulase-negative *Staphylococcus* are the organisms most commonly involved in these episodes of peritonitis. These bacteria have the enzymatic activity to convert fibrinogen to fibrin, which is the major matrix component of intestinal adhesions. Recently, a fulminant form of peritoneal sclerosis was described as a second phase phenomenon immediately following treatment of acute bacterial peritonitis. Treatment with prednisolone appeared to be particularly effective in this setting.¹⁵ However, EPS also occurs in patients who have never experienced PD peritonitis, and in a recent study of 810 PD patients, no differences in peritonitis rates were found between patients who developed EPS and those who did not.⁵

Histologically, EPS involves proliferation of peritoneal fibroblasts and deposition of extracellular matrix. The latter is stimulated by transforming growth factor- β 1 (TGF- β 1), and mRNA expression of TGF- β 1 may persist in patients with frequent peritonitis.¹⁶ Interestingly, the calcineurin inhibitors cyclosporine and tacrolimus that are frequently used for immunosuppression after transplantation, have been reported to induce TGF- β production and might contribute to progression of fibrosis.¹⁷⁻¹⁹

A Japanese multicentre survey showed that in 68.8% of the most recent EPS patients, EPS became manifest after discontinuation of PD and catheter removal in relation to kidney transplantation.^{1,14} Apparently, besides progression of peritoneal remodelling that happens with long-term PD, additional factors play a role in the progression of EPS.²⁰ It can be speculated that discontinuation of PD facilitates the progression of peritoneal fibrosis because inflammatory substances and fibrin are no longer efficiently removed from the peritoneal cavity. Furthermore, adhesiolysis by the instilled dialysate might be lost after discontinuation of PD.

Diagnosis

As the prognosis of established EPS is poor, early recognition of preceding symptoms is essential. Features suggestive of early peritoneal sclerosis include the

Table 1. Risk factors for encapsulating peritoneal sclerosis⁹

PD-dependent factors	PD-independent factors
Duration of PD	β -blocker use
Poor biocompatibility of dialysate: <ul style="list-style-type: none"> • Acetate or lactate buffer • Acidity • Glucose • High osmolality • Plasticiser 	Genetic predisposition
Poor biocompatibility of other chemicals: <ul style="list-style-type: none"> • Disinfectants, chlorhexidine • Antibiotics 	
High-transporter membrane	

development of a high transporter state of the peritoneal membrane, a decrease in sodium sieving, a loss of ultrafiltration capacity, and a decrease in mesothelial cell mass as reflected by a low peritoneal fluid CA-125 content. However, these symptoms are not specific, which makes early recognition difficult. As a result, the diagnosis is usually made only when the patient has an established EPS with symptoms of partial or complete intestinal obstruction, as the cases A, B, and C clearly illustrate. At this stage, CT of the abdomen provides a reliable and noninvasive diagnostic tool. Typical CT features of EPS include peritoneal calcification, bowel wall thickening, peritoneal thickening, loculated fluid collections, and tethered bowel loops (*figure 1*). These findings are diagnostic of EPS in the appropriate clinical setting.²¹ Histological findings in a peritoneal biopsy include a very thick sclerosing tissue (1000 to 4000 μm , vs 10 to 70 μm in normal conditions)²² involving the whole peritoneal wall, often with inflammatory infiltrates, microabscesses, giant cells originating from macrophages, calcifications, and severe vascular alterations.²³

Treatment

There is no evidence-based therapy available for EPS,^{8,24} so treatment advice is mainly based on anecdotal case reports. Discontinuation of PD is the logical first step of therapy. Additional treatment options include immunosuppressive therapy, surgical treatment, tamoxifen and, if needed, enteric rest with total parenteral nutrition.

Immunosuppressive therapy has been shown to be effective in some cases and has been associated with improved survival.⁵ Some patients have markers of acute inflammation such as a high C-reactive protein level in serum or high interleukin-6 levels in the dialysate,¹³ and in these cases treatment with corticosteroids, as in patient D, might be useful. Calcineurin inhibitors should be used with caution because they can induce TGF- β 1 production and thus contribute to the progression of tissue fibrosis.¹⁹ Surgical treatment can be considered when symptoms of EPS are not improved by steroid administration or total parenteral nutrition. The surgical procedure consists of total intestinal enterolysis, without damaging the capsule-covered intestine. In one Japanese study of 50 patients with EPS who were treated in this manner, 46 patients experienced complete relief, two patients maintained mild symptoms that could be successfully controlled by diet, and two patients died after perforation of the small intestine.²⁵ Continuation of PD following successful surgical treatment was reported to be possible in four patients for an average duration of 16 months (range 1 to 32).²³ However, these successful results have not yet been reproduced by non-Japanese groups. In a British single-centre study of 13 patients who underwent surgery for EPS, there were four perioperative deaths,

corresponding with a surgical mortality of 31%.⁵ After surgery, recurrence of intestinal encapsulation can occur.

In 1999 *Allaria et al.* reported the first case of EPS successfully treated with tamoxifen. This patient showed a gradual recovery of symptoms as well as a significant reduction in the thickness of peritoneal and intestinal loops.^{26,27} Small case series have confirmed these beneficial findings.²⁸ One should keep in mind that tamoxifen produces oestrogenic-like effects on certain tissues, and can lead to an increased incidence of venous thromboembolism.²⁹ Therefore, it has been recommended to withhold this treatment in patients with a known hypercoagulable state, such as activated protein C resistance due to factor V Leiden.³⁰

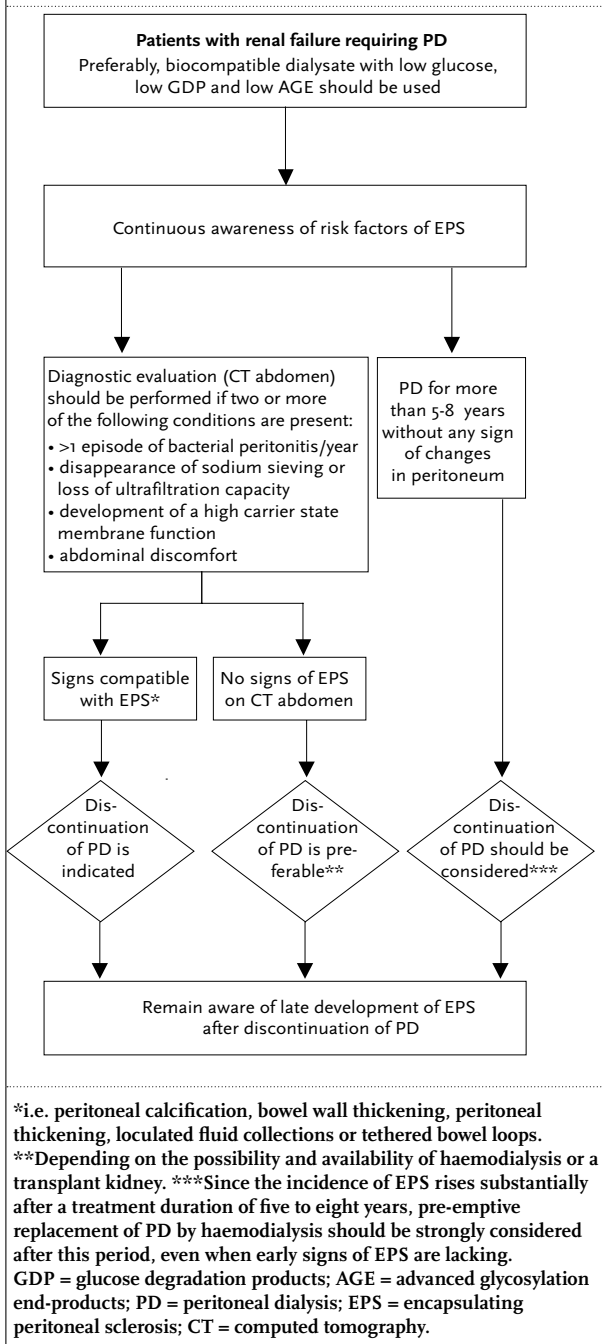
Prognosis and prevention

The cases described above show that the course of EPS is highly variable. In general, the prognosis of EPS is poor and is related to the duration of PD. The incidence (and mortality rate) of EPS was 0%, 0.7% (0%), 2.1% (8.3%), 5.9% (28.6%), 5.8% (61.5%), and 17.2% (100%) in patients who had undergone peritoneal dialysis for 3, 5, 8, 10, 15, and more than 15 years, respectively.¹

Earlier diagnosis, the use of biocompatible dialysates with nonglucose osmotic agents, and immunosuppressive therapy may improve outcome for such patients in the future.²¹ Careful radiological monitoring in patients on PD for more than five years, with early catheter removal if peritoneal thickening is detected, is recommended.⁵ To preserve the peritoneum it has been recommended to reduce membrane exposure to the bioincompatible glucose-containing, lactate-buffered solutions. Instead of glucose, amino-acids or icodextrin can be used as osmotic agents. Moreover, the production of dialysis bags with two compartments allows the preparation of dialysis solutions with a higher pH, bicarbonate as buffer, and a reduced concentration of GDPs.¹⁰ Finally, some controversial or experimental measures to prevent the occurrence of EPS are reported: (1) pre-emptive discontinuation of PD after a finite period of PD therapy or when early signs of EPS are evident, (2) prophylactic peritoneal lavage after PD cessation, or (3) medications that may ameliorate inflammation or minimise fibrin deposition.⁹

Based on the currently available literature, including the algorithm described by Kawaguchi *et al.*,²⁴ we suggest the following guideline (see also *figure 2*). At any time, the clinician must be aware of the risk of EPS development. Diagnostic evaluation, i.e. CT, should be performed when two or more of the following conditions are present: (1) frequent occurrence of bacterial peritonitis (more than one episode per year), (2) disappearance of sodium sieving or loss of ultrafiltration capacity, (3) development of a high carrier state membrane function, (4) abdominal discomfort.

Figure 2. Proposal for an EPS prevention guideline



When signs compatible with EPS are demonstrated, PD should be discontinued immediately. When CT shows no abnormalities, the decision to replace PD by haemodialysis will also depend on other factors such as the expected near availability of a transplant kidney, the possibility of creating a vascular access, and the ability of the patient to tolerate higher ultrafiltration rates during haemodialysis. Since the incidence of EPS rises substantially after a treatment duration of five to eight years, pre-emptive replacement of PD by haemodialysis should be strongly considered after this period, even when early signs of EPS are lacking.

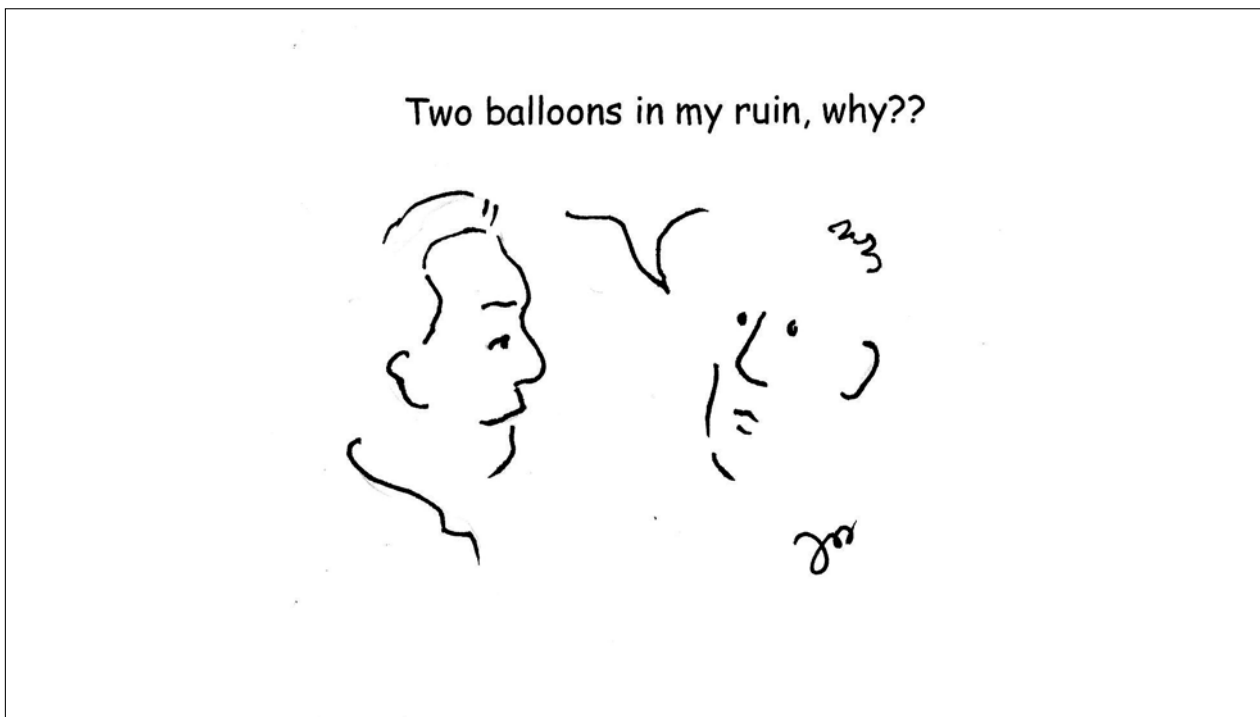
CONCLUSION

EPS is an infrequent but very severe complication in patients on long-term PD and is characterised by extensive intraperitoneal fibrosis, encasement of bowel loops, malnutrition and bowel obstruction. Risk factors include duration of PD, recurrent episodes of PD peritonitis, and exposure to hypertonic glucose-containing peritoneal solutions. EPS should be suspected in PD patients with symptoms suggestive of an ileus. CT can confirm the diagnosis. Although several therapeutic options have been described, an evidence-based therapy is still lacking. The most favoured approach is discontinuation of PD and treatment with corticosteroids and tamoxifen. When symptoms are not alleviated, surgical enterolysis can be considered. The prognosis of EPS is poor and prevention is difficult. Therefore, early recognition of this clinical syndrome followed by proper treatment is essential.

REFERENCES

1. Kawanishi H, Kawaguchi Y, Fukui H, et al. Encapsulating peritoneal sclerosis in Japan: a prospective, controlled, multicenter study. *Am J Kidney Dis* 2004;44:729-37.
2. Rigby RJ, Hawley CM. Sclerosing peritonitis: the experience in Australia. *Nephrol Dial Transplant* 1998;13:154-9.
3. Gandhi VC, Humayun HM, Ing TS, et al. Sclerotic thickening of the peritoneal membrane in maintenance peritoneal dialysis patients. *Arch Intern Med* 1980;140:1201-3.
4. Kawaguchi Y, Kawanishi H, Mujais S, Topley N, Oreopoulos DG. Encapsulating peritoneal sclerosis: definition, etiology, diagnosis, and treatment. International Society for Peritoneal Dialysis Ad Hoc Committee on Ultrafiltration Management in Peritoneal Dialysis. *Perit Dial Int* 2000;20(suppl 4):S43-55.
5. Summers AM, Clancy MJ, Syed F, et al. Single-center experience of encapsulating peritoneal sclerosis in patients on peritoneal dialysis for end-stage renal failure. *Kidney Int* 2005;68:2381-8.
6. Korte MR, Yo M, Betjes MG, et al. Increasing incidence of severe encapsulating peritoneal sclerosis after kidney transplantation. *Nephrol Dial Transplant* 2007;22:2412-4.
7. Fieren MW, Betjes MG, Korte MR, Boer WH. Posttransplant encapsulating peritoneal sclerosis: a worrying new trend? *Perit Dial Int* 2007;27:619-24.
8. Cancarini GC, Sandrini M, Vizzardi V, Bertoli S, Buzzi L, Maiorca R. Clinical aspects of peritoneal sclerosis. *J Nephrol* 2001;14(suppl 4):S39-47.
9. Chin AI, Yeun JY. Encapsulating peritoneal sclerosis: an unpredictable and devastating complication of peritoneal dialysis. *Am J Kidney Dis* 2006;47:697-712.
10. Krediet RT, Zweers MM, van Westrhenen R, Ho-Dac-Pannekeet MM, Struijk DG. What can we do to preserve the peritoneum? *Perit Dial Int* 2003;23(suppl 2):S14-9.
11. Davies SJ, Phillips L, Naish PF, Russell GI. Peritoneal glucose exposure and changes in membrane solute transport with time on peritoneal dialysis. *J Am Soc Nephrol* 2001;12:1046-51.
12. Ter Wee PM, van Ittersum FJ. The new peritoneal dialysis solutions: friends only, or foes in part? *Nat Clin Pract Nephrol* 2007;3:604-12.
13. Moriishi M, Kawanishi H, Tsuchiya S. Impact on peritoneal membrane of use of icodextrin-based dialysis solution in peritoneal dialysis patients. *Adv Perit Dial* 2006;22:24-8.

14. Nomoto Y, Kawaguchi Y, Kubo H, Hirano H, Sakai S, Kurokawa K. Sclerosing encapsulating peritonitis in patients undergoing continuous ambulatory peritoneal dialysis: a report of the Japanese Sclerosing Encapsulating Peritonitis Study Group. *Am J Kidney Dis* 1996;28:420-7.
15. Courtney AE, Doherty CC. Fulminant sclerosing peritonitis immediately following acute bacterial peritonitis. *Nephrol Dial Transplant* 2006;21:532-4.
16. Lin CY, Chen WP, Yang LY, Chen A, Huang TP. Persistent transforming growth factor-beta 1 expression may predict peritoneal fibrosis in CAPD patients with frequent peritonitis occurrence. *Am J Nephrol* 1998;18:513-9.
17. Ghellai AM, Stucchi AF, Chegini N, et al. Role of transforming growth factor beta-1 in peritonitis-induced adhesions. *J Gastrointest Surg* 2000;4:316-23.
18. Margetts PJ, Bonniaud P. Basic mechanisms and clinical implications of peritoneal fibrosis. *Perit Dial Int* 2003;23:530-41.
19. Khanna A, Cairns V, Hosenpud JD. Tacrolimus induces increased expression of transforming growth factor-beta1 in mammalian lymphoid as well as nonlymphoid cells. *Transplantation* 1999;67:614-9.
20. Yamamoto R, Otsuka Y, Nakayama M, et al. Risk factors for encapsulating peritoneal sclerosis in patients who have experienced peritoneal dialysis treatment. *Clin Exp Nephrol* 2005;9:148-52.
21. George C, Al-Zwae K, Nair S, Cast JE. Computed tomography appearances of sclerosing encapsulating peritonitis. *Clin Radiol* 2007;62:732-7.
22. Garosi G, Di Paolo N, Sacchi G, Gaggiotti E. Sclerosing peritonitis: a nosological entity. *Perit Dial Int* 2005;25(suppl 3):S110-2.
23. Klimopoulos S, Katsoulis IE, Margellos V, Nikolopoulou N. Sclerosing encapsulating peritonitis secondary to CAPD: the effect of fibrotic debridement on further dialysis. *J R Coll Surg Edinb* 2002;47:485-90.
24. Kawaguchi Y, Saito A, Kawanishi H, et al. Recommendations on the management of encapsulating peritoneal sclerosis in Japan, 2005: diagnosis, predictive markers, treatment, and preventive measures. *Perit Dial Int* 2005;25(suppl 4):S83-95.
25. Kawanishi H, Watanabe H, Moriishi M, Tsuchiya S. Successful surgical management of encapsulating peritoneal sclerosis. *Perit Dial Int* 2005;25(suppl 4):S39-47.
26. Moustafellos P, Hadjianastassiou V, Roy D, et al. Tamoxifen therapy in encapsulating sclerosing peritonitis in patients after kidney transplantation. *Transplant Proc* 2006;38:2913-4.
27. Allaria PM, Giangrande A, Gandini E, Pisoni IB. Continuous ambulatory peritoneal dialysis and sclerosing encapsulating peritonitis: tamoxifen as a new therapeutic agent? *J Nephrol* 1999;12:395-7.
28. Eltoun MA, Wright S, Atchley J, Mason JC. Four consecutive cases of peritoneal dialysis-related encapsulating peritoneal sclerosis treated successfully with tamoxifen. *Perit Dial Int* 2006;2:203-6.
29. Cosman F, Baz-Hecht M, Cushman M, et al. Short-term effects of estrogen, tamoxifen and raloxifene on hemostasis: a randomized-controlled study and review of the literature. *Thromb Res* 2005;116:1-13.
30. Weitz IC, Israel VK, Liebman HA. Tamoxifen-associated venous thrombosis and activated protein C resistance due to factor V Leiden. *Cancer* 1997;79:2024-7.



Double balloon enteroscopy for endoscopic retrograde cholangiopancreatography after Roux-en-Y reconstruction: case series and review of the literature

J.J. Koornstra

Department of Gastroenterology and Hepatology, University Medical Centre Groningen, University of Groningen, Groningen, the Netherlands, tel.: +31 (0)50-361 33 54, fax: +31 (0)50-361 93 06, e-mail: j.j.koornstra@int.umcg.nl

ABSTRACT

Background: Endoscopic access to the biliary system can be difficult in patients with surgically altered anatomy, such as a Roux-en-Y reconstruction. Double balloon enteroscopy (DBE) is a relatively new procedure that enables access to the small bowel. DBE has recently been advocated as a method for endoscopic retrograde cholangiopancreatography (ERCP) in patients with surgical reconstructions, with the potential to perform diagnostic and therapeutic interventions.

Methods: In three patients with a hepaticojejunostomy and Roux-en-Y reconstruction, the experiences using DBE to perform ERCP are described. The literature on DB-ERCP in patients with a Roux-en-Y reconstruction was reviewed.

Results: In all patients, the Roux limb was entered and a diagnostic cholangiography was carried out. In one patient, endoscopic therapy could be performed, consisting of balloon dilation of a stenotic biliodigestive anastomosis, repeated balloon dilation of biliary strictures and removal of bile casts.

Conclusion: This series confirms recent data emerging from the literature that double balloon enteroscopy is a safe and feasible technique to obtain biliary access in patients with surgically altered anatomical configurations, such as those with a Roux-en-Y reconstruction. The diagnostic and therapeutic potential of DB-ERCP is great, and the utility of the procedure could be further improved if customised accessories become more widely available.

KEYWORDS

Double balloon endoscopy, double balloon enteroscopy, ERCP, liver transplantation, Roux-en-Y

INTRODUCTION

Patients with altered anatomy, such as those with a Billroth II gastrojejunostomy or a biliodigestive anastomosis with Roux-en-Y reconstruction, pose a serious challenge to the endoscopist when access to the biliary system is required.¹ The Roux-en-Y reconstruction is a frequently used method of surgical reconstruction, which consists of the construction of a Y-branched jejunal limb. Roux-en-Y reconstructions are common in gastric bypass surgery (for obesity), after pylorus-preserving pancreaticoduodenectomy (PPPD) or after bile duct or liver surgery.² Diagnostic possibilities of suspected pancreatic or biliary diseases in patients with a Roux-en-Y reconstruction are limited and generally confined to magnetic resonance cholangiopancreatography (MRCP). Therapeutic or interventional options in these patients consist of endoscopic retrograde cholangiopancreatography (ERCP), percutaneous transhepatic cholangiography (PTC) or surgery.

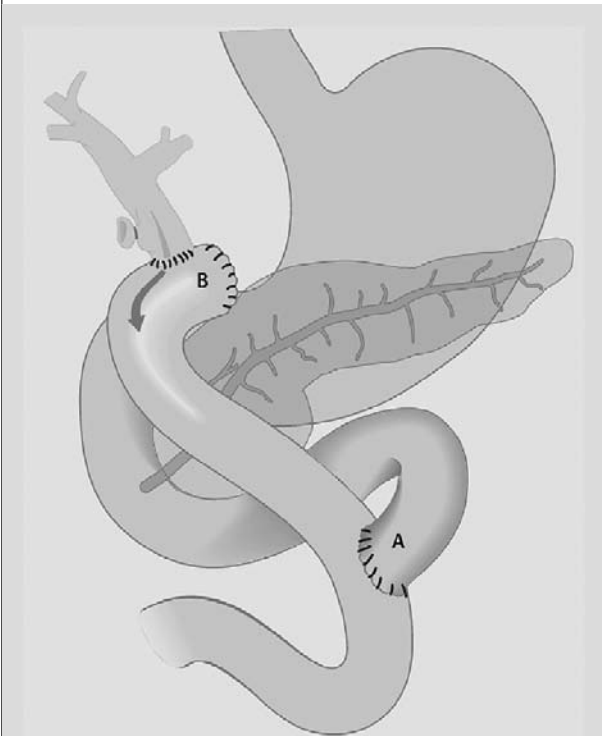
ERCP can be difficult in patients with surgically altered small bowel anatomy. One of the problems is the length of small bowel that has to be traversed to reach the bypassed small bowel limb and the biliary system. In patients after Billroth II reconstructive surgery, Whipple resection or PPPD, in which the gastric stump (BII, Whipple) or duodenal cap (PPPD) is anastomosed with the jejunum, the distance is relatively short. Access to the biliary tree in these situations is generally achievable with forward viewing endoscopes such as a standard gastroduodenoscope, a paediatric colonoscope or a push enteroscope.³ In contrast, patients with a Roux-en-Y reconstruction with a jejunojejunostomy distal from the ligament of Treitz have a long segment of small bowel that needs to be traversed to gain access to the Roux limb. In these cases,

the endoscope has to be advanced past the ligament of Treitz into the jejunum until the jejunojejunostomy is reached, and then another 40 to 80 cm up the Roux limb.³ This anatomical situation (*figure 1*), which is common after orthotopic liver transplantation (OLT) or biliary diversion procedures, is usually inaccessible for conventional endoscopes.⁴ Unfortunately, many patients develop biliary complications after OLT including anastomotic and nonanastomotic strictures.⁴ Endoscopic management of these complications is commonly difficult if a hepaticojejunostomy with Roux-en-Y reconstruction is present and often necessitates an alternative technique such as a percutaneous transhepatic approach. The introduction of the double balloon enteroscope (DBE) in 2001 has allowed endoscopic access into the small bowel.⁵ Recent data indicate that DBE also facilitates endoscopic entry into previously inaccessible areas and anatomical configurations that result from small bowel surgery.¹ In this report, the safety and feasibility of the DBE technique is described in a series of three patients with surgically altered anatomy in whom access to the biliary system was required. In addition, the currently available literature on DBE for ERCP in patients with a Roux-en-Y reconstruction was reviewed.

CASE REPORTS

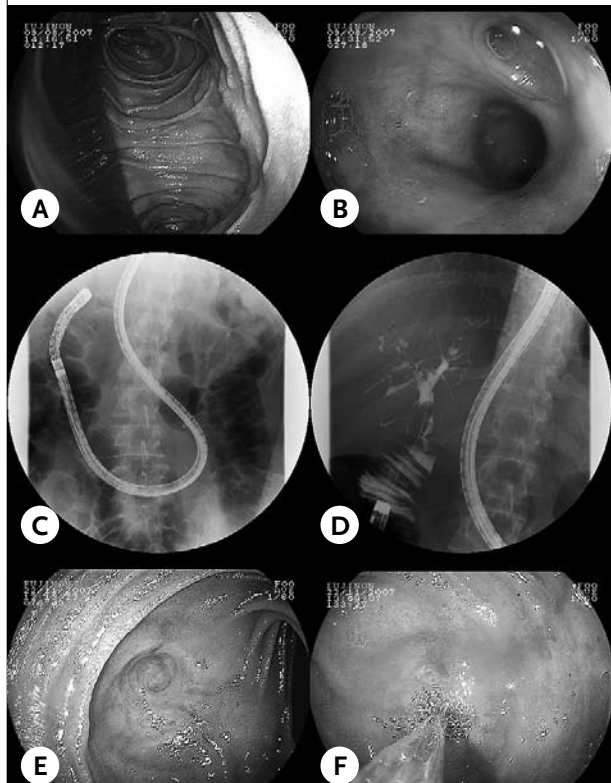
Case report 1, a 58-year-old female, was referred for evaluation of recurrent cholangitis. She had undergone a hepaticojejunostomy with Roux-en-Y reconstruction at the age of 38 for recurrent episodes of cholangitis. A liver biopsy at that time showed sclerosing cholangitis. Over the years, repeated periods of cholangitis occurred with increasing frequency. There was debate as to whether the frequent attacks of cholangitis were to be attributed to a stenotic hepaticojejunostomy or due to intrahepatic biliary strictures associated with sclerosing cholangitis. Endoscopy with conventional endoscopes was considered impossible, so a DBE was performed. The jejunojejunostomy was reached approximately 40 cm downstream of the ligament of Treitz (*figure 2A*). Under fluoroscopic control, the endoscope was then advanced into the Roux limb until the hepaticojejunostomy came into view (*figure 2B*). The hepaticojejunostomy did not appear stenotic (*figure 2C*). Cholangiography, using a 10 to 12 mm diameter controlled

Figure 1. Typical anatomy after hepaticojejunostomy with Roux-en-Y reconstruction showing A) the jejunojejunal anastomosis and B) the end-to-side hepaticojejunostomy¹



Source: Thieme Verlag.

Figure 2. A-D) Images of a 58-year-old female and E/F) a 27-year-old male



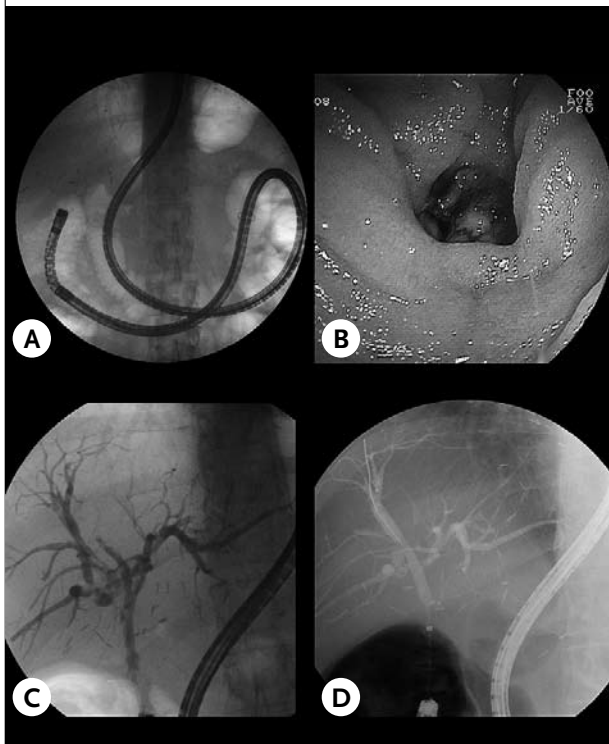
A) Endoscopic view of the jejunojejunal anastomosis. B) Endoscopic view of the opening of the hepaticojejunostomy, which appears normal. C) Fluoroscopic image of the endoscope and overtube advanced into the Roux limb. D) Cholangiography with inflated CRE balloon showing diffuse stricturing and dilation of biliary branches consistent with sclerosing cholangitis. E) Endoscopic view of the opening of the hepaticojejunostomy, which appears stenotic. F) Endoscopic view of an inflated balloon catheter in the opening of the hepaticojejunostomy.

radial expansion (CRE) balloon (Boston Scientific, Galway, Ireland), inflated in the biliodigestive anastomosis, showed diffuse intrahepatic strictures and dilation of biliary branches, consistent with sclerosing cholangitis (*figure 2D*). The abnormalities were considered unsuitable for endoscopic therapy. Given these findings and the endoscopically proven patency of the hepaticojejunostomy, the patient was listed for liver transplantation.

Case report 2, a 27-year-old male, was born with biliary atresia, for which a hepatoportoenterostomy, also known as Kasai procedure, was performed. At the age of 4, OLT was carried out, with a hepaticojejunostomy with Roux-en-Y reconstruction. For more than 20 years, follow-up was uneventful. He then developed cholestatic liver function tests. Abdominal ultrasonography revealed no abnormalities. A liver biopsy was performed showing signs of cholestatic disease, but no signs of rejection. An MRCP was performed, showing filling defects at the site of the central biliary branches. A DBE was performed, during which the Roux limb was accessed until the hepaticojejunostomy came into sight. The anastomosis appeared stenotic (*figure 2E*). Cholangiography, using an inflated 8 mm dilation balloon (Cook, Limerick, Ireland), showed numerous filling defects above the stenosis, suggestive of bile duct stones (*figure 2F*). Unfortunately, it was not possible to pass a guidewire through the anastomosis to perform balloon dilation or stone removal. The patient was therefore referred for surgery. Laparotomy revealed multiple biliary stones located just above a fibrotic hepaticojejunostomy. The bile ducts were cleared and a new hepaticojejunostomy was created. Following surgery, the liver function abnormalities gradually disappeared.

Case report 3, a 50-year-old male, underwent OLT for recurrent cholangitis in primary sclerosing cholangitis. A hepaticojejunostomy with Roux-en-Y reconstruction was carried out. Just six weeks after OLT, he developed severe cholangitis. An MRCP was performed which showed filling defects in the central biliary branches and suspicion of bile casts at the site of the hepaticojejunostomy. A DBE was performed seven weeks after OLT. Access into the Roux limb was obtained (*figure 3A*). At the hepaticojejunostomy, an obstructing bile cast was seen (*figure 3B*), which was removed with a biopsy forceps. The opening of the hepaticojejunostomy appeared small. Cholangiography using an inflated 8 mm CRE balloon showed filling defects in the distal biliary tree and several strictures of intrahepatic biliary branches (*figure 3C*). Balloon dilation with the 8 mm CRE balloon was performed for the hepaticojejunostomy and a few intrahepatic strictures (*figure 3D*). Not all strictures were treated as it was not possible to pass a guidewire through some strictures. The procedure was complicated by an *E. coli* bacteraemia

Figure 3. Images of a 50-year-old male



A) Fluoroscopic image of the endoscope advanced into the Roux limb. B) Endoscopic image of a hepaticojejunostomy obstructed by bile casts. C) Cholangiography showing irregular central bile ducts. D) Fluoroscopic image of balloon dilation of the right hepatic duct using an 8 mm CRE balloon.

the day after the procedure, probably due the extensive manipulation in the biliary system, which was successfully treated with antibiotics. Six weeks after the first procedure, a second DB-ERCP was performed, with additional dilation of biliary strictures. This procedure had an uncomplicated course.

DISCUSSION

This report illustrates the possibilities to diagnose and treat biliary abnormalities using double balloon enteroscopy in patients after surgery resulting in altered small bowel anatomy. In all of the three cases presented here, access to the Roux limb was obtained and a diagnostic cholangiography carried out, and therapeutic interventions were performed in one patient (*table 1*). These results are in line with recent reports that demonstrated the safety and feasibility of the DBE procedure for this indication. The DBE procedure, introduced in 2001, is based on the combined use of a balloon-loaded enteroscope and a similarly balloon-loaded overtube.⁵ The enteroscope has a working length of 200 cm and an outer diameter of 8.5 mm. The 12-mm-diameter overtube has a length of 140 cm. Alternately inflating and deflating the two

Table 1. Summary of four DB-ERCP procedures in three patients with a Roux-en-Y reconstruction

Case	Anatomy	Access into Roux limb	Diagnostic cholangiography	Therapeutic intervention	Complications
1	Roux-en-Y hepaticojejunostomy	Yes	Yes	Considered not indicated	None
2	OLT with a Roux-en-Y hepaticojejunostomy	Yes	Yes	Not possible	None
3*	OLT with a Roux-en-Y hepaticojejunostomy	Yes	Yes	Balloon dilation; cast removal	Bacteraemia
		Yes	Yes	Balloon dilation	None

OLT = orthotopic liver transplantation; *patient underwent two DB-ERCP procedures.

balloons and straightening the endoscope with the overtube achieves a stepwise progression of the enteroscope throughout the small intestine.⁵ There are two available DBE scopes: a diagnostic scope (EN-450P5, Fujinon Corp, Saitama, Japan) which has a working channel diameter of 2.0 mm, and a therapeutic scope (EN-450T5, Fujinon), with a 2.8 mm diameter working channel. Both endoscopes have a length of 200 cm. DBE has revolutionised the ability to visualise the small bowel. Currently available in 14 hospitals in the Netherlands, DBE is now routinely applied for the diagnosis and therapy of small bowel pathology, and to perform colonoscopy in patients with previously failed colonoscopy.^{6,7} The DBE technique allows endoscopic interventions such as mucosal biopsy, argon plasma coagulation, polypectomy, injection therapy and balloon dilation.^{6,7} Relative limitations of the technique are that DBE is an invasive and time-consuming procedure. The risk of complications is low, especially for diagnostic DBE procedures. In a recent survey, reporting on 2362 DBE procedures, the complication rate of diagnostic DBE procedures was 0.8% and that of therapeutic DBE procedures 4.3%.⁸

As illustrated in this report, the DBE technique can also be used in patients with altered small intestinal anatomy. A few aspects of the technique in this setting deserve attention. First, as it is important in patients with a Roux-en-Y reconstruction to recognise the jejunojejunal anastomosis and determine the limb that needs to be accessed, the procedure is best performed under fluoroscopic control, while DBE procedures for other indications are generally not performed under fluoroscopy. If the enteroscope is at the desired position in the Roux limb, the overtube should be advanced just behind the enteroscope, to fix the overtube and allow the enteroscope to approach the biliary system as flexibly as possible. Access to a hepaticojejunostomy is probably easier than a native major papilla given the fact that the endoscope is forward viewing and the straight angle with which accessories can be advanced. The endoscopic aspect of a hepaticojejunostomy can instantly be assessed, for example to determine whether an anastomotic stricture is present.

In this series, all four procedures were performed under fluoroscopic control with the patient placed in the prone position. In all procedures, the therapeutic double balloon endoscope was used. Three procedures were performed using conscious sedation, one under general anaesthesia. Antibiotics were routinely given prior to the procedure to diminish the risk of cholangitis as a consequence of instrumental manipulation. Apart from one case of post-procedure bacteraemia, there were no complications. An important issue is that of the accessories that can be used with this type of scope. There is a limited availability of suitable equipment, as all accessories have to be of sufficient length. Unfortunately for double balloon endoscopists, there is a current trend in ERCP equipment to develop shorter rather than longer accessories.⁹ Available accessories of sufficient length that can be used for DBE are guidewires, biopsy forceps, dilation balloons (CRE balloon catheter, Boston Scientific; biliary balloon dilation catheters, Cook), snares and argon plasma coagulator probes. At present, there is a lack of needle knives, sphincterotomes, extraction balloons, lithotripsy devices and retrieval baskets customised for the DBE system. In my view, cannulation and cholangiography with DBE in patients with a hepaticojejunostomy are best achieved with a CRE balloon. CRE balloons are available in many diameters (6-8 mm, 8-10 mm etcetera up to 18-20 mm), which can all be inserted through the working channel of the therapeutic DBE scope.

Recently, several others have reported their experience with the use of DBE in patients with a Roux-en-Y reconstruction.^{1,10-16} A review of these studies, updated until March 2008, is summarised in *table 2*. In total, data are available on 40 patients (age range 2 to 81 years). In 90% of patients (36/40), access into the Roux limb was obtained. A diagnosis was made in 80% of cases (32/40), based on findings of cholangiography and direct visualisation of the biliodigestive anastomosis. In those patients in whom therapeutic interventions were attempted, ERCP was successful in 77% of cases (20/26). Interventions such as balloon dilation, biliary stent placement, biliary stone extraction and pancreatic duct interventions have proved

Table 2. Overview of reports on DB-ERCP in patients with a Roux-en-Y reconstruction

Author, reference	n	Age	Type of surgery	Type of intervention
Haruta, 10	1	7	OLT with Roux-en-Y jejunojejunostomy and choledochojejunostomy	Repeated balloon dilation of stenotic hepaticojejunostomy
Mehdizadeh, 11	7	No data available	Postcholecystectomy Roux-en-Y hepaticojejunostomy	Balloon dilation of stenotic hepaticojejunostomy
Emmett, 12	14	27-73	Various (mostly Roux-en-Y gastric bypass and Whipple with pancreaticojejunostomy)	Balloon dilation; sphincterotomy; biliary stent placement; pancreatic stent placement and removal
Moreels, 13	1	72	Roux-en-Y hepaticojejunostomy	Balloon dilation of stenotic hepaticojejunostomy; biliary stent placement
Spahn, 14	1	34	Roux-en-Y hepaticojejunostomy	Balloon dilation of stenotic hepaticojejunostomy and stone removal
Chu, 15	1	79	Roux-en-Y gastrojejunostomy	Sphincterotomy and stone removal
Monkemuller, 16	2	58-60	Roux-en-Y gastrojejunostomy Pylorus-preserving pancreaticoduodenectomy with Roux-en-Y hepaticojejunostomy	Biliary stent placement and removal; balloon dilation of stenotic hepaticojejunostomy
Aabakken, 1	13	2-81	Various (mostly OLT with Roux-en-Y jejunojejunostomy and hepaticojejunostomy)	Biliary stent placement and removal; stone removal

OLT = orthotopic liver transplantation.

to be technically possible. Serious complications were not encountered in any of the reports. As such, the risk of complications using DBE for ERCP seems to be lower than that of percutaneous transhepatic biliary interventions, which is estimated to be around 5%.¹⁷

CONCLUSION

Double balloon enteroscopy has allowed endoscopists to access intestinal areas which until recently were inaccessible with the conventional endoscopes. Even after surgical procedures such as a Roux-en-Y reconstruction, diagnostic and therapeutic endoscopic interventions are feasible and safe. In Roux-en-Y patients with a suspected stricture of a hepaticojejunostomy or suspected choledocholithiasis, DB-ERCP should strongly be considered. The value of the procedure could further be improved by expanding the currently limited availability of adapted accessories.

REFERENCES

- Aabakken L, Bretthauer M, Line PD. Double-balloon enteroscopy for endoscopic retrograde cholangiography in patients with a Roux-en-Y anastomosis. *Endoscopy* 2007;39:1068-71.
- Haber GB. Double balloon endoscopy for pancreatic and biliary access in altered anatomy (with videos). *Gastrointest Endosc* 2007;66(suppl):S47-50.
- Çiçek B, Parlak E, Dişibeyaz S, Koksak AS, Sahin B. Endoscopic retrograde cholangiopancreatography in patients with Billroth II gastroenterostomy. *J Gastroenterol Hepatol* 2007;22:1210-3.
- Verdonk RC, van den Berg AP, Slooff MJ, Porte RJ, Haagsma EB. Liver transplantation: an update. *Neth J Med* 2007;65:372-80.
- Yamamoto H, Sekine Y, Sato Y, et al. Total enteroscopy with a nonsurgical steerable double-balloon method. *Gastrointest Endosc* 2001;53:216-20.
- Heine GD, Hadithi M, Groenen MJ, et al. Double-balloon enteroscopy: indications, diagnostic yield, and complications in a series of 275 patients with suspected small-bowel disease. *Endoscopy* 2006;38:42-48.
- Zhong J, Ma T, Zhang C, et al. A retrospective study of the application on double-balloon enteroscopy in 378 patients with suspected small-bowel diseases. *Endoscopy* 2007;39:208-15.
- Mensink PB, Haringsma J, Kucharzik T, et al. Complications of double balloon enteroscopy: a multicenter survey. *Endoscopy* 2007;39:613-5.
- Joyce AM, Ahmad NA, Beilstein MC, et al. Multicenter comparative trial of the V-scope system for therapeutic ERCP. *Endoscopy* 2006;38:713-6.
- Haruta H, Yamamoto H, Mizuta K, et al. A case of successful enteroscopic balloon dilation for late anastomotic stricture of choledochojejunostomy after living donor liver transplantation. *Liver Transpl* 2005;11:1608-10.
- Mehdizadeh S, Ross A, Gerson L, et al. What is the learning curve associated with double-balloon enteroscopy? Technical details and early experience in 6 U.S. tertiary care centers. *Gastrointest Endosc* 2006;64:740-50.
- Emmett DS, Mallat DB. Double-balloon ERCP in patients who have undergone Roux-en-Y surgery: a case series. *Gastrointest Endosc* 2007;66:1038-41.
- Moreels TG, Roth B, Vandervliet EJ, Parizel PM, Dutré J, Pelckmans PA. The use of the double-balloon enteroscope for endoscopic retrograde cholangiopancreatography and biliary stent placement after Roux-en-Y hepaticojejunostomy. *Endoscopy* 2007;39(suppl 1):E196-7.
- Spahn TW, Grosse-Thie W, Spies P, Mueller MK. Treatment of choledocholithiasis following Roux-en-Y hepaticojejunostomy using double-balloon enteroscopy. *Digestion* 2007;75:20-1.
- Chu YC, Su SJ, Yang CC, Yeh YH, Chen CH, Yueh SK. ERCP plus papillotomy by use of double-balloon enteroscopy after Billroth II gastrectomy. *Gastrointest Endosc* 2007;66:1234-6.
- Mönkemüller K, Bellutti M, Neumann H, Malfertheiner P. Therapeutic ERCP with the double-balloon enteroscope in patients with Roux-en-Y anastomosis. *Gastrointest Endosc* 2008;67:992-6.
- Winick AB, Waybill PN, Venbrux AC. Complications of percutaneous transhepatic biliary interventions. *Tech Vasc Interv Radiol* 2001;4:200-6.

Liver transplantation in a patient with encapsulating peritoneal sclerosis

W.H. de Vos tot Nederveen Cappel¹, J. Dubbeld², S.M. Willems³, J. Ringers², B. van Hoek^{1*}

Departments of ¹Gastroenterology and Hepatology, ²Surgery and ³Pathology, Leiden University Medical Centre, the Netherlands, *corresponding author: tel.: +31 (0)71-526 35 07, fax: +31 (0)71-524 81 15, e-mail: bvhoek@lumc.nl

ABSTRACT

Encapsulating peritoneal sclerosis (EPS) is a poorly understood condition in which excess fibrosis results in an encasement of the small bowel, which can clinically result in obstruction. The condition is thought to be related to the persistent expression of transforming growth factor beta on mesothelial cells causing proliferation of subserosal fibroblasts, massive production of extracellular matrix and loss of mesothelial cells. We report a patient with liver cirrhosis in whom the diagnosis of EPS was made. During laparotomy for liver transplantation the complete peritoneum was found to be thickened, consisting of white sheets; liver transplantation was deferred. Histological examination showed peritoneal sclerosing fibrosis. Immunosuppressive medication was started and a difficult but successful liver transplantation followed. If EPS is diagnosed during laparotomy for organ transplantation, adjusted immunosuppression is preferred as calcineurin inhibitors such as cyclosporin and tacrolimus may accelerate EPS while prednisone and some other drugs may stop progression.

KEYWORDS

Immunosuppressive therapy, proliferation, TGF- β

INTRODUCTION

Encapsulating peritoneal sclerosis (EPS) is a rare cause of small bowel obstruction in which there is encapsulation of the small bowel by a fibrous membrane which can clinically result in obstruction. It occurs in a variety of clinical conditions.¹ We report a case of liver transplantation in a patient with EPS.

CASE REPORT

A 65-year-old male patient was diagnosed with liver cirrhosis associated with a heterozygote α_1 antitrypsin deficiency (α_1 AT Pi MZ). Liver biopsy showed macronodular cirrhosis with intracytoplasmatic periodic acid schiff (PAS)-positive globules (*figures 1 and 2*). After a variceal bleeding in 2000 he started taking propranolol 80 mg slow-release tablets. The diagnosis of spontaneous bacterial peritonitis (SBP) was never made. Because of progressive liver failure and fatigue, he was put on the waiting list for liver transplantation. In July 2006, a liver graft became available. During laparotomy the complete peritoneum and especially the peritoneum surrounding the liver and hepatoduodenal ligament were found to be thickened, consisting of white sheets as shown in *figure 3*. The results of frozen section biopsies were inconclusive. Since malignancy could not be excluded liver transplantation was deferred. The liver graft was transplanted successfully into another recipient. EPS was diagnosed on histological examination showing peritoneal sclerosing fibrosis (*figure 4*). Preoperative and postoperative computed tomography (CT) and ultrasound of the abdomen showed a small cirrhotic liver with portal hypertension and ascites, but no other abnormalities. In November 2006 we started prednisone, azathioprine and tamoxifen. Only seven days after starting this medical therapy a donor liver became available. During transplantation, no differences with respect to the thickened peritoneum were seen, compared with the first laparotomy. Due to extensive fibrosis an *en-bloc* resection of the liver and partial diaphragm took place with above average blood loss. After a prolonged postoperative period the patient could be discharged in a good condition. No cyclosporin or tacrolimus were given. His current medication consists of mycophenolate mofetil and prednisone.

Figure 1. Liver biopsy showing macronodular cirrhosis with intracytoplasmatic periodic acid schiff-positive globules (100 x)

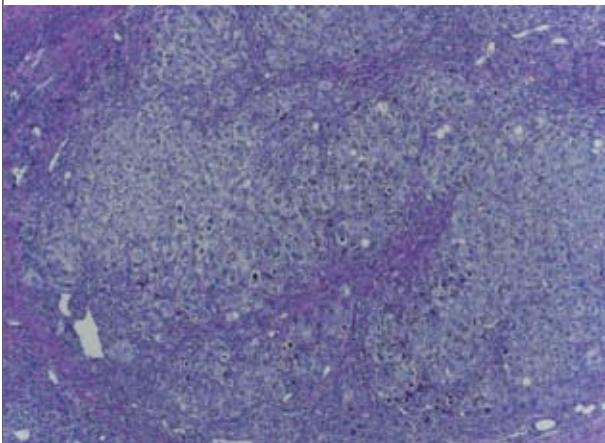


Figure 2. Liver biopsy showing numerous intracytoplasmatic periodic acid schiff-positive globules consistent with (partial) α_1 antitrypsin deficiency (400 x)

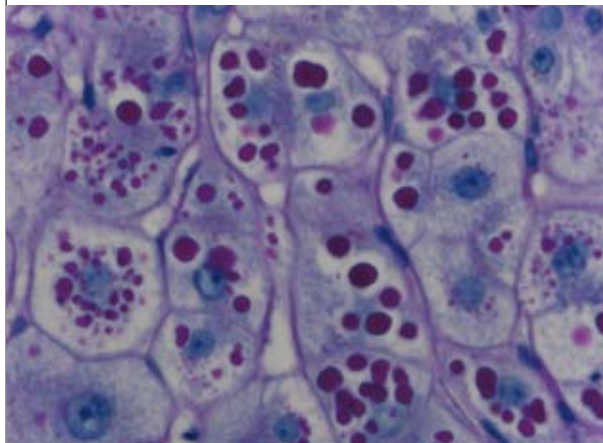
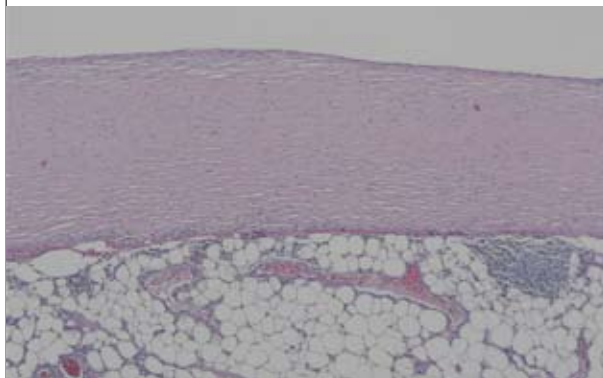


Figure 3. Thickened peritoneum found during laparotomy

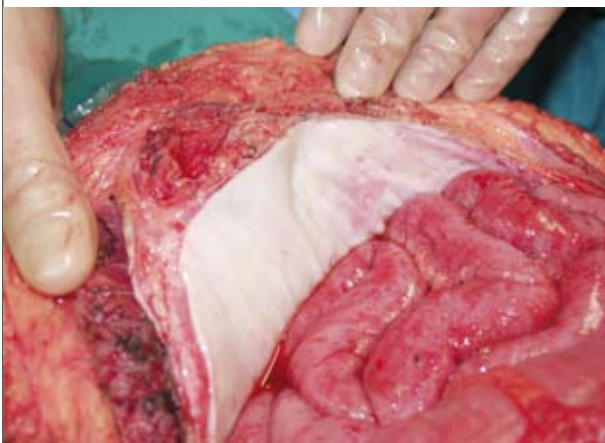

Figure 4. Thickened peritoneum with proliferation of fibroblasts, deposition of collagenous extracellular matrix and loss of mesothelial cells (Haematoxylin Eosin, 100 x)



DISCUSSION

EPS is a poorly understood condition in which excess fibrosis results in an encasement of the small bowel, which can clinically result in obstruction. The condition is thought to be related to the persistent expression of transforming growth factor beta (TGF- β) on mesothelial cells.^{2,3} Patients with EPS presenting with symptoms have signs of bowel obstruction including abdominal pain, anorexia, nausea and weight loss.¹ However, the condition does not generally cause symptoms, as in the present case. In our patient, this might be explained by the fact that the visceral peritoneum covering the gut was relatively spared from fibrosis. In the work-up for liver transplantation, EPS was not detected on radiological examinations including ultrasound and CT. In patients with EPS, abdominal ultrasound and CT may show increased peristalsis and small bowel dilatation as well as thickened adherent bowel loops.⁴ The histological changes consist of diffuse loss of

mesothelial cells, proliferation of subserosal fibroblasts and massive production of extracellular matrix (ECM).

EPS is described in the context of chronic ambulatory peritoneal dialysis (CAPD), recurrent peritonitis, the use of β -adrenergic blockers and ventriculoperitoneal shunting.^{2,3}

Prevalence estimates of EPS in CAPD patients range from 0.54 to 7.3%.¹ It is related to time on dialysis and may be related to the nonphysiological composition of dialysis solutions as well as the direct action of glucose and glucose degradation products.⁵

In patients with liver cirrhosis, EPS is extremely rare. There might be a relation to the occurrence of SBP. Recently two patients with liver cirrhosis and EPS after recurrent peritonitis were reported. In one of them, liver transplantation was halted because of EPS.⁶

In the late 1970s a relation between EPS and the use of practolol, a β -adrenergic blocker, was reported. Practolol was withdrawn after recognition of its toxic effects on skin, eyes, ears, peritoneum, and lungs.⁷ The exact pathogenesis remained unknown. A role for β -adrenergic blockers other than practolol in EPS is less likely considering that only a few cases have been reported.⁸

Ascites flow through a peritoneal venous shunt (PVS) and fibrin deposition in the peritoneum may lead to chronic inflammation and cause EPS in patients with liver cirrhosis. A recent case report described a patient who underwent PVS drainage for treating refractory ascites. During surgery for liver transplantation, EPS was diagnosed. Two weeks after liver transplantation emergency surgery was necessary for small bowel obstruction caused by EPS.⁹

The pathogenesis of EPS in the patient we describe here remains unknown. A relation with his underlying disease (α_1 AT Pi MZ) cannot be ruled out. On the other hand this is the first case of EPS reported in the many patients with α_1 antitrypsin deficiency who underwent liver transplantation. In the past, the diagnosis of SBP had not been made in our patient. One could speculate on a genetic predisposition, e.g. polymorphism of fibroblast activity, possibly triggered or aggravated by the long duration treatment with propranolol.

To our knowledge only one case report has described a patient with EPS not before but following liver transplantation. This patient had been on tacrolimus since the liver transplantation and presented with EPS nine months later.¹⁰ Calcineurin inhibitors such as cyclosporin and tacrolimus may activate TGF- β , induce fibrinogenesis and accelerate EPS. Therefore they should probably be avoided.¹¹

Several studies in CAPD patients with EPS describe the successful treatment with immunosuppressive therapy (i.e. prednisone and azathioprine).¹² Also, treatment with tamoxifen might be helpful.¹³ Tamoxifen has been successfully used in the treatment of retroperitoneal fibrosis. It may alter the balance of growth factors in such a way that fibroblast proliferation is inhibited. The exact mechanism is, however, not yet understood.¹⁴ Whether our patient benefited from the combined immunosuppressive therapy and tamoxifen started after the first laparotomy was not obvious during the second laparotomy for liver transplantation; however, treatment had started only one week before.

Based on 32 cases of surgically treated patients with EPS, recommendations were made when EPS is found during laparotomy. These included that if the membrane is easily cleavable, it should be removed as completely as possible; however when enterolysis is difficult, extreme caution

must be exercised not to perforate the intestine. If EPS is discovered as an incidental finding, surgical treatment is not indicated.¹⁵

CONCLUSION

EPS is a not well understood condition involving TGF- β , which does not generally cause symptoms. This may result in difficult decision-making at times of surgery as described in the present case. In asymptomatic patients, immunosuppressive therapy with prednisolone and azathioprine seems the treatment of choice. After liver transplantation an adjusted immunosuppressive regimen seems preferable.

REFERENCES

1. Kawaguchi Y, Kawanishi H, Mujais S, Topley N, Oreopoulos DG. Encapsulating peritoneal sclerosis: definition, etiology, diagnosis, and treatment. *Perit Dial Int* 2000;20(suppl 4):S43.
2. Dobbie JW. Pathogenesis of peritoneal fibrosis syndrome (sclerosing peritonitis) in peritoneal dialysis. *Perit Dial Int* 1992;12:14.
3. Roberts WA, McKune BK, Sporn MB. TGF-Beta: Regulation of extracellular matrix. *Kidney Int* 1992;41:557.
4. Perks FJ, Murchison JT, Gibson P, Jackson SHL. Imaging Findings in sclerosing encapsulating peritonitis. *J R Coll Physicians Edinb* 2004;34:116.
5. Summers AM, Clancy MJ, Syed F, et al. Single-center experience of encapsulating peritoneal sclerosis in patients on peritoneal dialysis for end-stage renal failure. *Kidney Int* 2005;68:2381-8.
6. Yamamoto S, Sato Y, Takeishi T, Kobayashi T, Hatekeyama K. Sclerosing encapsulating peritonitis in two patients with liver cirrhosis. *J Gastroenterol* 2004;39:172.
7. Brown P, Baddeley H, Read AE, Davies JD, McGarry J. Sclerosing peritonitis, an unusual reaction to a beta-adrenergic blocking drug (practolol). *Lancet* 1974;2:1477.
8. Clark CV, Terris R. Sclerosing peritonitis is associated with metoprolol. *Lancet* 1983;23:937.
9. Lin C-H, Yu JC, Chen TW, Chan DC, Chen CJ, Hsieh CB. Sclerosing encapsulating peritonitis in a liver transplant patient: A case report. *World J Gastroenterol* 2005;11:5412.
10. Abul S, Al-Oazweni H, Zalat S, SI-Sumait B, Asfar S. Cocoon Abdomen in a liver transplant patient. *JR Coll Edinb* 2002;47:579.
11. Maluccio M, Sharma V, Lagman M, et al. Tacrolimus enhances transforming growth factor-beta1 expression and promotes tumor progression. *Transplantation* 2003;76:597.
12. Kuriyama S, Tomonari H. Corticosteroid therapy in encapsulating peritoneal sclerosis. *Nephrol Dial Transplant*. 2001;16:1304.
13. Allaria PM, Giangrande A, Gandini E, Brambilla, Pisoni I. Continuous ambulatory peritoneal dialysis and sclerosing encapsulating peritonitis: Tamoxifen as a new therapeutic agent? *J Nephrol* 1999;12:395-7.
14. Van Bommel EF, Hendriksz TR, Huiskes AW, Zeegers AG. Brief communication: tamoxifen therapy for nonmalignant retroperitoneal fibrosis. *Ann Intern Med* 2006;144:101-6.
15. Celicout B, Levard H, Hay JM, Msika S, Fingerhut A, Pelissier E. Sclerosing encapsulating peritonitis: early and late results of surgical management in 32 cases. *Dig Surg* 1998;15:697.

Myomatous erythrocytosis syndrome: further proof for the pathogenic role of erythropoietin

L.T. Vlasveld^{1*}, C.W.M. de Wit², R.A. Verweij³, A. Castel⁴, P.M. Jansen⁵, A.A.W. Peters⁶

Departments of ¹Internal Medicine, ²Surgery, ³Gynaecology and Obstetrics, and ⁴Clinical Chemistry and Haematology, Bronovo Hospital, The Hague, the Netherlands, Departments of ⁵Pathology, and ⁶Gynaecology and Obstetrics, Leiden University Medical Center, Leiden, the Netherlands, *corresponding author: tel.: +31 (0)70-312 41 41, fax: +31 (0)70-326 27 06, e-mail: tomvlasveld@hotmail.com

ABSTRACT

Background: Myomatous erythrocytosis syndrome is defined by the combination of erythrocytosis, myomatous uterus and persistent restoration of normal haematological values after hysterectomy. A pathogenic role of erythropoietin is suggested by clinical and experimental data.

Case report: A postmenopausal patient is described with the classical clinical signs of the myomatous erythrocytosis syndrome. During hysterectomy we demonstrated a large gradient between the erythropoietin levels in the uterine vein and artery, providing direct evidence for *in vivo* erythropoietin production by the myomatous uterus.

Conclusion: While erythropoietin and its receptor are consecutively expressed in normal and myomatous uterine tissue, it is amazing that erythrocytosis occurs so rarely in such a frequent disorder as uterine myomatosis. We strongly advocate cytogenetic examination of the myomatous tissue of subsequent patients with this entity.

until 1968, when the presence of erythropoietin in an extract of a myomatous uterus was proposed by increased radioactive iron incorporation in a hypoxic polycythemic mouse model. Since then, the presence of erythropoietin has been demonstrated in tumour extracts by functional assays, and a variety of immunological and molecular techniques. Although the preoperative erythropoietin activity or levels were only occasionally absolutely increased, a decrease in the serum erythropoietin activity or level after hysterectomy was found in most, but not every patient. We present a case with the typical features of the myomatous erythrocytosis syndrome and provide further evidence for the pathogenic role of erythropoietin by demonstrating direct *in vivo* production of erythropoietin by the myomatous uterus.

CASE REPORT

KEYWORDS

erythrocytosis, erythropoietin, myoma, uterus

INTRODUCTION

The combination of erythrocytosis, myomatous uterus and persistent restoration of normal haematological values after hysterectomy is defined as the myomatous erythrocytosis syndrome.¹ Since the first description in 1953 more than 40 cases have been reported. Already in 1955, a causative role of erythropoietin produced by the myomatous uterus was hypothesised, but analytical problems hampered the demonstration of erythropoietin production in the tumour

A 45-year-old female was admitted because her haemoglobin (Hb) level had increased from 8.8 mmol/l (reference interval 7.4 to 10.1) to 10.8 mmol/l in five years. The relevant medical history revealed endometriosis of the left adnex treated by adnexectomy, mild uterine myoma and hypertension. For two years she had been taking tibolone because of climacterial symptoms. On physical examination her blood pressure was 140/90 mmHg. The patient was mildly obese (weight 74 kg, height 172 cm) with moderate hypertrichiosis. The spleen was not enlarged. Laboratory examination showed a haematocrit (Ht) 0.53 l/l (RI: 0.36 to 0.47), erythrocyte count 5.69 x 10⁶/l (RI: 3.9 to 5.6), while the platelet and leucocyte counts were normal. An extensive biochemical profile, including serum cobalamin and overnight dexamethasone

suppression test, was within the reference interval. The O₂ saturation of 97% (RI: 96 to 100), the pulmonary function tests and chest X-ray were normal. Abdominal ultrasound revealed normal-sized kidneys and spleen. The serum erythropoietin level was 8.9 pmol/l (RI: 4.5 to 19.6). The measured total erythrocyte volume was 1850 ml (24.6 ml/kg), which was 118% of the calculated volume of 1570 ml ($[1.06 \times \text{age}] + 822 \times \text{m}^2$ body surface area). Bone marrow examination showed mildly increased but otherwise normal erythropoiesis with normal megakaryopoiesis and myelopoiesis. At pelvic examination the gynaecologist noticed that the myomatous uterus had increased in size, despite the postmenopausal status. During the follow-up period the Hb level increased to 11.9 mmol/l and Ht to 0.57 l/l while the erythropoietin level increased to 17 pmol/l. Because the uterus also increased in size during this period of time, it was decided to perform a hysterectomy. During the operation samples were drawn from the uterine vein and artery. The erythropoietin level was 12.7 pmol/l in the uterine artery while the concentration was 40 pmol/l in the uterine vein. A 1235 gram uterus was removed with multiple myomas, the largest diameter being 8 cm. Sample suspensions of the myomatous tissue and normal endometrium were made by homogenising 4 mm³ tissue in 2 ml PBS using a Potter's homogeniser. The erythropoietin concentration in the supernatant of the homogenised myomatous tissue was 50 pmol/l while the concentration was <1.0 pmol/l in the supernatant of the normal myometrium. Immunohistochemical staining with monoclonal antibody against erythropoietin (Santa Cruz Biotechnology, Santa Cruz, CA, USA) showed the presence of erythropoietin in myomatous tissue cells (figure 1) while the staining was negative in the normal myometrium cells (figure 2). After hysterectomy the Hb and Ht persistently returned to normal values and the serum erythropoietin level decreased to 6.3 pmol/l.

DISCUSSION

In this patient all three diagnostic criteria of the myomatous erythrocytosis syndrome are met. This is to our knowledge the first case in which direct evidence is provided for *in vivo* production of erythropoietin by the myomatous uterus by the demonstration of an erythropoietin level gradient between the uterine vein and artery of 27.3 pmol/l with a ratio of 3.1. As others, we found increased production of erythropoietin in the myomatous tissue *in vitro* and the presence of erythropoietin in the myomatous tissue was confirmed by immunohistochemical staining. Based on these findings the pathogenic role of erythropoietin in the myomatous erythrocytosis syndrome is undoubted. Erythropoietin is primarily produced by cells of the renal cortex and stimulates growth and differentiation of the erythrocyte progenitor cells.² Recent studies indicate that both erythropoietin and erythropoietin receptor (Epo-R) are expressed on a great variety of tissues including the female reproductive organs. There is emerging evidence that in premenopausal women the cyclic expression of erythropoietin in normal endometrial cells is regulated by oestrogen and progesterone.^{3,4} During the female reproductive life cyclic formation of new blood vessels (angiogenesis) occurs in the normal uterus. Experimental data may indicate that an oestrogen-induced-erythropoietin-Epo-R signalling pathway stimulates angiogenesis.^{5,7} Uterine myoma affects 30% of reproductive women with an estimated incidence of 70 to 80% at the age of 50.⁸ The pathogenesis of uterine myoma is not fully elucidated. Myomata are oestrogen and progesterone hormone dependent and many cytokines and growth factors may foster myoma growth through paracrine and/or autocrine mechanisms.⁹ The causative role of erythropoietin and Epo-R in myoma and especially in the erythrocytosis myomatous syndrome is speculative. Erythropoietin and Epo-R are expressed

Figure 1. Immunohistochemical staining for erythropoietin in uterine myoma, erythropoietin is expressed in the myoma and the vascular endothelial cells (40 x)

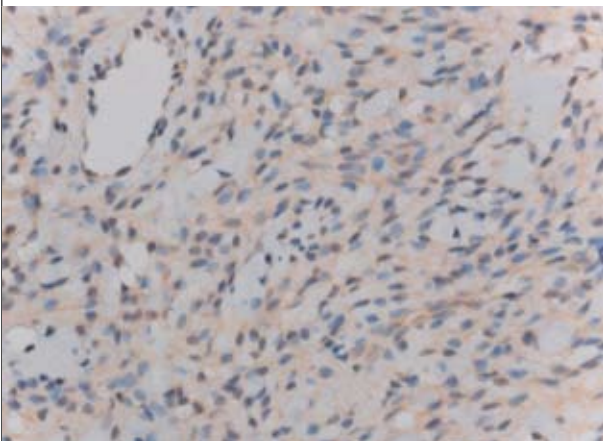
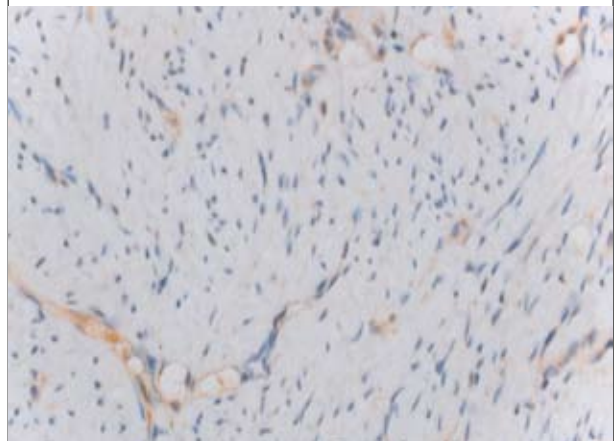


Figure 2. Adjacent normal myometrium, erythropoietin is not expressed in the normal myometrial cells, but is in the vascular endothelial cells (40 x)



in normal and myomatous tissue while in patients with the erythrocytosis myomatous syndrome the level of erythropoietin and/or Epo-R expression in the myoma is (strongly) elevated compared with myoma in patients without erythrocytosis and, as in our case, normal adjacent myometrium. It has been hypothesised that erythropoietin may contribute to myoma growth by stimulating angiogenesis. In the erythrocytosis myomatous syndrome the oestrogen-induced erythropoietin production may be further augmented by local hypoxia due to the rapid growing myomatous tissue, or by paracrine and/or autocrine mechanism.¹ However, theoretically the increased expression of erythropoietin and Epo-R may be explained alternatively. Despite the benign nature of uterine myomas chromosomal abnormalities can be demonstrated in up to 40 to 50% of the patients.¹⁰⁻¹² The aberrations are both nonrandom and tumour-specific and include t(12;14)(q15;q23-q24) and del(7)(q22.q32), while other rearrangements are less frequent. The 7q deletion, encompassing roughly band q22-q32 occurs frequently (17%) and is highly specific for myoma.¹²⁻¹⁴ The 7q22 band appears the critical region of rearrangement. An infrequent cytogenetic aberration in myoma are gains on chromosome 19 with the minimal region of overlap mapped to 19p13.3 and 19p13.1 or 19p13.2.¹⁵ Notably the gene encoding erythropoietin is located on 7q22 while the Epo-R gene is located on 19p13.3-p13.2 (www.ncbi.nih.gov). Gene profiling studies of genes involving the erythropoietin and Epo-R genes in uterine myoma are lacking and cytogenetic studies in patients with the myomatous erythrocytosis syndrome have not been performed. In view of the high incidence of uterine myoma and the consecutive expression of erythropoietin and/or Epo-R in normal and myomatous endometrium, it is amazing that the myomatous erythrocytosis syndrome occurs so infrequently. Further studies in subsequent patients are needed to clarify whether the increased production of erythropoietin is caused by a fortuitous local deregulation or by a unique cytogenetic aberration involving a specific region of the 7q22 and/or 19p13.3-p13.2 bands.

REFERENCES

1. Pollio F, Staibano S, Mansueto G, et al. Erythropoietin and erythropoietin receptor system in a large uterine myoma of a patient with myomatous erythrocytosis syndrome: possible relationship with the pathogenesis of unusual tumor size. *Hum Pathol* 2005;36:120-7.
2. Jelkmann W, Wagner K. Beneficial and ominous aspects of the pleiotropic action of erythropoietin. *Ann Hematol* 2004;83:673-86.
3. Matsuzaki S, Canis M, Yokomizo R, Yaegashi N, Bruhat MA, Okamura K. Expression of erythropoietin and erythropoietin receptor in peritoneal endometriosis. *Hum Reprod* 2003;18:152-6.
4. Yasuda Y, Masuda S, Chikuma M, Inoue K, Nagao M, Sasaki R. Estrogen-dependent production of erythropoietin in uterus and its implication in uterine angiogenesis. *J Biol Chem* 1998;273:25381-7.
5. Kertesz N, Wu J, Chen TH, Sucof HM, Wu H. The role of erythropoietin in regulating angiogenesis. *Dev Biol* 2004;276:101-10.
6. Chikuma M, Masuda S, Kobayashi T, Nagao M, Sasaki R. Tissue-specific regulation of erythropoietin production in the murine kidney, brain, and uterus. *Am J Physiol Endocrinol Metab* 2000;279:E1242-8.
7. Sasaki R, Masuda S, Nagao M. Erythropoietin: multiple physiological functions and regulation of biosynthesis. *Biosci Biotechnol Biochem* 2000;64:1775-93.
8. Arslan AA, Gold LI, Mittal K, et al. Gene expression studies provide clues to the pathogenesis of uterine leiomyoma: new evidence and a systematic review. *Hum Reprod* 2005;20:852-63.
9. Di Lieto A, de Falco M, Pollio F, et al. Clinical response, vascular change, and angiogenesis in gonadotropin-releasing hormone analogue-treated women with uterine myomas. *J Soc Gynecol Invest* 2005;12:123-8.
10. Sandberg AA. Updates on the cytogenetics and molecular genetics of bone and soft tissue tumors: leiomyoma. *Cancer Genet Cytogenet* 2005;158:1-26.
11. Ligon AH, Morton CC. Leiomyomata: heritability and cytogenetic studies. *Hum Reprod Update* 2001;7:8-14.
12. Vanharanta S, Wortham NC, Laiho P, et al. 7q Deletion mapping and expression profiling in uterine fibroids. *Oncogene* 2005;24:6545-54.
13. Xing YP, Powell WL, Morton CC. The del(7q) subgroup in uterine leiomyomata: genetic and biologic characteristics. *Cancer Genet Cytogenet* 1997;98:69-74.
14. Levy B, Mukherjee T, Hirschhorn K. Molecular cytogenetic analysis of uterine leiomyoma and leiomyosarcoma by comparative genomic hybridization. *Cancer Genet Cytogenet* 2000;121:1-8.
15. Packenham JP, du Manoir S, Schrock E, et al. Analysis of genetic alterations in uterine leiomyomas and leiomyosarcomas by comparative genomic hybridization. *Mol Carcinog* 1997;19:273-9.

Two rare complications of glioblastoma multiforme: persistent hiccup and acquired haemophilia A

C.M.P.G. van Durme¹, R.N. Idema², C. van Guldener^{1*}

Department of ¹Internal Medicine and ²Laboratory of Haematology and Clinical Chemistry, Amphibia Hospital, Breda, the Netherlands, *corresponding author: e-mail: cvguldener@amphia.nl

ABSTRACT

A 69-year-old man was admitted to the hospital with persistent hiccups. Computed tomography and magnetic resonance imaging of the brain were performed and revealed a glioblastoma multiforme localised in the right temporal lobe. After resection, the hiccups disappeared, suggesting that temporal areas are involved in control mechanisms of hiccups. A month later, the patient was readmitted because of skin, mucosal and soft tissue bleedings. Laboratory findings showed a prolonged aPTT, a low factor VIII activity and a factor VIII inhibitor, leading to the diagnosis of acquired haemophilia A. Acquired haemophilia A is a potentially life-threatening haemorrhagic disorder resulting from the presence of antibodies against factor VIII. We believe that this disorder developed due to exposure of factor VIII(-like) tumour antigens to the immune system. This case illustrates two yet unknown complications of a glioblastoma multiforme: persistent hiccups and acquired haemophilia A.

KEYWORDS

Glioblastoma, haemophilia, hiccups

INTRODUCTION

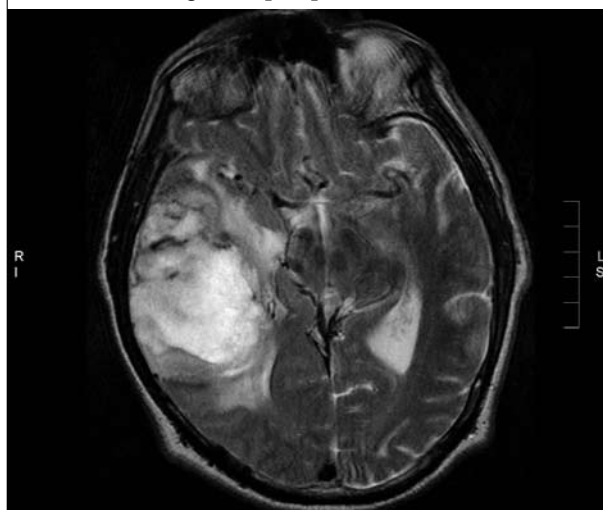
Hiccups are a common, benign and usually transient phenomenon that affects nearly everyone. Hiccups that continue for more than 48 hours are called persistent, and those lasting for more than two months are called intractable. Persistent or intractable hiccups may herald serious underlying disease. We report the case of a persistent hiccup, which was the first sign of a brain tumour. At follow-up, a second rare phenomenon of this

tumour presented in the form of acquired haemophilia with a severe haemorrhagic diathesis.

CASE REPORT

A previously healthy 69-year-old man was admitted with persistent hiccups for seven days, which had not responded to metoclopramide, diazepam and piracetam. At physical examination, there were no abnormalities. Laboratory tests were unremarkable and the chest radiograph was also without abnormalities. Baclofen was prescribed. During the first night, the patient developed a generalised seizure. Magnetic resonance imaging (MRI) of the brain showed a solitary tumour in the right temporal lobe, most likely a glioblastoma multiforme (*figure 1*). The tumour

Figure 1. MRI scan of the cerebrum showing a large tumour in the right temporoparietal lobe



was resected and histology confirmed the diagnosis of a glioblastoma multiforme. Postoperatively, the hiccups disappeared.

Four weeks after neurosurgery, the patient was re-admitted because of gross haematuria, melena, skin bleedings and a large retroperitoneal haematoma. Laboratory examination showed a haemoglobin of 3.8 mmol/l (normal >8.0 mmol/l), an elevated thrombocyte count ($513 \times 10^9/l$), a normal PT (12 s) and a prolonged APTT of 124 s (normal <32 s). The APTT of a 1+1 mixture of patient's plasma with pooled normal plasma (APTT 29 s) was prolonged (45 s) and increased markedly to 57 s after one hour of incubation at 37°C. Lupus anticoagulant was excluded by means of a dilute Russel Viper Venom Time (41.8 s, normal <42.9 s). Further evaluation showed a decreased factor VIII activity of 1.9% of normal. Dilution of the patient's plasma showed a linear decrease in factor VIII activity. Other coagulation factors were not measured. An unmodified Bethesda assay demonstrated a factor VIII inhibitor of 4 BU/ml, leading to the diagnosis of acquired haemophilia A.¹

Treatment was started with transfusion of packed cells, tranexaminic acid (500 mg three times/day) and DDAVP (24 µg twice daily). Postoperative dexamethasone therapy (2 mg twice daily) was switched to prednisone 75 mg/day. Because transfusion with three to four units of packed cells per day remained necessary to maintain the haemoglobin concentration above 5.0 mmol/l, 6000 units of porcine factor VIII concentrate were administered. This neither corrected the coagulation abnormalities (plasma factor VIII activity: 3.7%, APTT: 73 s and factor VIII inhibitor concentration: 1.8 BU/ml) nor terminated the ongoing blood loss. Then, recombinant factor VIIa was administered (bolus 90 µg/kg followed by 1.2 mg/hour) for one day. This resulted in cessation of the bleeding and discontinuation of the transfusions. Coagulation tests, however, remained abnormal. One week after the administration of recombinant factor VIIa, the APTT was 132 s, factor VIII activity 0.7% and factor VIII inhibitor concentration 5.0 BU/ml. Because of the persistence of the inhibitor, cyclophosphamide was started at 100 mg/day orally and the patient was discharged. At follow-up, there were no recurrent bleedings. Seven weeks after discharge, factor VIII activity remained low at 3.2%, but APTT had decreased to 49 s and factor VIII inhibitor to 1.6 BU/ml. Cyclophosphamide was discontinued and prednisone was tapered. Three weeks later, APTT was 38 s and factor VIII activity 22%. Ten weeks later, i.e. five months after discharge, APTT (29 s) and factor VIII (87%) had normalised. One year after surgery, the tumour reappeared. There were no accompanying bleeding complications and APTT (26 s) and factor VIII activity (118%) were normal at that moment.

DISCUSSION

In this case, two yet unreported phenomena were observed in a patient with a glioblastoma multiforme: persistent hiccups and acquired haemophilia A.

Hiccups are caused by contractions of the diaphragm, the scalenic and intercostals muscles, followed by abrupt closure of the glottis, which causes the typical sound. Hiccup is considered to be a primitive respiratory reflex with the phrenic or vagal nerves or the sympathetic ganglia as afferent pathways, and the phrenic, cervical, intercostal and the recurrent laryngeal nerves as efferent pathways. The central connection is unknown, but it is thought to involve the brainstem, the respiratory centre in the medulla, the reticular formation, the phrenic nerve nuclei and the hypothalamus. In addition, supratentorial areas may be involved in normal inhibition of the hiccup reflex. Stimulation or irritation of the afferent pathways controlling the diaphragm (usually hiatus hernia with reflux oesophagitis) are responsible for most cases of chronic hiccups.^{2,3}

Most cases of chronic hiccups due to disorders of the central nervous system are caused by brainstem lesions such as trauma, ischaemic stroke or compression by infection or tumour. The rare supratentorial lesions that have been associated with chronic hiccups, were all, as in our case, located in one of the temporal lobes.^{4,5} Our case therefore strengthens the suggestion that temporal areas are involved in control mechanisms of hiccups.

With an incidence of only 1.5 per 1 million persons per year,⁶ acquired haemophilia A is an uncommon but potentially life-threatening haemorrhagic disorder with an associated mortality between 8 and 22%.^{7,9} It results from the presence of IgG autoantibodies directed against clotting factor VIII. These antibodies are usually of low affinity (type II) and may permit measurable levels of factor VIII, as was the case in our patient. The titre of these antibodies does not linearly correlate with the inactivation of factor VIII and the clinical manifestations. High affinity (type I) antibodies more frequently develop in response to infusions of factor VIII in patients with congenital haemophilia A. For unknown reasons, patients with acquired haemophilia A are more likely to have a severe bleeding diathesis than patients with congenital haemophilia A with the same inhibitor level.¹⁰

In the majority of patients with acquired haemophilia A, there is no underlying disease.⁶⁻⁸ Autoimmune diseases (systemic lupus erythematosus, rheumatoid arthritis, Sjögren's syndrome) or malignancies (both solid and haematological) are found in 20 to 30% of cases. About 10% of the cases develop postpartum. In malignancy-associated acquired haemophilia A, there is no clear relationship between the type or extent of the tumour and the occurrence or severity of acquired haemophilia A.^{11,12}

Glioblastoma multiforme has not yet been reported in malignancy-associated haemophilia A. The pathogenesis of the factor VIII inhibitors in malignancy remains elusive. Tumours may contain factor VIII-like antigens, which are able to elicit an immune response. In our patient, the inhibitor occurred four weeks after neurosurgery and it can be speculated that the tumour indeed contained factor VIII-(like) antigens which activated the immune system after the blood-brain barrier was severed.

The treatment of acquired haemophilia A requires a two-pronged approach: treatment of bleeding and elimination of the inhibitor. Treatment options for the bleeding episodes in patients with a low titre of inhibitor (i.e. <5 BU/ml) are DDAVP or factor VIII concentrate. In patients with severe bleeding and an inhibitor titre of >5 BU/ml, treatment with factor VIII-bypassing agents such as activated prothrombin complex concentrate or recombinant factor VIIa is preferred. Recombinant factor VIIa seems to be very effective,¹³ as it was in our case. The fact that factor VIII was bypassed by this treatment explains that the bleeding stopped while APTT and factor VIII activity were still abnormal. Eradication of the inhibitor should immediately be attempted in every patient. Prednisolone at 1 mg/kg/day results in inhibitor elimination in approximately 30% of patients. Other agents that can be used include cyclophosphamide, azathioprine, ciclosporin A, rituximab and high-dose immunoglobulins.¹⁴ In our patient, two weeks of high-dose prednisone was not successful in removing the inhibitor, after which cyclophosphamide was added. Seven weeks later, the inhibitor started disappearing from the plasma.

CONCLUSION

This case report illustrates two uncommon complications of glioblastoma multiforme: persistent hiccups and acquired haemophilia A. The location of the tumour in the temporal lobe and the disappearance of hiccups after

removal of the tumour support earlier suggestions that the hiccup reflex is supratentorially controlled from this area. In addition, glioblastoma multiforme had not yet been described as the underlying disease of acquired haemophilia A. Interruption of the blood-brain barrier and exposition of tumour antigens to the immune system may explain its occurrence in the present case.

REFERENCES

1. Kasper CK, Aledort LM, Aronson D, et al. A more uniform measurement of factor VIII inhibitors. *Thromb Diath Haemorrh* 1975;34:869-72.
2. Lewis JH. Hiccups: causes and cures. *J Clin Gastroenterol* 1985;7:539-52.
3. Kolodzik PW, Eilers MA. Hiccups (singultus): review and approach to management. *Ann Emerg Med* 1991;20:565-73.
4. Jansen PH, Joosten EM, Vingerhoets HM. Persistent periodic hiccups following brain abscess: a case report. *J Neurol Neurosurg Psychiatry* 1990;53:83-4.
5. Marsot-Dupuch K, Bousson V, Cabane J, Tubiana JM. Intractable hiccups: the role of cerebral MR in cases without systemic cause. *Am J Neuroradiology* 1995;16:2093-100.
6. Collins PW, Hirsch S, Baglin TP, et al. Acquired hemophilia A in the United Kingdom: a 2-year national surveillance study by the United Kingdom Haemophilia Centre Doctors' Organisation. *Blood* 2007;109:1870-7.
7. Delgado J, Jimenez-Yuste V, Hernandez-Navarro F, Villar A. Acquired haemophilia: review and meta-analysis focused on therapy and prognostic factors. *Br J Haematol* 2003;121:21-35.
8. Green D, Lechner K. A survey of 215 non-hemophilic patients with inhibitors to factor VIII. *Thromb Haemost* 1981;45:200-3.
9. Hay CR, Negrier C, Ludlam C. The treatment of bleeding in acquired hemophilia with recombinant factor VIIa: a multicentre study. *Thromb Haemost* 1997;78:1463-7.
10. Lollar P. Pathogenic antibodies to coagulation factors. Part one: Factor VIII and factor IX. *J Thromb Haemost* 2004;2:1082-95.
11. Hauser I, Lechner K. Solid tumors and factor VIII antibodies. *Thromb Haemost* 1999;82:1005-7.
12. Sallah S, Wan JY. Inhibitors against factor VIII in patients with cancer. Analysis of 41 patients. *Cancer* 2001;91:1067-74.
13. Hay CR, Brown S, Collins PW, Keeling DM, Liesner R. The diagnosis and management of factor VIII and IX inhibitors: a guideline from the United Kingdom Haemophilia Centre Doctors Organisation. *Br J Haematol* 2006;133:591-605.
14. Biggs R, Austen DE, Denson KW, Borrett R, Rizza CR. The mode of action of antibodies which destroy factor VIII. II. Antibodies which give complex concentration graphs. *Br J Haematol* 1972;23:137-55.

Case reports: added value counts

J.P.H. Drenth

Associate editor of the *Netherlands Journal of Medicine*, Radboud University Nijmegen Medical Centre, Nijmegen, the Netherlands, e-mail: g.derksen@aig.umcn.nl

A case report is a powerful tool to disseminate information on unusual clinical syndromes, disease associations, unusual side effects to therapy, or response to treatment. Case reports continue to be a very popular section within the Journal. They are well read, and by nature they are easily accessible.¹

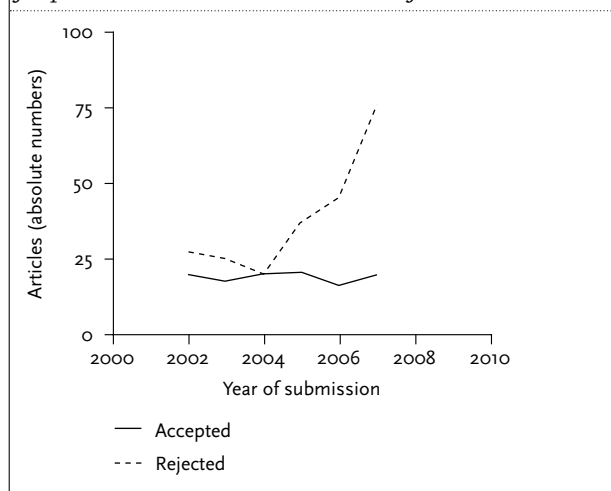
We think that case reports are a valuable asset to the Journal. We are not alone, since in some countries writing a case report is a prerequisite to pass the board examination as a medical professional. Examinees must write a case report and be able to answer relevant questions about the case and review of the literature in general.² Also, some medical societies require a written case report as a token of professionalism to become member.

Among the many reasons that explain the popularity of case reports, the main one is probably the accessible nature of this particular piece of clinical information. A good case report seamlessly fits with the clinical thinking needed in the ward and outpatient clinic. What clinical practice has in common with a written case report is that the same steps in clinical thinking are taken.

Symbol of the high popularity in the Journal is the continuous rise in the number of case report submissions (*figure 1*). The journal has always witnessed a steady stream of case reports, but over the last years the number has increased significantly. Last year we received 137 case reports and this represented a threefold increase in comparison with 2002.

What happens with the case report once you submit it? First, the Editorial Office checks whether the manuscript meets the administrative standards and that it is complete. If so, your manuscript moves to the next stage, and that is the editorial board meeting. Here we discuss your paper and judge whether it meets the standard of the Journal. This is a major hurdle, and we have to admit that not many manuscripts get beyond this stage. Next, we send your paper out for review, and after receipt of the referee reports, one of the editorial board members issues a

Figure 1. The number of manuscripts that are submitted as a case report to the *Netherlands Journal of Medicine* divided into manuscripts that were accepted for publication and those that were rejected



recommendation. The Editorial Board discusses the paper again, in view of the recommendation. If we agree that the case report is potentially interesting, we ask you to write a rebuttal and change the manuscript according to the issues raised by the reviewer. Now we have come to the last stage, and here the editorial board member checks whether the referee's issues have been dealt with. If there is any doubt at this stage, the paper can be rejected or we get back to you with additional questions. Finally, if you manage to get beyond this stage, your paper is accepted in the Journal and you can await publication.

Why do many case reports not get that far? As you may have noticed, we only publish two to three case reports each month and with eleven Journal issues, it becomes clear that we cannot print all submissions. Indeed, we rejected 74.6% of case report submissions last year.

How do we decide what to take or not to take? We, as Editorial Board, are committed to the Journal and we need to apply strict quality control measures in order to maintain

the high standard of the journal. Two years ago we wrote about the type of case reports that the Journal would like to receive and we issued guidelines on how to prepare a good case report.¹ At that time we hoped that the *Netherlands Journal of Medicine* would be the author's first choice for publishing their case reports. Well, that has happened in view of the vigorous rise in the number of submissions, but unfortunately, quality sorely fails to parallel quantity.

Indeed, we have noticed that many case reports appear to be hastily prepared, and casually submitted. Even with high profile clinicians as co-authors sloppy manuscripts with obvious textual mistakes are submitted, which leads us to doubt whether these authors actually proofread the manuscript. Often, the figures are of poor quality and more than once we have seen radiological figures which contain complete identification information of the patient. Needless to say, it is your responsibility to protect the confidentiality and anonymity of the patient. Ideally all visual supplements should be compact, self-contained, and instructive. If you want your paper to stand out, pay attention here, and offer us more than a direct low-resolution copy from the electronic medical file. We would prefer one high-resolution figure consisting of several panels, instead of five different radiological pictures.

Now back to the content. We have outlined in the past which types of case reports the Journal desires. Often, we are left in the dark as to why a certain case report warrants publication. We realise that many authors want or even need their publication to build a resume, but we want to urge you to be very selective as to which case you select to write up. The wards are littered with potential case reports and although there might be something novel for you, ask yourself if it is also novel for the more experienced clinician? To be honest, most case reports we receive just fail to meet standard criteria such as novelty, insightfulness and impact.

We want to publish case reports that, broadly speaking, discuss new aspects of clinical presentation, diagnosis or treatment. We always ask ourselves the following question: will publication significantly advance our understanding of a particular disease aetiology or drug mechanism? If not, your case report stands a poor chance given the intense

competition it faces. Again, we would like to draw the attention of the potential authors to the Journal's guidelines for case reports, as it sometimes seems that they have been missed.

In order to remind authors of the standards we want to apply, we want to introduce a new item which you will see from the next issue of the Journal onwards. Authors will be required to answer two specific questions about their case report, see table 1 for an example on this special report.

Table 1. *Maintaining the standard of the Netherlands Journal of Medicine, by answering two specific questions about the case report*

Question	Answer (on this special report)
What was known on this topic (prior to preparing this case)?	Case reports are valuable tools for clinical learning, difficult to publish, mostly lack a message and poorly written
What does this case add?	Advice to improve quality for case reports and introduction of two questions that need to be answered

We will implement these changes as we want authors to rethink the much abused claim of novelty, and to help you to really highlight the essentials from your case.

The *Netherlands Journal of Medicine* is one of the few clinical journals that still considers case reports. For authors the advantages to publish with us are manifold. The Journal has open access, is well read and cited and we do not charge a publication fee.³ We want to offer you the best, so read our guidelines, answer the two questions, and submit to us your very best case reports.

REFERENCES

1. Drenth JP, Smits P, Thien T, Stalenhoef AF. The case for case reports in the Netherlands Journal of Medicine. *Neth J Med* 2006;64:262-4.
2. <http://www.aaopt.org/becoming/reportguide/index.asp>.
3. Drenth JP. The Netherlands Journal of Medicine's hitlist: which 2004 paper was best cited? *Neth J Med* 2006;64:393-4.

The Netherlands Journal of Medicine: 1998-2002, what came out of it?

A.I.M. Hoepelman

Department of Internal Medicine and Infectious Diseases, University Medical Center Utrecht,
the Netherlands, e-mail: i.m.hoepelman@umcutrecht.nl

When I took over as the seventh Editor-in-Chief in 1998, the Journal was in good shape. The Journal received about 110 articles yearly, 20% from abroad, its impact factor had risen substantially and took the 45th place in the ranking of journals in medicine. Moreover, it was available to more than 2000 subscribers in all continents.

However, the editors wanted more. In the decade of mergers, the internet and the Euro, the editorial board, in close collaboration with the Netherlands Association of Internal Medicine (NIV), started to look at ways to intensify cooperation with European journals with the same scope. Firstly, with the help of Elsevier, the Journal was made available electronically. Immediately, between 500 and 700 articles were downloaded monthly, adding up to more than 20,000 at the end of our term in December 2001.¹

What should the future direction be? In our vision we could go in two directions:

- Going more global and improving the scientific content in a way that we would translate the findings from 'subspecialties' in the context of the impact of general medical practice or
- Stay in line with the statement of the first Editor-in-Chief, Professor G.A. Lindeboom, in 1958 and act as 'a forum for Dutch internists and stimulate young doctors to write their first publication'.

This was a profound and difficult decision to make. The opinions among Dutch internists varied. It appeared that most Dutch internists wanted the best of both worlds: a high impact journal in which young doctors could write their first publications. In our opinion these ambitions were hard to combine but we certainly had to reconsider our European plans.

Moreover, in accordance with a well-known Dutch tradition, the costs of the journal were a topic at every annual convention of the NIV, many finding the Journal too expensive.

By the end 2001 it was finally decided that the journal would leave the scientific publisher Elsevier and move to the commercial publisher Van Zuiden Communications.

In our opinion this was choosing for the second option and consequently the decision had great impact. Firstly, the availability in medical libraries throughout the world was not anchored. Moreover, the journal was no longer available electronically. Together this influenced the impact factor which decreased from 0.93 in 2001 to 0.57 in 2003. Despite these turbulent times we thoroughly enjoyed our Editorship. We all had a very good time and each of us (*figure 1*) remembers the exciting discussions we had at the Tuesday afternoon editorial board meetings. Every aspect of an important journal such as fraud, disagreement with the readership and excitement about high-quality contributions passed our desks. It was with sadness and, given the uncertain future, with concern that at the end of our term we looked for a new Editorial team. Finding Professor J.W.M. van de Meer willing to guide the journal into a new future was a great relief. As stated in our editorial in December 2001,¹ we were sure we had left the Journal in good hands.

REFERENCE

1. Hoepelman IM. The Netherlands Journal of Medicine: end of a fruitful period and a new start. *Neth J Med* 2001;59:267-9.

Figure 1. A.I.M. Hoepelman, C.A. Gaillard, G.H. Blijham and J.B. Hoekstra



Treatment of chronic hepatitis B virus infection – Dutch national guidelines

E.H.C.J. Buster¹, K.J. van Erpecum², S.W. Schalm¹, H.L. Zaaijer³, J.T. Brouwer⁴, H.C. Gelderblom⁵, R.J. de Knecht¹, C. Minke Bakker⁶, H.W. Reesink⁵, H.L.A. Janssen^{1*}, for the Netherlands Association of Gastroenterologists and Hepatologists

¹Department of Gastroenterology and Hepatology, Erasmus MC, University Medical Centre Rotterdam, the Netherlands, ²Department of Gastroenterology and Hepatology, University Medical Centre Utrecht, the Netherlands, Departments of ³Virology, and ⁵Gastroenterology and Hepatology, Academic Medical Centre Amsterdam, the Netherlands, ⁴Department of Internal Medicine, Gastroenterology and Hepatology, Reinier de Graaf Group, Delft, the Netherlands, ⁶Department of Gastroenterology and Hepatology, Atrium Medical Centre, Heerlen, the Netherlands, *corresponding author: e-mail: h.janssen@erasmusmc.nl

ABSTRACT

The development of this guideline was initiated and coordinated by the Netherlands Association of Gastroenterologists and Hepatologists (Nederlandse Vereniging van Maag-Darm-Leverartsen). The aim is the establishment of national standards in the evaluation and antiviral treatment of patients with chronic hepatitis B virus (HBV) infection. This includes recommendations on the initial evaluation of patients, choice and duration of antiviral therapy, follow-up after antiviral therapy and monitoring of patients not currently requiring antiviral therapy.

The initial evaluation of chronic HBV-infected patients should include testing of liver biochemistry, virus serology and abdominal imaging. In patients without cirrhosis, antiviral treatment is recommended for those with a serum HBV DNA of at least 1.0×10^5 c/ml ($\geq 2.0 \times 10^4$ IU/ml) in combination with: a) elevation of serum alanine aminotransferase (ALAT) level above twice the upper limit of normal during at least three months, and/or b) histological evidence of porto-portal septa or interface hepatitis on liver histology. In patients with cirrhosis, antiviral treatment is recommended if serum HBV DNA is 1.0×10^4 c/ml ($\geq 2.0 \times 10^3$ IU/ml) or higher, independent of ALAT levels or histological findings. If the patient has decompensated cirrhosis, antiviral treatment is recommended if serum HBV DNA is 1000 c/ml (≥ 200 IU/ml) or higher.

Patients who do not have an indication for antiviral treatment should be monitored because there is a risk of (re)activation of disease activity. Monitoring every three to six months is recommended for HBeAg-positive and HBeAg-negative

patients with high viraemia (HBV DNA $\geq 1.0 \times 10^5$ c/ml or $\geq 2.0 \times 10^4$ IU/ml) and normal ALAT levels. For patients with serum HBV DNA below 1.0×10^5 c/ml ($< 2.0 \times 10^4$ IU/ml) the recommended frequency of monitoring is every three to six months for HBeAg-positive patients and every six to 12 months for HBeAg-negative patients.

Peginterferon (PEG-IFN) therapy should be considered as initial therapy in both HBeAg-positive and HBeAg-negative patients without contraindications for treatment with this drug because of the higher chance of achieving sustained response compared with nucleos(t)ide analogue therapy. In patients starting nucleos(t)ide analogue therapy, the use of lamivudine is not preferred if long-term antiviral treatment is expected due to the high risk of antiviral resistance against this drug. Of the currently licensed nucleos(t)ide analogues, entecavir has the lowest risk of antiviral resistance (compared with lamivudine, adefovir and telbivudine), while suppression of viral replication seems most profound with either entecavir or telbivudine. The recommended duration of treatment with PEG-IFN is one year for both HBeAg-positive and HBeAg-negative patients. In HBeAg-positive patients, nucleos(t)ide analogue therapy should at least be continued until HBeAg seroconversion and a decline in HBV DNA to below 400 c/ml (80 IU/ml) has been achieved and maintained for six months during therapy. Whether nucleos(t)ide analogue therapy can be safely discontinued in HBeAg-negative patients is unknown; usually prolonged or indefinite antiviral treatment is necessary.

Patients receiving PEG-IFN should be monitored once a month, while three monthly monitoring suffices for those receiving nucleos(t)ide analogues. Genotypic analysis of the HBV polymerase is indicated if an increase in serum HBV DNA of at least 1 log₁₀ c/ml (IU/ml) compared with the nadir value is observed during nucleos(t)ide analogue therapy. Antiviral therapy should be changed as soon as possible in case of confirmed genotypic resistance. Adding a second antiviral agent seems beneficial over switching to another agent.

With the availability of multiple new antiviral drugs for the treatment of chronic hepatitis B, effective treatment is now possible for more patients and for longer periods. However, the complexity of HBV therapy has also increased. Nowadays, virtually all chronic HBV-infected patients can be effectively managed, either by inducing sustained off-treatment response or by maintaining an on-treatment response.

INTRODUCTION

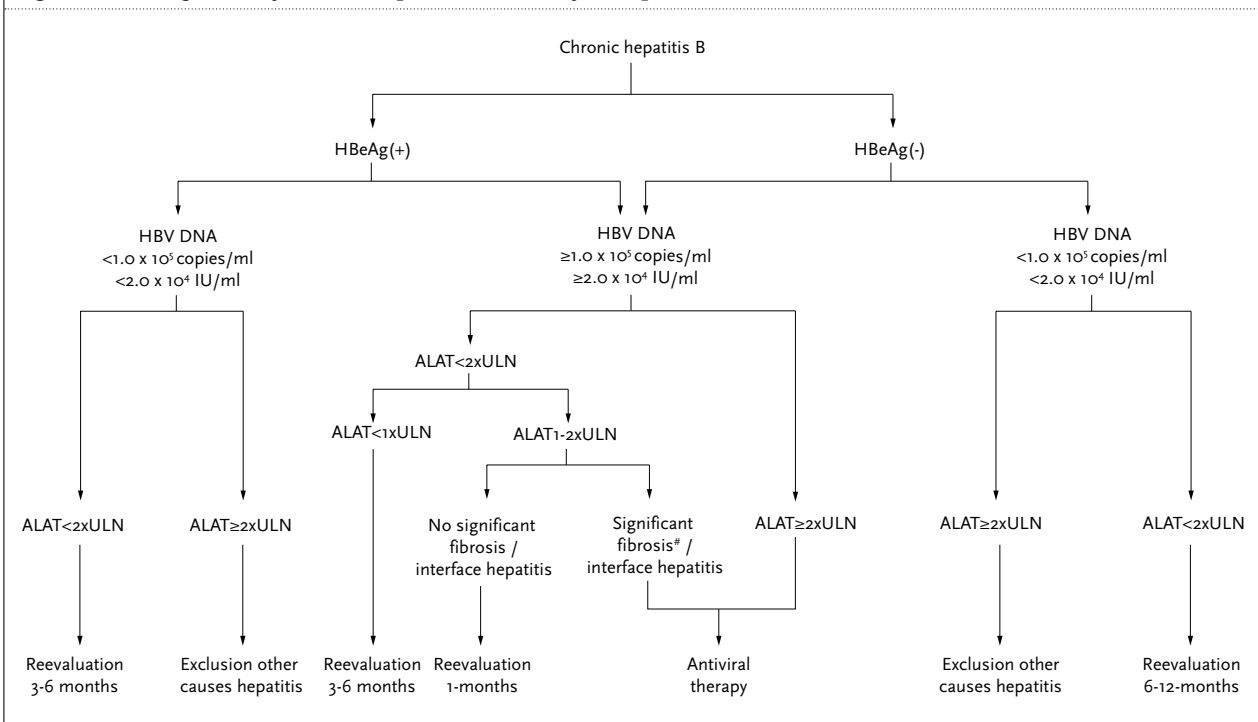
About one-third of the world's population has evidence of HBV infection and chronic hepatitis B affects about 400 million people worldwide.^{1,2} More than 500,000 people die yearly of HBV-related liver disease, largely due to complication of cirrhosis or hepatocellular carcinoma.³ The Netherlands is a low endemic country for HBV infection, the estimated seroprevalence of HBsAg and anti-HBc is

about 0.2% and 2.1%, respectively.⁴ Risk groups with a higher prevalence of HBV infection include immigrants from areas with intermediate or high prevalence of HBV infection, males who have sex with males and people with multiple sexual contacts. Despite the availability of a safe and effective vaccine for over 20 years now, HBV infection remains an important health problem. Antiviral treatment of chronic hepatitis B has dramatically changed over the last decade; with the availability of multiple new antiviral agents the treatment of chronic HBV infection has become more effective, but more complex as well.

Multiple consensus guidelines for the treatment of chronic hepatitis B have been published in the last few years.^{3,5,6} However, there is currently no standard of care for the management and antiviral treatment of chronic HBV-infected patients in the Netherlands. Therefore, a committee was convened by the Netherlands Association of Gastroenterologists and Hepatologists (Nederlandse Vereniging van Maag-Darm-Leverartsen) to formulate consensus-based guidelines for the management and treatment of chronic HBV-infected adults (*figure 1*).

The guideline provides recommendations on the initial evaluation of chronic HBV-infected patients, choice of (initial) antiviral therapy, follow-up during and after antiviral therapy and monitoring of patients currently not requiring antiviral therapy. Management of patients with coinfections of HBV and hepatitis C virus (HCV), hepatitis delta virus (HDV) or human

Figure 1. Management of chronic hepatitis B virus infected patients



This flowchart shows the recommendations on the management of chronic HBV-infected patients based on HBeAg status, serum HBV DNA and ALAT levels. # Significant fibrosis: at least porto-portal septa on liver histology. ULN = upper limit of normal.

immunodeficiency virus (HIV) is not discussed in this guideline. The recommendations in this guideline have been defined in accordance with recent international literature, data presented at international symposia and guidelines of the American Association for the Study of Liver Diseases (AASLD), the European Association for the Study of the Liver (EASL) and the Asian-Pacific Association for the Study of the Liver (APASL).^{3,5,6} The level of recommendation was performed according to the Dutch Institute for Healthcare Improvement (CBO) (http://www.cbo.nl/product/richtlijnen/handleiding_ebro/article20060207153532) (tables 1A and 1B).

Table 1A. Quality of studies on which a recommendation is based

Grade	Definition
A1	Systematic review of at least two independent studies of A2 level
A2	Randomised double-blind controlled study of adequate quality and size
B	Comparative study not fulfilling the characteristics of A2 level studies (including case-control studies and cohort studies)
C	Noncomparative studies
D	Expert opinion

Table 1B. Quality of evidence on which a recommendation is based

Grade	Definition
I	Study of level A1 or at least two independent studies of level A2
II	Single level A2 study or at least two independent level B studies
III	Single level B or C study
IV	Expert opinion

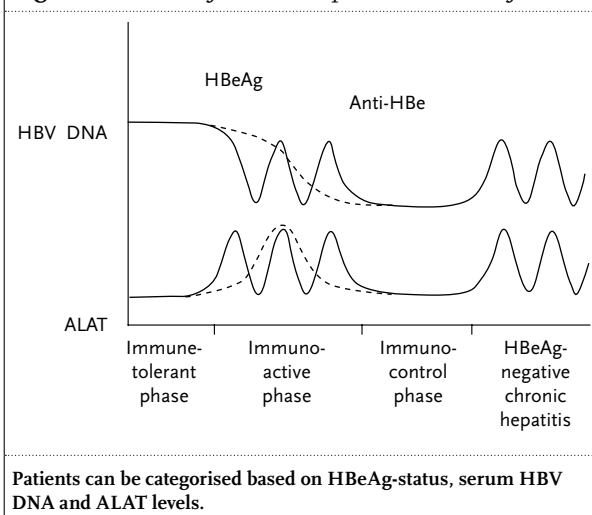
NATURAL HISTORY

Infection with HBV in adulthood is usually not associated with symptomatic disease and results in chronic infection in less than 5% of cases.³ However, infection during childhood is associated with a much higher risk of chronicity, up to 90% in case of perinatal transmission.³ Chronic HBV infection is defined as detectable hepatitis B surface antigen (HBsAg) in serum for at least six months.

Phases of infection

Chronic HBV-infected patients typically present in one of four phases of infection (figure 2).⁷ In the immunotolerant phase, hepatitis B e antigen (HBeAg) is detectable and serum HBV DNA is high ($>1.0 \times 10^5$ c/ml or $>2.0 \times 10^4$ IU/ml), while serum alanine aminotransferase (ALAT) is normal. Patients infected in early childhood usually

Figure 2. Phases of chronic hepatitis B virus infection



remain in this phase of infection for 10 to 30 years.⁸ In the immunoactive phase, an active host's immune response against the virus results in a rise in ALAT accompanied by a decline in HBV DNA; loss of HBeAg with seroconversion to anti-HBe can occur. The immune control phase follows HBeAg seroconversion and is characterised by low viraemia ($<1.0 \times 10^4$ c/ml or $<2.0 \times 10^3$ IU/ml) and normalisation of ALAT. Although HBV replication persists, it is profoundly suppressed by an active immune response. In a significant proportion of HBeAg-negative patients, viral replication and hepatic inflammation persist or recur, usually due to the selection of HBV variants with mutation in the HBV genome (precore or core promoter mutants) which hamper the production of HBeAg. These patients develop HBeAg-negative chronic hepatitis. Patients with chronic hepatitis B who acquire infection in adulthood often skip the immunotolerant phase and enter the immuno-active phase shortly after the infection.

Reactivation of HBV infection can occur in case of immunosuppression; it is therefore recommended to determine HBV status in all patients prior to the start of chemotherapy or treatment with selective antibodies.

Cirrhosis

The annual incidence of cirrhosis in patients with chronic hepatitis B is about 6%, with a five-year cumulative incidence of 20%.⁹ The course of the disease strongly varies among individual patients; progression of liver damage particularly occurs in those with persistent hepatic inflammation.¹⁰ Factors associated with an increased risk of developing liver cirrhosis include high serum HBV DNA, coinfection with HCV, HDV or HIV, repeated episodes of acute exacerbation and severe necroinflammation at diagnosis.^{3,11,12} The annual risk of hepatic decompensation is about 3% in patients with pre-existent cirrhosis.³

Presence of liver cirrhosis is associated with a diminished five-year survival rate of about 84%, for patients with decompensated cirrhosis this is only 14 to 30%.¹³⁻¹⁵

Hepatocellular carcinoma

Cirrhosis is a major risk factor for the development of hepatocellular carcinoma (HCC), the majority of patients with HCC have underlying cirrhosis (80 to 90%).¹⁶ The annual incidence of HCC in European chronic hepatitis B patients is about 2%. In patients from Asia, the risk of developing HCC is higher, with an annual incidence of about 3%.¹⁶ Factors associated with an increased risk of developing HCC in patients with cirrhosis include high age, male sex, persistent hepatic inflammation, HBV DNA $>1.0 \times 10^4$ c/ml ($>2.0 \times 10^3$ IU/ml), HBeAg positivity, coinfection with HCV or HIV, and alcohol abuse.¹⁶⁻¹⁹

INITIAL EVALUATION

The initial evaluation of patients with chronic HBV infection should include a detailed history, with special emphasis on risk factors for infection with blood-borne viruses and sexual transmitted diseases, alcohol use, and family history of HBV infection and liver cancer. Physical examination should focus on signs of chronic liver disease and cirrhosis (palmar erythema, spider nevi, gynaecomasty, flapping tremor and testicular atrophy), portal hypertension (ascites, splenomegaly and abdominal wall collaterals) and liver failure (jaundice and hepatic encephalopathy).

Laboratory tests should include assessment of liver enzymes (aminotransferases), liver function tests (albumin, bilirubin and prothrombin time), full blood count and kidney function tests. Virus serology should include markers of HBV replication (quantification of HBV DNA, HBeAg and anti-HBe) and in patients at increased risk, also tests for coinfection with HCV, HDV, or HIV. Determination of HBV genotype may be of use in patients starting antiviral therapy, as this may guide the choice of therapy.

Abdominal ultrasound should be performed in all patients, with special emphasis on signs of cirrhosis (irregular liver surface, blunt liver edge and narrowed hepatic veins), portal hypertension (diminished portal flow speed, splenomegaly, venous collaterals and ascites) and focal liver lesions.

Performing a liver biopsy is often indicated, but does not have to be routinely performed in all chronic HBV-infected patients. A liver biopsy should particularly be considered in patients with an indication for antiviral therapy in order to assess baseline necroinflammatory activity and fibrosis stage. If there is any doubt about the need for starting antiviral therapy, liver biopsy is probably of even greater value as it may give additional information on whether antiviral therapy or a conservative approach is justified. For patients in the immune-control phase (inactive

HBsAg carrier state) a liver biopsy should be considered if cirrhosis is suspected. Patients in the immune control and HBeAg-negative hepatitis phase are usually older, have been infected with HBV longer and more often develop advanced fibrosis or cirrhosis as compared with patients in other phases of infection.²⁰ If liver histology shows the presence of cirrhosis it is not recommended to discharge the patient because of the risk of HCC developing in these patients, even in patients with inactive disease. Patients in the immunotolerant phase, on the other hand, rarely have significant fibrosis and progression of disease should only be suspected in case of transition to the immunoactive phase.²¹ Performing a liver biopsy can therefore usually be postponed in such cases.

Surveillance for HCC, by abdominal ultrasound every six to 12 months, is recommended for all chronic HBV-infected patients with cirrhosis, in particular in those at increased risk of developing HCC.^{6,22} Patients at increased risk of developing HCC include Asian males over 40 years, Asian females over 50 years, patients with a family history of HCC, Africans over 20 years, patients with high HBV DNA levels and those with persistent hepatic inflammation.²³ Also in patients without cirrhosis but with an increased risk of developing HCC, surveillance for HCC should be considered. Surveillance for HCC results in detection of HCC at an earlier stage and thereby improved survival.²⁴ Routine measurement of α -fetoprotein is in general not useful as this does not improve the efficacy of screening and leads to an increase in false-positive findings.²³ In patients with cirrhosis, upper gastrointestinal endoscopy should be considered to confirm or exclude the presence of oesophageal varices.²⁵

Hepatitis A virus (HAV) immunity should be established in all patients with chronic hepatitis B, since the risk of a fulminant course of acute HAV infection is increased compared with healthy controls.^{26,27} Despite the fact that the actual risk of fulminant HAV is low, HAV vaccine is recommended for all chronic HBV-infected patients not immune to HAV.

Recommendations	
The initial evaluation of chronic HBV-infected patients should include a detailed history and physical examination. Blood chemistry, full blood count, virus serology, including quantification of serum HBV DNA, and abdominal ultrasound should be performed. Performing a liver biopsy should particularly be considered in case of active hepatitis and if there is any doubt about the need for starting antiviral therapy.	Level 4
Surveillance for hepatocellular carcinoma by abdominal ultrasound every 6 to 12 months is recommended in patients with cirrhosis.	Level 3
Hepatitis A vaccination is recommended in all chronic hepatitis B patients without immunity against the hepatitis A virus because of the increased risk of developing fulminant acute hepatitis A compared with healthy controls.	Level 1

INDICATIONS FOR ANTIVIRAL THERAPY

In a considerable proportion of chronic HBV-infected patients there is no need for antiviral treatment.²⁸ Whether or not antiviral treatment should be started depends on multiple factors (table 2). First, active viral replication should be present, as shown by serum HBV DNA of at least 1.0×10^5 c/ml (2.0×10^4 IU/ml). In HBeAg-negative patients, the risk of (re)activation of disease activity and progression of disease seems to be already increased in those with serum HBV DNA above 1.0×10^4 c/ml (2.0×10^3 IU/ml) compared with patients with lower HBV DNA levels.²⁹ In addition to HBV DNA, the degree of hepatic fibrosis and inflammation plays an important role in assessing the need for antiviral therapy. This is represented by serum ALAT levels and necroinflammatory activity on liver histology. Serum ALAT of at least two times the upper limit of normal (ULN) for a period of three to six months is usually considered an indication for antiviral therapy. In patients with serum HBV DNA above 1.0×10^5 c/ml (2.0×10^4 IU/ml) and persistent mild hepatic inflammation (ALAT 1 to 2 x ULN), but with significant liver fibrosis (porto-portal septa) or interface hepatitis, antiviral therapy should also be considered. If serum ALAT is elevated but serum HBV DNA is low, other causes of hepatitis should be considered. If no other underlying aetiology can be found and liver biopsy shows hepatitis B virus associated inflammation, antiviral treatment should be considered. In patients with compensated cirrhosis, antiviral treatment should be considered if HBV DNA is 1.0×10^4 c/ml (2.0×10^3 IU/ml) or higher. HBV DNA above this level

is associated with an increased risk of progression to decompensated cirrhosis or HCC.¹⁷ Patients with decompensated cirrhosis should be offered antiviral therapy if HBV DNA is 1000 c/ml (200 IU/ml) or higher, as suppression of viral replication can significantly improve liver function and survival in these patients.^{30,31}

Over 90% of babies born to HBsAg-positive mothers are effectively protected by passive-active immunisation. However, in pregnant patients with very high viraemia (HBV DNA $\geq 1.0 \times 10^9$ c/ml or $\geq 2.0 \times 10^8$ IU/ml), the risk of vaccination failure in the newborn is about 30%.^{32,33} In these women, nucleos(t)ide analogue therapy from week 32 of pregnancy can significantly lower this risk.^{33,34} Lamivudine is the antiviral agent of choice because of extensive clinical experience in pregnancy, particularly in HIV infection.^{33,35} Switching to another antiviral agent after delivery can be considered if prolongation of antiviral therapy is indicated. In patients becoming pregnant during nucleos(t)ide analogue therapy, the risks of stopping antiviral therapy (in particular acute exacerbation) should be balanced against the risk for the unborn child when continuing the drug. Recommendations on what to do in such cases are not possible as scientific evidence is lacking; consulting a centre with expertise on treatment of chronic HBV infection is recommended.

In HBsAg-positive patients starting chemotherapy or treatment with selective antibodies, prophylactic antiviral treatment with a nucleos(t)ide analogue is recommended until six months after the completion of the immunosuppressive therapy. Prophylactic antiviral therapy has been shown to significantly reduce the risk of reactivation and hepatitis B-related death.^{6,36} In patients requiring prophylactic antiviral treatment, who have baseline HBV

Table 2. Recommendations of management of chronic hepatitis B based on HBeAg status, ALAT and HBV DNA

Severity of disease	HBeAg status	ALAT	HBV DNA c/ml (IU/ml)	Recommended management
Chronic hepatitis	HBeAg positive	$\geq 2x$ ULN	$\geq 1.0 \times 10^5$ ($\geq 2.0 \times 10^4$)	Antiviral therapy
		$< 2x$ ULN	$\geq 1.0 \times 10^5$ ($\geq 2.0 \times 10^4$)	3-monthly monitoring, consider liver biopsy in case of persistently elevated ALAT (and antiviral therapy in case of active necroinflammation)
		$< 2x$ ULN	$< 1.0 \times 10^5$ ($< 2.0 \times 10^4$)	3-monthly monitoring
		$\geq 2x$ ULN	$< 1.0 \times 10^5$ ($< 2.0 \times 10^4$)	Exclude other cause of hepatitis, consider liver biopsy
	HBeAg negative	$\geq 2x$ ULN	$\geq 1.0 \times 10^5$ ($\geq 2.0 \times 10^4$)	Antiviral therapy
		$< 2x$ ULN	$\geq 1.0 \times 10^5$ ($\geq 2.0 \times 10^4$)	3-6 monthly monitoring, consider liver biopsy in case of persistently elevated ALAT (and antiviral therapy in case of active necroinflammation)
		$< 2x$ ULN	$< 1.0 \times 10^5$ ($< 2.0 \times 10^4$)	6-12 monthly monitoring
		$\geq 2x$ ULN	$\geq 1.0 \times 10^4$ - $< 1.0 \times 10^5$ ($\geq 2.0 \times 10^3$ - $< 2.0 \times 10^4$)	Antiviral therapy if no other causes of hepatitis are present
Compensated cirrhosis	-	-	$< 1.0 \times 10^4$ ($< 2.0 \times 10^3$) $\geq 1.0 \times 10^4$ ($\geq 2.0 \times 10^3$)	Exclude other cause of hepatitis, consider liver biopsy Antiviral therapy
Decompensated cirrhosis	-	-	> 300 (> 60)	Antiviral therapy

ULN = upper limit of normal.

DNA of above 1.0×10^4 c/ml ($>2.0 \times 10^3$ IU/ml), the regular endpoints of antiviral therapy should be applied (see also *Choice and duration of antiviral therapy*).⁶ Prophylactic antiviral therapy can also be considered in anti-HBc positive patients, since these patients are also at risk for reactivation in case of severe immunosuppression.³⁶

Recommendations	
In patients without cirrhosis, antiviral therapy is recommended in those with serum HBV DNA of at least 1.0×10^5 c/ml (2.0×10^4 IU/ml) in combination with serum ALAT above twice the upper limit of normal for at least 3 months, and/or presence of interface hepatitis or significant fibrosis on liver histology.	Level 1
In patients with cirrhosis, antiviral therapy is recommended if serum HBV DNA is 1.0×10^4 c/ml (2.0×10^3 IU/ml) or higher, irrespective of serum ALAT or HBeAg status.	Level 2
In patients with decompensated cirrhosis, antiviral therapy should be considered in those with serum HBV DNA of 1000 c/ml (200 IU/ml) or higher, irrespective of serum ALAT or HBeAg status.	Level 3
Antiviral therapy from week 32 of pregnancy until delivery can be considered in pregnant women with serum HBV DNA of 1.0×10^9 c/ml (2.0×10^8 IU/ml) or higher in order to lower the risk of failure of passive-active immunisation in the newborn.	Level 2

MONITORING OF PATIENTS NOT REQUIRING ANTIVIRAL THERAPY

Patients who do not have an indication for antiviral therapy should be monitored since disease activity may fluctuate over time (table 2). Three to six monthly monitoring of serum ALAT is recommended for HBeAg-positive patients with high viraemia (HBV DNA $\geq 1.0 \times 10^5$ c/ml or $\geq 2.0 \times 10^4$ IU/ml) and normal ALAT, with more frequent monitoring when ALAT becomes elevated. For HBeAg-negative patients with high serum HBV DNA ($\geq 1.0 \times 10^5$ c/ml or $\geq 2.0 \times 10^4$ IU/ml) and normal ALAT, monitoring is also recommended every three to six months. In those with low viraemia, six to 12 monthly monitoring suffices.

Recommendation	
Patients who are currently not candidates for antiviral therapy should be monitored since disease activity may fluctuate over time. For both HBeAg-positive and HBeAg-negative patients with high serum HBV DNA ($\geq 1.0 \times 10^5$ c/ml or $\geq 2.0 \times 10^4$ IU/ml) and normal ALAT, three to six monthly monitoring is recommended. For patients with low serum HBV DNA ($<1.0 \times 10^5$ c/ml or $<2.0 \times 10^4$ IU/ml) the recommended frequency of follow-up is once per three to six months for HBeAg-positive patients and once per six to 12 months for HBeAg-negative patients.	Level 1

GOALS OF ANTIVIRAL THERAPY

The ultimate goal of antiviral therapy for chronic HBV-infected patients is clearance of HBsAg and appearance of anti-HBs. However, since HBsAg seroconversion can only be achieved in a small proportion of patients, other surrogate endpoints of antiviral therapy have been chosen. These endpoints can generally be assessed after one year of treatment and are associated with favourable long-term outcome. The most important endpoints of antiviral therapy include HBeAg seroconversion (loss of HBeAg with appearance of anti-HBe) in previously positive patients, decline in serum HBV DNA below the lower limit of detection of a sensitive polymerase chain reaction (PCR) assay (or comparable test), biochemical response (normalisation of ALAT) and improvement of liver histology (decrease in necroinflammatory activity and no increase in fibrosis). These endpoints indicate the presence of inactive disease in patients with previous active hepatitis. Furthermore, responses can be distinguished in those sustained after discontinuation of therapy versus those that need to be maintained by antiviral therapy. In case of sustained response there is an active immune-response against the virus, as shown by HBeAg or HBsAg seroconversion. In case of treatment-maintained response there is persistent suppression of viral replication by the antiviral drug, but no active immune response. Sustained response is particularly achieved with (peg)interferon therapy, while treatment-maintained response can be achieved with long-term nucleos(t)ide analogue therapy in the majority of patients. Higher rates of sustained HBeAg seroconversion have been achieved with interferon compared with lamivudine.³⁷ It is not clear whether substantial rates of sustained response can be reached with the new potent nucleos(t)ide analogues after HBeAg seroconversion and subsequent withdrawal of therapy.

ANTIVIRAL DRUGS FOR THE TREATMENT OF CHRONIC HBV INFECTION

Peginterferon

Interferon-alpha (IFN- α) has been used for the treatment of chronic HBV infection since the 1980s. Interferons are natural occurring cytokines with immunomodulatory, antiproliferative and antiviral activity.³⁸ IFN- α has been a mainstay in the treatment of chronic HBV infection since it was licensed for this indication in the early 1990s, both in HBeAg-positive and HBeAg-negative chronic hepatitis B. In the majority of HBeAg-positive patients IFN-induced HBeAg seroconversion is durable (87%)

and eventually leads to HBsAg loss in about 50% of these responders.³⁹ The risk of developing cirrhosis and HCC is significantly lower for responders to IFN therapy compared with nonresponders.³⁹

The addition of a polyethylene glycol molecule (PEG) to the IFN has resulted in a significant increase in half-life, thereby allowing administration once weekly. In the last few years clinical research has focussed on the use of peginterferon (PEG-IFN) for the treatment of chronic hepatitis B. Two types of peginterferons have been developed (peginterferon- α 2a and peginterferon- α 2b), of which peginterferon- α 2a has been licensed for the treatment of chronic HBV infection in the Netherlands in a weekly dose of 180 μ g (subcutaneous) for 48 weeks in both HBeAg-positive and HBeAg-negative patients.

In HBeAg-positive patients, PEG-IFN appears at least as effective as conventional IFN with loss of HBeAg in 35% and seroconversion to anti-HBe in 29 to 32% of patients.⁴⁰⁻⁴³ Addition of lamivudine did not lead to an increase in sustained response rates compared with PEG-IFN monotherapy. PEG-IFN induced HBeAg loss is sustained in 80 to 86% of HBeAg-positive patients.^{44,45} HBsAg seroconversion occurs in 3 to 7% of PEG-IFN treated patient within six months after the end of therapy (10 to 20% of those with HBeAg loss).

The likelihood of HBeAg loss after PEG-IFN therapy is associated with the HBV genotype; patients with genotype A or B have a higher chance of achieving HBeAg loss than those with genotype C or D.^{42,46} Genotype A infected patients significantly more often show loss of HBeAg and HBsAg than those infected with genotype D.^{42,47}

Only one large randomised trial of PEG-IFN therapy has been performed in HBeAg-negative chronic hepatitis B.⁴⁸ Combined response of HBV DNA below 2.0×10^4 c/ml and normalisation of ALAT occurred in 36% of patients. At 24 weeks post-treatment, serum HBV DNA below 400 c/ml was observed in 19%. As in HBeAg-positive chronic hepatitis B, the addition of lamivudine did not increase response rates in these patients either. HBsAg seroconversion occurred in 4% of PEG-IFN treated HBeAg-negative patients (over 10% of those with combined response).⁴⁸

Major disadvantages of PEG-IFN therapy are the subcutaneous administration and frequent side effects (table 3). Particularly flu-like symptoms, cytopenia and psychiatric adverse events are frequently observed,⁴⁹ but rarely require discontinuation of therapy.^{49,50}

PEG-IFN is contraindicated in patients with advanced cirrhosis (albumin <35 g/l, bilirubin >34 μ mol/l or prolongation of prothrombin time by more than 4 seconds) because of the increased risk of decompensation in case of acute exacerbation.^{51,52} Other important contraindications of treatment with PEG-IFN are severe psychiatric comorbidity (depression and suicidal ideation), severe cardiac disease and autoimmune hepatitis (or other

Table 3. Undesirable effects during treatment with peginterferon alpha^{49,100-102}

Frequency	Undesirable effects
>30% (very frequent)	Flu-like symptoms Headache Fatigue Pyrexia Chills Myalgia Thrombocytopenia Induction of autoantibodies
1-30% (frequent)	Anorexia Erythema at injection site Insomnia Alopecia Lack of motivation Lack of concentration Irritability, agitation Emotional instability Depression Diarrhoea Autoimmune disease (thyroiditis, Sjögren's disease) Neutropenia Change of taste
<1% (rare)	Polynuropathy Paranoia of suicidal ideation Diabetes mellitus Retinopathy Optic neuritis Hearing loss Seizures Loss of libido Cardiotoxicity

autoimmune disorders). A major advantage of PEG-IFN therapy is the high rate of sustained response (over 80% in HBeAg-positive patients and about 40% of HBeAg-negative patients who initially responded to the treatment).^{44,45,53}

Nucleos(t)ide analogues

In the last decade there has been a major advance in the treatment of chronic hepatitis B with nucleos(t)ide analogues. These antiviral agents inhibit the viral polymerase and thereby viral replication. Advantages of nucleos(t)ide analogues are the oral administration, rapid decline in HBV DNA and minimal side effects. A major disadvantage is that the majority of patients need prolonged or even indefinite therapy, as sustainability of response after discontinuation of therapy is limited. Furthermore, the risk of antiviral resistance increases with the duration of antiviral therapy. Antiviral resistance is caused by the selective selection of naturally occurring mutations in the HBV polymerase. Rapid and profound viral suppression reduces the risk of antiviral resistance.⁵⁴

Lamivudine

Lamivudine was the first nucleoside analogue licensed for the treatment of chronic HBV infection in 1999. Lamivudine should be given in a dosage of 100 mg daily and has excellent safety and tolerability. In HBeAg-positive

patients, treatment with lamivudine for one year results in HBeAg seroconversion plus serum HBV DNA below 1.0×10^5 c/ml (2.0×10^4 IU/ml) in 16 to 22% of patients.⁵⁵⁻⁶⁰ The rate of HBeAg seroconversion increases with increasing duration of therapy to 29, 40 and 47% after two, three and four years of therapy, respectively.^{57,58,61} Decline in HBV DNA below 7.0×10^5 c/ml (1.4×10^5 IU/ml) was observed in 65% of patients.⁶²

In HBeAg-negative patients, serum HBV DNA below 400 c/ml (<80 IU/ml) was observed in 68 to 73% of patients after one year of lamivudine. Of these patients 68 to 96% also had a biochemical response.^{48,63,64} In HBeAg-negative patients the rate of virological response declined with increasing duration of therapy, largely due to the increasing risk of antiviral resistance. Response rates at year two, three and four were 67, 60 and 39%, respectively.^{63,65,66} Treatment with lamivudine has been shown to result in a decrease of disease progression and development of HCC in patients with advanced fibrosis or cirrhosis compared with untreated controls.⁶⁷

The major disadvantage of lamivudine is the high incidence of antiviral resistance. The majority of patients with viral breakthrough have mutations in the tyrosine-methionine-aspartate-aspartate motif (YMDD) of the HBV polymerase.⁶⁶ The most frequently observed mutation is a substitution of methionine for valine or isoleucine at position 204 of the HBV polymerase.⁶⁸ Lamivudine resistance occurred in 24% of patients after one year, which increased to 71% after five years.⁶⁹ The selection of resistance mutations is often followed by an increase in ALAT.⁶⁶ Another disadvantage of lamivudine is the high risk of relapse after discontinuation of therapy; half of patients with lamivudine-induced HBeAg seroconversion had a relapse at two to three years after therapy.^{37,70}

Adefovir

Adefovir is a nucleotide analogue with activity against wild-type and lamivudine-resistant HBV. Adefovir was licensed for the treatment of chronic hepatitis B in the Netherlands in 2003 in a daily dosage of 10 mg. Higher dosages may be more effective, but are associated with nephrotoxicity.⁷¹

In HBeAg-positive patients, a one-year course of adefovir resulted in HBeAg seroconversion in 12%, serum HBV DNA below 1.0×10^3 c/ml (200 IU/ml) in 21% and normalisation of ALAT in 48% of patients.⁷¹ The rate of HBeAg seroconversion increased with increasing duration of therapy to 29% after two years and 43% after three years of treatment. The proportion of patients with HBV DNA below 1.0×10^3 c/ml (200 IU/ml) increased to 45 and 56% after two and three years, respectively.⁷²

Serum HBV DNA below 1.0×10^3 c/ml (200 IU/ml) and normalisation of ALAT were observed in 51 and 72% of

HBeAg-negative patients after one year of adefovir.⁷³ After five years of therapy, the proportion of patients with HBV DNA below 1.0×10^3 c/ml (200 IU/ml) increased to 67% and to 69% for ALAT normalisation.^{74,75} Histological response was observed in 75 to 80% of adefovir-treated patients at year five.⁷⁴ However, more recent studies suggested lower response rates during adefovir therapy, with serum HBV DNA above 1.0×10^4 c/ml (2.0×10^3 IU/ml) in 50% of patients after six months of therapy.⁷⁶

HBeAg loss occurred in 20% of lamivudine-resistant patients treated with adefovir.⁷⁷ The proportion of lamivudine-resistant patients with HBV DNA below 400 c/ml (80 IU/ml) was 19% after one year of adefovir therapy.⁷⁷

Antiviral resistance to adefovir occurs less frequently and later during the course of therapy compared with lamivudine. The most important mutations in the HBV polymerase associated with adefovir resistance include a substitution of asparagine for threonine at position 236 and a substitution of alanine for valine or threonine at position 181.^{75,78} The reported incidence of adefovir resistance is 0% at year one, 22% at year two and 28% at year five of antiviral therapy.^{74,76} In lamivudine-resistant patients treated with adefovir monotherapy the rate of antiviral resistance was 6 to 18% after one year and 21 to 38% after two years.^{77,79,80}

Entecavir

Entecavir is a guanine analogue, which was licensed for the treatment of chronic hepatitis B in the Netherlands in 2006. In nucleoside-naïve patients, entecavir is given in a daily dosage of 0.5 mg. A daily dose of 1 mg should be used in patients with pre-existent lamivudine resistance. Three large randomised trials have compared entecavir with lamivudine for the treatment chronic hepatitis B.^{62,81,82} Decline in HBV DNA was significantly greater with entecavir than lamivudine in both HBeAg-positive and HBeAg-negative patients.^{62,81}

HBeAg seroconversion occurred in 21% of entecavir-treated HBeAg-positive patients after one year, while serum HBV DNA below 300 c/ml (60 IU/ml) or below 7.0×10^5 c/ml (1.4×10^5 IU/ml) was observed in 67 and 91% of patients.⁶² The cumulative proportion of patients with undetectable HBV DNA (300 c/ml (60 IU/ml)) increased to 82% after three years of therapy.⁸³ After one year of entecavir treatment, serum ALAT normalised in 68% of patients, which increased to 90% of patients after three years.⁸³ The proportion of patients with HBeAg loss also increased, to 39% after three years of therapy.⁸³

In HBeAg-negative patients, treatment with entecavir resulted in normalisation of ALAT and HBV DNA below 300 c/ml (200 IU/ml) in 78 and 89, and 90 and 94% of patients after one and two years of therapy, respectively.^{81,84} Histological response was observed in 70% of entecavir-treated patients after one year.⁸¹

Response to entecavir was lower in lamivudine-resistant patients, with undetectable HBV DNA in 19% and ALAT normalisation in 61% of patients after 48 weeks of entecavir therapy.⁸² HBeAg loss was observed in 8% of these patients.⁸²

The rate of entecavir resistance was extremely low in nucleoside-naïve patients with antiviral resistance observed in less than 1% of patients after four years of entecavir therapy.⁸⁵⁻⁸⁷ However, in lamivudine-resistant patients the risk of antiviral resistance is much higher with entecavir resistance in 12, 20, 25 and 40% after one to four years of therapy, respectively.⁸⁶⁻⁸⁸ These findings implicate cross-resistance of lamivudine and entecavir; entecavir resistance requires pre-existent lamivudine resistance mutations.

Telbivudine

Telbivudine is a nucleoside analogue belonging to the same group of antiviral agents as lamivudine. Telbivudine is administered orally in a daily dosage of 600 mg. Telbivudine has been licensed for the treatment of chronic hepatitis B in the Netherlands since 2007. In both HBeAg-positive and HBeAg-negative patients, telbivudine resulted in more profound viral suppression than lamivudine.⁸⁹

After one year of treatment with telbivudine HBeAg seroconversion occurred in 22% of HBeAg-positive patients, increasing to 29% after two years of therapy.^{89,90} The proportion of patients with serum HBV DNA below 300 c/ml (60 IU/ml) was 60% after one year and 54% after two years of telbivudine therapy. Eighty percent of patients who stopped telbivudine treatment after achieving HBeAg seroconversion had sustained response after a mean period of 35 weeks post-treatment, which was comparable with lamivudine therapy.⁹¹

Treatment with telbivudine resulted in HBV DNA below 300 c/ml (60 IU/ml) in 88% of HBeAg-negative patients after one year and 79% after two years. Combined response of HBV DNA below 1.0×10^5 c/ml ($<2.0 \times 10^4$ IU/ml) and normalisation of ALAT was observed in 75 and 74% of patients after one and two years of therapy, respectively.

Since telbivudine and lamivudine belong to the same group of nucleoside analogues, there is cross-resistance between the two drugs. A substitution of methionine for isoleucine at position 204 is associated with telbivudine resistance. Telbivudine resistance was observed in 2 to 3% of patients after one year and in 7 to 17% after two years of telbivudine therapy.^{89,90} The risk of antiviral resistance was strongly associated with viral load at week 24 of treatment. The two-year rate of telbivudine resistance was 4% in HBeAg-positive patients and 2% in HBeAg-negative patients if serum HBV DNA was below 300 c/ml (60 IU/ml) after 24 weeks of therapy. At week 24, HBV DNA below this level was observed in 45 and 80% of HBeAg-positive and HBeAg-negative patients, respectively.⁸⁹

CHOICE AND DURATION OF (INITIAL) THERAPY

When deciding on the antiviral drug to be given, several factors have to be taken into account (*table 4*). The major advantage of PEG-IFN is the higher chance of achieving sustained response compared with nucleos(t)ide analogues with a finite duration of therapy. Disadvantages are the subcutaneous administration and the frequent occurrence of side effects. The major advantages of nucleos(t)ide analogues are the favourable tolerability and the oral administration. Disadvantages are the long duration of therapy and the subsequent risk of antiviral resistance. The costs of a one-year course of nucleos(t)ide analogue therapy are lower than of PEG-IFN, but will easily be higher when long-term therapy is needed.

Table 4. Choice of initial therapy based on patient characteristics

Patient characteristics	Peginterferon	Nucleos(t)ide analogue
HBeAg status	HBeAg positive	HBeAg negative
HBV genotype	A or B	C or D
HBV DNA	$\leq 1.0 \times 10^9$ c/ml (2.0×10^8 IU/ml)	$> 1.0 \times 10^9$ c/ml (2.0×10^8 IU/ml)
ALAT	$> 2 \times 10$ ULN	1-2 or > 10 ULN
Severity of liver disease	Compensated	Compensated or decompensated

ULN = upper limit of normal. The above-mentioned characteristics may be of help in choosing an antiviral agent, but do not provide strict recommendations.

PEG-IFN should always be considered as first-line therapy in eligible patients because of the higher chance of achieving sustained off-treatment response compared with nucleos(t)ide analogues (*table 5*), particularly in HBeAg-positive patients. Sustained transition to the immune-control phase (inactive HBsAg carrier state) can be achieved in 30 to 35% of HBeAg-positive patients and 25% of HBeAg-negative patients treated with PEG-IFN, implicating that treatment-induced response is sustained in about 85 and 40% of HBeAg-positive and HBeAg-negative patients, respectively.^{45,53} Relapse occurs in at least 40 and 90% of HBeAg-positive and HBeAg-negative patients after discontinuation of nucleos(t)ide analogue therapy, respectively.^{64,73,75,92} The latter applies especially to the older nucleos(t)ide analogues. There are insufficient data available for the newer, more potent, nucleos(t)ide analogues.

Patients with a high chance of response to PEG-IFN therapy are those with genotype A or B, with serum HBV DNA below 1.0×10^9 c/ml (2.0×10^8 IU/ml) and serum ALAT above twice the upper limit of normal.^{42,93,94} The licensed duration of peginterferon therapy is one year for both HBeAg-positive and HBeAg-negative chronic hepatitis B. However, the optimal

Table 5. Response after one year of antiviral therapy and antiviral resistance after 1 to 5 years of therapy

Antiviral therapy	HBeAg positive		HBeAg negative		Antiviral resistance				
	HBeAg seroconversion		Undetectable HBV DNA		Year 1	Year 2	Year 3	Year 4	Year 5
	End of therapy	Post-treatment	End of therapy	Post-treatment					
Alpha-interferon	35% ^{38,103,107}	30% ^{39,41,103,108}	60% ^{109,115}	35% ^{109,112,115}	-	-	-	-	-
Peginterferon	40% ^{40,43}	35% ^{40,44}	63% ⁴⁸	19% ⁴⁸	-	-	-	-	-
Lamivudine	19% ^{55,56,58,60}	12% ^{44,70,92}	65% ^{48, 63, 65}	10% ^{48, 64}	24% ¹¹⁶	42% ¹¹⁶	53% ¹¹⁶	70% ¹¹⁶	74% ¹¹⁷
Adefovir	12% ⁷¹	NA	51% ⁷³	NA	0% ⁷⁴	3% ⁷⁴	11% ⁷⁴	18% ⁷⁴	28% ⁷⁴
Adefovir in lamivudine resistance	20% ⁷⁷	NA	19% ^{#77}	NA	6-18% ^{77,79,80}	21-38% ^{77,79,80}	NA	NA	NA
Entecavir	21% ⁶²	NA	90% ⁸¹	NA	0.1% ⁸⁵	0.3% ⁸⁵	0.4% ⁸⁷	0.8% ⁸⁶	NA
Entecavir in lamivudine resistance	8% ⁸²	NA	26% ^{#118}	NA	12% ⁸⁵	20% ⁸⁵	25% ⁸⁷	40% ⁸⁶	NA
Telbivudine	22% ⁸⁹	NA	88% ⁸⁹	NA	2-3% ⁸⁹	7-17% ⁹⁰	NA	NA	NA

#HBV DNA <400 c/ml in a mixed group of HBeAg-positive and HBeAg-negative patients. NA = not available.

duration of PEG-IFN therapy has not been established. In HBeAg-positive patients, response rates after 24 to 32 weeks of treatment seem comparable with those observed after one year, but head-to-head comparison is not available.⁴⁰⁻⁴³ Since early prediction of response to PEG-IFN is not possible in chronic HBV-infected patients, the recommended the duration of therapy is one year for all patients.

Nucleos(t)ide analogue therapy should be considered in patients not responding to or not eligible for PEG-IFN therapy. This includes patients with autoimmune disease, pre-existent psychiatric disorders or advanced cirrhosis (signs of diminished liver function or portal hypertension). When choosing a nucleos(t)ide analogue, potency and risk of resistance play an important role (table 5). Because of the high risk of antiviral resistance, lamivudine should no longer be considered to be the initial therapy in patients who require long-term therapy. However, because of extensive clinical experience, lamivudine can be given to pregnant patients with very high viraemia during the last trimester of pregnancy.³³ Of the currently available nucleos(t)ide analogues, entecavir has the most favourable resistance profile (in comparison with lamivudine, adefovir and telbivudine) (table 5),⁸⁷ while entecavir and telbivudine seem most potent.^{62,89,95} However, little is known about the long-term safety of entecavir and telbivudine. In patients with lamivudine resistance, treatment with entecavir is not recommended because of the high risk of antiviral resistance. Adefovir add-on therapy is recommended for these patients. The role of telbivudine in the treatment is not yet established. The role of *de-novo* combination therapy of nucleos(t)ide analogues is also unclear. A combination of antiviral drugs could potentially prevent the selection of resistance mutations, but supporting scientific evidence is not available.

In HBeAg-positive patients, nucleos(t)ide analogue therapy should be continued at least until HBeAg seroconversion

and HBV DNA below 400 c/ml (80 IU/ml) have been achieved and maintained for six months. It is unclear when nucleos(t)ide analogue therapy can be safely discontinued in HBeAg-negative patients, this may be possible in case of HBsAg seroconversion and HBV DNA below 400 c/ml (80 IU/ml). Nucleos(t)ide analogue therapy therefore needs to be continued for long periods in virtually all HBeAg-negative patients.

Recommendations	
PEG-IFN should be considered the first-line therapy in patients without contraindications because of the higher chance of achieving sustained response compared with nucleos(t)ide analogues.	Level 1
Nucleos(t)ide analogue therapy should be considered in patients not eligible for, not tolerating or not responding to PEG-IFN therapy.	Level 1
Lamivudine is not recommended in patients in whom long-term nucleos(t)ide analogue is expected because of the high risk of antiviral resistance.	Level 1
Of the currently available nucleos(t)ide analogues, entecavir has the lowest risk of antiviral resistance (compared with lamivudine, adefovir and telbivudine). Entecavir and telbivudine seem to provide the most potent viral suppression.	Level 2
The recommended duration of PEG-IFN therapy is one year for both HBeAg-positive and HBeAg-negative patients.	Level 3
In HBeAg-positive patients, nucleos(t)ide analogue therapy should at least be continued until HBeAg seroconversion and a decline in HBV DNA below 400 c/ml (80 IU/ml) have been achieved and maintained for six months during therapy.	Level 2
In HBeAg-negative patients, it is unknown whether nucleos(t)ide analogues can be safely discontinued. Long-term or indefinite antiviral treatment is usually necessary.	Level 2

MONITORING OF ANTIVIRAL THERAPY

PEG-IFN treated patients should be monitored monthly; an additional visit at week two can be considered. Frequently occurring side effects such as depression, irritability, neutropenia and thrombocytopenia require monthly monitoring and blood count. If necessary, PEG-IFN dosage should be reduced or treatment temporarily discontinued. PEG-IFN dosage should be reduced if the neutrophil count is below $0.75 \times 10^9/l$ or the platelet count below $50 \times 10^9/l$. The dose can be reduced by 25% of the original dose until the respective cell fractions have normalised. Temporary discontinuation of PEG-IFN therapy is indicated if the neutrophil count is below $0.50 \times 10^9/l$ or the platelet count below $25 \times 10^9/l$. Severe side effects such as depression or severe flu-like may also require dose reduction or even (temporary) discontinuation of therapy.

Recommendations on laboratory testing during PEG-IFN and nucleos(t)ide analogue therapy are shown in *table 6*. The recommended frequency of HBV DNA quantification during antiviral therapy is every three to six months, dependent on the risk of antiviral resistance. Testing of serum ALAT is recommended every three months. Prior to the start of nucleos(t)ide analogue therapy a quantitative HBV DNA

test and HBV serology should be performed in order to evaluate response to therapy. The recommended frequency of monitoring during nucleos(t)ide analogue therapy is every three months, particularly for the early detection of antiviral resistance. Monitoring of serum creatinine is indicated every three months and nucleos(t)ide analogue dosage or frequency of administration should be reduced in case of severely decreased creatinine clearance ($<50 \text{ ml/min}$) (*table 7*). Although nucleos(t)ide analogue therapy generally has an excellent safety and tolerability profile, severe side effects such as lactic acidosis have been described.⁹⁶

Recommendation

The recommended frequency of monitoring is monthly during PEG-IFN therapy and every three months during nucleos(t)ide analogue therapy.

Level 2

Antiviral resistance

Primary nonresponse is defined as a less than $2 \log_{10} \text{ c/ml}$ (or IU/ml) decline in HBV DNA after 24 weeks of nucleos(t)ide analogue therapy.⁶ Potential causes of primary nonresponse include antiviral resistance, but also noncompliance, decreased absorption or rapid breakdown.⁹⁷ The risk of antiviral resistance is minimal if serum HBV DNA is 400 c/ml or lower after 24 weeks of therapy. Addition of adefovir or

Table 6. Recommendations on minimal laboratory testing during antiviral therapy

	Start of therapy	PEG-IFN 4-weekly [†]	PEG-IFN 3-monthly	Nucleos(t)ide analogues 3-monthly
Aminotransferases (ASAT, ALAT)	X	X		X
Liver function (bilirubin, albumin, prothrombin time)	X		X	X
Kidney function (creatinine) [‡]	X		X	X
Blood count (platelets, neutrophil count)	X	X		
Endocrinology (TSH)	X [#]		X	
Virus serology (HBsAg, [§] anti-HBs, [§] HBeAg, anti-HBe)	X		X	X
Quantitative HBV DNA	X		X [£]	X [£]

[†]Also after 2 weeks of therapy; [‡]assessment of 24-hour creatinine clearance is recommended in patients with elevated creatinine; [#]only for PEG-IFN treated patients; [§]HBsAg and anti-HBs only after HBeAg seroconversion or repeatedly undetectable HBV DNA (HBV DNA $<400 \text{ c/ml}$ or $<80 \text{ IU/ml}$); [£]quantitative HBV DNA every 3-6 months.

Table 7. Adjustment of nucleos(t)ide analogue dosing in accordance with creatinine clearance

Creatinine clearance	Lamivudine	Adefovir	Entecavir in naive patients	Entecavir in lamivudine resistance	Telbivudine
$<5 \text{ ml/min}$ /haemodialysis/ CAPD	10 mg/day (starting dose 35 mg)	10 mg/7 days [‡]	0.05 mg/day	0.1 mg/day	600 mg/4 days [‡]
5-9 ml/min/haemodialysis/ CAPD	15 mg/day (starting dose 35 mg)	10 mg/7 days [‡]	0.05 mg/day	0.1 mg/day	600 mg/4 days [‡]
10-14 ml/min	15 mg/day (starting dose 35 mg)	10 mg/3 days	0.15 mg/day	0.3 mg/day	600 mg/3 days
15-19 ml/min	25 mg/day (starting dose 100 mg)	10 mg/3 days	0.15 mg/day	0.3 mg/day	600 mg/3 days
20-29 ml/min	25 mg/day (starting dose 100 mg)	10 mg/2 days	0.15 mg/day	0.3 mg/day	600 mg/3 days
30-49 ml/min	50 mg/day (starting dose 100 mg)	10 mg/2 days	0.25 mg/day	0.5 mg/day	600 mg/2 days
$\geq 50 \text{ ml/min}$	100 mg/day	10 mg/day	0.5 mg/day	1 mg/day	600 mg/day

CAPD = continuous ambulant peritoneal dialysis. [‡]No recommendations can be made for adefovir-treated patients with creatinine clearance $<10 \text{ ml/min}$; [§]telbivudine should be administered after haemodialysis. Source: Farmacotherapeutisch Kompas (<http://www.fk.cvz.nl/>).

switching to entecavir is recommended in telbivudine-treated patients with serum HBV DNA above 400 c/ml (80 IU/ml) after 24 weeks of therapy. This should also be considered in patients treated with lamivudine. Antiviral resistance is rare in adefovir-treated patients during the first year of antiviral treatment. However, addition of telbivudine or switching to entecavir should be considered in patients with serum HBV DNA above 1000 c/ml (200 IU/ml) after 12 months of therapy because of the increasing risk of antiviral resistance in these patients.

Antiviral resistance should be suspected if serum HBV DNA increases during nucleos(t)ide analogue therapy. If virological breakthrough, defined as a 1 log₁₀ c/ml (or IU/ml) increase in HBV DNA, is observed in compliant patients, genotypic analysis of the HBV polymerase is indicated.⁹⁷ A rise in HBV DNA is the first sign of antiviral resistance and is often followed by a rise in ALAT without intervention.⁹⁷

In case of antiviral resistance it is recommended to change antiviral therapy as soon as possible since response to the second drug is better when started at the time of virological breakthrough than at the time of biochemical breakthrough.⁹⁸ Adding a second drug seems favourable over switching to another drug, since this significantly reduces the risk of antiviral resistance to the second drug.⁹⁹ However, adding a second nucleos(t)ide analogue does not lead to more profound viral suppression compared with monotherapy of the new drug.⁹⁹ Adding adefovir is preferred over switching to entecavir in lamivudine-resistant patients because of the lower risk of antiviral resistance. If entecavir is started, lamivudine should be discontinued. In adefovir-resistant patients, treatment with entecavir is preferred.⁶ Table 8 shows the recommendations for the management of antiviral resistance. In case of resistance to other antiviral agents or multiple drugs, consulting a centre with expertise on this topic is recommended.

Table 8. Treatment options for patients with antiviral resistance

Type of antiviral resistance	Treatment options [‡]
Lamivudine resistance	Adefovir add-on (Switch to entecavir)
Adefovir resistance	Entecavir add-on (Telbivudine add-on) (Lamivudine add-on) (Switch to entecavir)
Entecavir resistance	Adefovir add-on
Telbivudine resistance	Adefovir add-on (Switch to entecavir)

[‡]Controlled studies are often not available. Treatment options between brackets are not preferred.

Recommendations	
In telbivudine-treated patients, changing antiviral therapy is recommended if serum HBV DNA is higher than 400 c/ml (80 IU/ml) after 24 weeks of therapy because of the risk of antiviral resistance.	Level 2
In adefovir-treated patients, changing antiviral therapy is recommended if serum HBV DNA is higher than 1000 c/ml (200 IU/ml) after 12 months of therapy because of the risk of antiviral resistance.	Level 4
Confirmation of the HBV DNA measurement and genotypic analysis of the HBV polymerase is indicated in compliant patients with virological breakthrough, as defined by a more than 1 log ₁₀ c/ml (or IU/ml) increase in serum HBV DNA, as this often is associated with antiviral resistance.	Level 1
Antiviral treatment should be changed as soon as possible in case of antiviral resistance.	Level 2
Adding a second nucleos(t)ide analogue is preferable over switching to another drug because of the lower risk of antiviral resistance to the second drug.	Level 3
In lamivudine-resistant patients, addition of adefovir is preferred over switching to entecavir because of the high risk of entecavir resistance in these patients.	Level 2

FOLLOW-UP AFTER ANTIVIRAL THERAPY

Liver biochemistry, quantification of HBV DNA and HBV serology should be repeated three to six months post-treatment in PEG-IFN treated patients to assess the presence of sustained response. This is also recommended for responders to nucleos(t)ide analogue treatment who stopped antiviral therapy, although more frequent monitoring after discontinuation can be considered because of the higher risk of relapse compared with PEG-IFN.³⁷ In HBeAg-negative patients with serum HBV DNA below 1.0 x 10⁵ c/ml (2.0 x 10⁴ IU/ml) and normal ALAT, yearly monitoring of ALAT for three years suffices. These patients could also be monitored by their general practitioner. The Dutch Society of General Practitioners (NHG) also recommends this frequency of follow-up in their guideline 'Viral hepatitis and other liver diseases'. If a rise in serum ALAT is observed, the patient should be referred to the treating specialist. In patients with HBsAg seroconversion (loss of HBsAg and anti-HBs >10 IU/l), monitoring of disease activity and prophylactic treatment should only be considered in case of severe immunosuppression, e.g. chemotherapy or treatment with selective antibodies.

ACKNOWLEDGEMENT

We thank Dr. B. van Hoek and Dr. G.H. Koek for their extensive peer review of the manuscript.

NOTE

Guidelines Committee for the Netherlands Association of Gastroenterologists and Hepatologists: H.L.A. Janssen, chairman; E.H.C.J. Buster, H.C. Gelderblom, secretaries; C.M. Bakker, J.T. Brouwer, K.J. van Erpecum, R.J. de Knegt, H.W. Reesink, S.W. Schalm, H.L. Zaaijer, members.

REFERENCES

1. Kane M. Global programme for control of hepatitis B infection. *Vaccine*. 1995;13(Suppl.1):S47-9.
2. Lee WM. Hepatitis B virus infection. *N Engl J Med*. 1997;337(24):1733-45.
3. De Franchis R, Hadengue A, Lau G, et al. EASL International Consensus Conference on Hepatitis B. 13-14 September, 2002 Geneva, Switzerland. Consensus statement (long version). *J Hepatol*. 2003;39(Suppl.1):S3-25.
4. Veldhuijzen IK, Conyn-van Spaendonck MAE, Dorigo-Zetsma JW. Seroprevalentie van hepatitis B en C in de Nederlandse bevolking. *Infectieziekten Bulletin*. 1999;10(9):182-4.
5. Liaw YF, Leung N, Guan R, et al. Asian-Pacific consensus statement on the management of chronic hepatitis B: a 2005 update. *Liver Int*. 2005 Jun;25(3):472-89.
6. Lok AS, McMahon BJ. Chronic hepatitis B. *Hepatology*. 2007 Jan 26;45(2):507-39.
7. Wong SN, Lok AS. Treatment of hepatitis B: who, when, and how? *Arch Intern Med*. 2006 Jan 9;166(11):9-12.
8. Chang MH. Natural history of hepatitis B virus infection in children. *J Gastroenterol Hepatol*. 2000 May;15 Suppl:E16-9.
9. Fattovich G, Brollo L, Giustina G, et al. Natural history and prognostic factors for chronic hepatitis type B. *Gut*. 1991 Mar;32(3):294-8.
10. Mathurin P, Moussalli J, Cadranel JF, et al. Slow progression rate of fibrosis in hepatitis C virus patients with persistently normal alanine transaminase activity. *Hepatology*. 1998 Mar;27(3):868-72.
11. Iloeje UH, Yang HI, Su J, Jen CL, You SL, Chen CJ. Predicting cirrhosis risk based on the level of circulating hepatitis B viral load. *Gastroenterology*. 2006 Mar;130(3):678-86.
12. Poynard T, Bedossa P, Opolon P. Natural history of liver fibrosis progression in patients with chronic hepatitis C. The OBSVIRC, METAVIR, CLINIVIR, and DOSVIRC groups. *Lancet*. 1997 Mar 22;349(9055):825-32.
13. De Jongh FE, Janssen HL, de Man RA, Hop WC, Schalm SW, van Blankenstein M. Survival and prognostic indicators in hepatitis B surface antigen-positive cirrhosis of the liver. *Gastroenterology*. 1992 Nov;103(5):1630-5.
14. Fattovich G, Giustina G, Schalm SW, et al. Occurrence of hepatocellular carcinoma and decompensation in western European patients with cirrhosis type B. The EUROHEP Study Group on Hepatitis B Virus and Cirrhosis. *Hepatology*. 1995 Jan;21(1):77-82.
15. Realdi G, Fattovich G, Hadziyannis S, et al. Survival and prognostic factors in 366 patients with compensated cirrhosis type B: a multicenter study. The Investigators of the European Concerted Action on Viral Hepatitis (EUROHEP). *J Hepatol*. 1994 Oct;21(4):656-66.
16. Fattovich G, Stroffolini T, Zagni I, Donato F. Hepatocellular carcinoma in cirrhosis: incidence and risk factors. *Gastroenterology*. 2004 Nov;127(5 Suppl 1):S35-50.
17. Chen CJ, Yang HI, Su J, et al. Risk of hepatocellular carcinoma across a biological gradient of serum hepatitis B virus DNA level. *JAMA*. 2006 Jan 4;295(1):65-73.
18. Iloeje UH, Yang HI, Su J, et al. Viral load is a strong predictor of hepatocellular carcinoma risk in people chronically infected with hepatitis B virus and with normal serum alanine aminotransferase level. *J Viral Hepat*. 2005;42(Suppl. 2):179.
19. Yang HI, Lu SN, Liaw YF, et al. Hepatitis B e antigen and the risk of hepatocellular carcinoma. *N Engl J Med*. 2002 Jul 18;347(3):168-74.
20. Cadranel JF, Lahmek P, Causse X, et al. Epidemiology of chronic hepatitis B infection in France: risk factors for significant fibrosis--results of a nationwide survey. *Aliment Pharmacol Ther*. 2007 Aug 15;26(4):565-76.
21. Hui CK, Leung N, Yuen ST, et al. Natural history and disease progression in Chinese chronic hepatitis B patients in immune-tolerant phase. *Hepatology*. 2007 Aug;46(2):395-401.
22. Trevisani F, De NS, Rapaccini G, et al. Semiannual and annual surveillance of cirrhotic patients for hepatocellular carcinoma: effects on cancer stage and patient survival (Italian experience). *Am J Gastroenterol*. 2002 Mar;97(3):734-44.
23. Bruix J, Sherman M. Management of hepatocellular carcinoma. *Hepatology*. 2005 Nov;42(5):1208-36.
24. Zhang BH, Yang BH, Tang ZY. Randomized controlled trial of screening for hepatocellular carcinoma. *J Cancer Res Clin Oncol*. 2004 Jul;130(7):417-22.
25. Garcia-Tsao G, Sanyal AJ, Grace ND, Carey W. Prevention and management of gastroesophageal varices and variceal hemorrhage in cirrhosis. *Hepatology*. 2007 Sep;46(3):922-38.
26. Chu CM, Liaw YF. Increased incidence of fulminant hepatic failure in previously unrecognized HBsAg carriers with acute hepatitis independent of etiology. *Infection*. 2005 Jun;33(3):136-9.
27. Reiss G, Keeffe EB. Review article: hepatitis vaccination in patients with chronic liver disease. *Aliment Pharmacol Ther*. 2004 Apr 1;19(7):15-27.
28. McMahon BJ. Epidemiology and natural history of hepatitis B. *Semin Liver Dis*. 2005;25 Suppl 1:3-8.
29. Manesis EK, Papatheodoridis GV, Sevastianos V, Cholongitas E, Papaioannou C, Hadziyannis SJ. Significance of hepatitis B viremia levels determined by a quantitative polymerase chain reaction assay in patients with hepatitis B e antigen-negative chronic hepatitis B virus infection. *Am J Gastroenterol*. 2003 Oct;98(10):2261-7.
30. Fontana RJ, Hann HW, Perrillo RP, et al. Determinants of early mortality in patients with decompensated chronic hepatitis B treated with antiviral therapy. *Gastroenterology*. 2002 Sep;123(3):719-27.
31. Villeneuve JP, Condreay LD, Willems B, et al. Lamivudine treatment for decompensated cirrhosis resulting from chronic hepatitis B. *Hepatology*. 2000 Jan;31(1):207-10.
32. Del Canho R, Grosheide PM, Mazel JA, et al. Ten-year neonatal hepatitis B vaccination program, The Netherlands, 1982-1992: protective efficacy and long-term immunogenicity. *Vaccine*. 1997 Oct;15(15):1624-30.
33. Van Zonneveld M, van Nunen AB, Niesters HG, de Man RA, Schalm SW, Janssen HL. Lamivudine treatment during pregnancy to prevent perinatal transmission of hepatitis B virus infection. *J Viral Hepat*. 2003 Jul;10(4):294-7.
34. Xu WM, Cui YT, Wang L, et al. Efficacy and safety of lamivudine in late pregnancy for the prevention of mother-child transmission of hepatitis B: a multicenter, randomized, double-blind, placebo-controlled study. *Hepatology*. 2004;40(Suppl.4):272A-3A.
35. Keeffe EB, Dieterich DT, Han SH, et al. A treatment algorithm for the management of chronic hepatitis B virus infection in the United States: an update. *Clin Gastroenterol Hepatol*. 2006 Aug;4(8):936-62.
36. Kohrt HE, Ouyang DL, Keeffe EB. Systematic review: lamivudine prophylaxis for chemotherapy-induced reactivation of chronic hepatitis B virus infection. *Aliment Pharmacol Ther*. 2006 Oct 1;24(7):1003-16.
37. Van Nunen AB, Hansen BE, Suh DJ, et al. Durability of HBeAg seroconversion following antiviral therapy for chronic hepatitis B: relation to type of therapy and pretreatment serum hepatitis B virus DNA and alanine aminotransferase. *Gut*. 2003 Mar;52(3):420-4.
38. Haria M, Benfield P. Interferon-alpha-2a. A review of its pharmacological properties and therapeutic use in the management of viral hepatitis. *Drugs*. 1995 Nov;50(5):873-96.
39. Van Zonneveld M, Honkoop P, Hansen BE, et al. Long-term follow-up of alpha-interferon treatment of patients with chronic hepatitis B. *Hepatology*. 2004;39(3):804-10.

Buster, et al. Treatment of chronic hepatitis B virus infection.

40. Chan HL, Leung NW, Hui AY, et al. A randomized, controlled trial of combination therapy for chronic hepatitis B: comparing pegylated interferon-alpha2b and lamivudine with lamivudine alone. *Ann Intern Med.* 2005 Feb 15;142(4):240-50.
41. Cooksley WG, Piratvisuth T, Lee SD, et al. Peginterferon alpha-2a (40 kDa): an advance in the treatment of hepatitis B e antigen-positive chronic hepatitis B. *J Viral Hepat.* 2003 Jul;10(4):298-305.
42. Janssen HL, van Zonneveld M, Senturk H, et al. Pegylated interferon alfa-2b alone or in combination with lamivudine for HBeAg-positive chronic hepatitis B: a randomised trial. *Lancet.* 2005;365(9454):123-9.
43. Lau GK, Piratvisuth T, Luo KX, et al. Peginterferon Alfa-2a, lamivudine, and the combination for HBeAg-positive chronic hepatitis B. *N Engl J Med.* 2005;352(26):2682-95.
44. Chan HL, Hui AY, Wong VW, Chim AM, Wong ML, Sung JJ. Long-term follow-up of peginterferon and lamivudine combination treatment in HBeAg-positive chronic hepatitis B. *Hepatology.* 2005 Jun;41(6):1357-64.
45. Lau GK, Piratvisuth T, Luo KX, et al. Durability of response and occurrence of late response to peginterferon alpha-2a (40KD) one year post-treatment in patients with HBeAg-positive chronic hepatitis B. *J Hepatol.* 2006;44(Suppl. 2):S23.
46. Zhao H, Kurbanov F, Wan MB, et al. Genotype B and younger patient age associated with better response to low-dose therapy: a trial with pegylated/nonpegylated interferon-alpha-2b for hepatitis B e antigen-positive patients with chronic hepatitis B in China. *Clin Infect Dis.* 2007 Feb 15;44(4):541-8.
47. Flink HJ, van Zonneveld M, Hansen BE, de Man RA, Schalm SW, Janssen HL. Treatment with peg-interferon alpha-2b for HBeAg-positive chronic hepatitis B: HBsAg loss is associated with HBV genotype. *Am J Gastroenterol.* 2006 Feb;101(2):297-303.
48. Marcellin P, Lau GK, Bonino F, et al. Peginterferon alfa-2a alone, lamivudine alone, and the two in combination in patients with HBeAg-negative chronic hepatitis B. *N Engl J Med.* 2004 Sep 16;351(12):1206-17.
49. Van Zonneveld M, Flink HJ, Verhey E, et al. The safety of pegylated interferon alpha-2b in the treatment of chronic hepatitis B: predictive factors for dose reduction and treatment discontinuation. *Aliment Pharmacol Ther.* 2005 May 1;21(9):1163-71.
50. Janssen HL, Berk L, Vermeulen M, Schalm SW. Seizures associated with low-dose alpha-interferon. *Lancet.* 1990 Dec 22-29;336(8730):1580.
51. Janssen HL, Brouwer JT, Nevens F, Sanchez-Tapias JM, Craxi A, Hadziyannis S. Fatal hepatic decompensation associated with interferon alfa. European concerted action on viral hepatitis (Eurohep). *BMJ.* 1993 Jan 9;306(6870):107-8.
52. Pugh RN, Murray-Lyon IM, Dawson JL, Pietroni MC, Williams R. Transection of the oesophagus for bleeding oesophageal varices. *Br J Surg.* 1973 Aug;60(8):646-9.
53. Marcellin P, Bonino F, Lau GKK, et al. The majority of patients with HBeAg-negative chronic hepatitis B treated with peginterferon alfa-2a (40KD) [Pegasys®] sustain responses 2 years post-treatment. *J Hepatol.* 2006;44(Suppl. 2):S275.
54. Di Bisceglie A, Lai CL, Gane E, et al. Telbivudine GLOBE trial: Maximal early HBV suppression is predictive of optimal two-year efficacy in nucleoside-treated hepatitis B patients. *Hepatology.* 2006;44(Suppl.1):230A-1A.
55. Dienstag JL, Schiff ER, Wright TL, et al. Lamivudine as initial treatment for chronic hepatitis B in the United States. *N Engl J Med.* 1999 Oct 21;341(17):1256-63.
56. Lai CL, Chien RN, Leung NW, et al. A one-year trial of lamivudine for chronic hepatitis B. Asia Hepatitis Lamivudine Study Group. *N Engl J Med.* 1998 Jul 9;339(2):61-8.
57. Leung NW, Lai CL, Chang TT, et al. Extended lamivudine treatment in patients with chronic hepatitis B enhances hepatitis B e antigen seroconversion rates: results after 3 years of therapy. *Hepatology.* 2001 Jun;33(6):1527-32.
58. Liaw YF, Leung NW, Chang TT, et al. Effects of extended lamivudine therapy in Asian patients with chronic hepatitis B. Asia Hepatitis Lamivudine Study Group. *Gastroenterology.* 2000 Jul;119(1):172-80.
59. Schalm SW, Heathcote J, Cianciara J, et al. Lamivudine and alpha interferon combination treatment of patients with chronic hepatitis B infection: a randomised trial. *Gut.* 2000 Apr;46(4):562-8.
60. Schiff ER, Dienstag JL, Karayalcin S, et al. Lamivudine and 24 weeks of lamivudine/interferon combination therapy for hepatitis B e antigen-positive chronic hepatitis B in interferon nonresponders. *J Hepatol.* 2003 Jun;38(6):818-26.
61. Chang TT, Lai CL, Chien RN, et al. Four years of lamivudine treatment in Chinese patients with chronic hepatitis B. *J Gastroenterol Hepatol.* 2004 Nov;19(11):1276-82.
62. Chang TT, Gish RG, de Man R, et al. A comparison of entecavir and lamivudine for HBeAg-positive chronic hepatitis B. *N Engl J Med.* 2006 Mar 9;354(10):1001-10.
63. Hadziyannis SJ, Papatheodoridis GV, Dimou E, Laras A, Papaioannou C. Efficacy of long-term lamivudine monotherapy in patients with hepatitis B e antigen-negative chronic hepatitis B. *Hepatology.* 2000 Oct;32(4 Pt 1):847-51.
64. Santantonio T, Mazzola M, Iacovazzi T, Miglietta A, Guastadisegni A, Pastore G. Long-term follow-up of patients with anti-HBe/HBV DNA-positive chronic hepatitis B treated for 12 months with lamivudine. *J Hepatol.* 2000 Feb;32(2):300-6.
65. Buti M, Cotrina M, Jardi R, et al. Two years of lamivudine therapy in anti-HBe-positive patients with chronic hepatitis B. *J Viral Hepat.* 2001 Jul;8(4):270-5.
66. Gaia S, Marzano A, Smedile A, et al. Four years of treatment with lamivudine: clinical and virological evaluations in HBe antigen-negative chronic hepatitis B. *Aliment Pharmacol Ther.* 2004 Aug 1;20(3):281-7.
67. Liaw YF, Sung JJ, Chow WC, et al. Lamivudine for patients with chronic hepatitis B and advanced liver disease. *N Engl J Med.* 2004 Oct 7;351(15):1521-31.
68. Tipples GA, Ma MM, Fischer KP, Bain VG, Kneteman NM, Tyrrell DL. Mutation in HBV RNA-dependent DNA polymerase confers resistance to lamivudine in vivo. *Hepatology.* 1996 Sep;24(3):714-7.
69. Lok AS, Lai CL, Leung N, et al. Long-term safety of lamivudine treatment in patients with chronic hepatitis B. *Gastroenterology.* 2003 Dec;125(6):1714-22.
70. Song BC, Suh DJ, Lee HC, Chung YH, Lee YS. Hepatitis B e antigen seroconversion after lamivudine therapy is not durable in patients with chronic hepatitis B in Korea. *Hepatology.* 2000 Oct;32(4 Pt 1):803-6.
71. Marcellin P, Chang TT, Lim SG, et al. Adefovir dipivoxil for the treatment of hepatitis B e antigen-positive chronic hepatitis B. *N Engl J Med.* 2003 Feb 27;348(9):808-16.
72. Marcellin P, Chang TT, Lim SG, Sievert W, Tong M, Xiong S. Long term efficacy and safety of adefovir dipivoxil (ADV) 10mg in HBeAg+ chronic hepatitis B patients: increasing serologic, virologic and biochemical response over time. *Hepatology.* 2004;40(Suppl.4):655A.
73. Hadziyannis SJ, Tassopoulos NC, Heathcote EJ, et al. Adefovir dipivoxil for the treatment of hepatitis B e antigen-negative chronic hepatitis B. *N Engl J Med.* 2003 Feb 27;348(9):800-7.
74. Hadziyannis S, Tassopoulos NC, Chang TT, et al. Long-term adefovir dipivoxil treatment induces regression of liver fibrosis in patients with HBeAg-negative chronic hepatitis B: Results after 5 years of therapy. *Hepatology.* 2005;42(Suppl.1):754A.
75. Hadziyannis SJ, Tassopoulos NC, Heathcote EJ, et al. Long-term therapy with adefovir dipivoxil for HBeAg-negative chronic hepatitis B. *N Engl J Med.* 2005 Jun 30;352(26):2673-81.
76. Fung SK, Chae HB, Fontana RJ, et al. Virologic response and resistance to adefovir in patients with chronic hepatitis B. *J Hepatol.* 2006 Feb;44(2):283-90.
77. Lee YS, Suh DJ, Lim YS, et al. Increased risk of adefovir resistance in patients with lamivudine-resistant chronic hepatitis B after 48 weeks of adefovir dipivoxil monotherapy. *Hepatology.* 2006 Jun;43(6):1385-91.
78. Bartholomeusz A, Locarnini SA, Ayres A, et al. Molecular modelling of hepatitis B virus polymerase and adefovir resistance identifies three clusters of mutations. *Hepatology.* 2004;40(Suppl):A165.
79. Chen CH, Wang JH, Lee CM, et al. Virological response and incidence of adefovir resistance in lamivudine-resistant patients treated with adefovir dipivoxil. *Antivir Ther.* 2006;11(6):771-8.
80. Yeon JE, Yoo W, Hong SP, et al. Resistance to adefovir dipivoxil in lamivudine resistant chronic hepatitis B patients treated with adefovir dipivoxil. *Gut.* 2006 Oct;55(10):1488-95.

81. Lai CL, Shouval D, Lok AS, et al. Entecavir versus lamivudine for patients with HBeAg-negative chronic hepatitis B. *N Engl J Med.* 2006 Mar 9;354(10):1011-20.
82. Sherman M, Yurdaydin C, Sollano J, et al. Entecavir for treatment of lamivudine-refractory, HBeAg-positive chronic hepatitis B. *Gastroenterology.* 2006 Jun;130(7):2039-49.
83. Chang TT, Chao YC, Kaymakoglu S, et al. Entecavir maintained virological suppression through 3 years of treatment in antiviral-naïve HBeAg(+) patients (ETV 022/901). *Hepatology.* 2006;44(Suppl.1):229A.
84. Shouval D, Akarca US, Hatzis G, et al. Continued virologic and biochemical improvement through 96 weeks of entecavir treatment in HBeAg(-) chronic hepatitis B patients (study ETV-027). *J Hepatol.* 2006;44(Suppl.2):S32-22.
85. Colonna RJ, Rose R, Baldick CJ, et al. Entecavir resistance is rare in nucleoside naïve patients with hepatitis B. *Hepatology.* 2006 Dec;44(6):1656-65.
86. Colonna RJ, Rose RE, Pokornowski K, et al. Four year assessment of ETV resistance in nucleoside-naïve and lamivudine refractory patients. *J Hepatol.* 2007;46(Suppl.1):S294.
87. Colonna RJ, Rose RE, Pokornowski K, Baldick CJ, Kleczewski K, Tenney D. Assessment at three years shows high barrier to resistance is maintained in entecavir-treated nucleoside naïve patients while resistance emergence increases over time in lamivudine refractory patients. *Hepatology.* 2006;44(Suppl.1):229A-30A.
88. Tenney DJ, Rose RE, Baldick CJ, et al. Two-year assessment of entecavir resistance in Lamivudine-refractory hepatitis B virus patients reveals different clinical outcomes depending on the resistance substitutions present. *Antimicrob Agents Chemother.* 2007 Mar;51(3):902-11.
89. Lai CL, Gane E, Liaw YF, et al. Telbivudine versus lamivudine in patients with chronic hepatitis B. *N Engl J Med.* 2007 Dec 20;357(25):2576-88.
90. Lai CL, Gane E, Hsu CW, et al. Two-year results from the GLOBE trial in patients with hepatitis B: greater clinical and antiviral efficacy for telbivudine (LdT) vs. lamivudine. *Hepatology.* 2006;44(Suppl.1):222A.
91. Poynard T, Chutaputti A, Hwang SG, et al. Sustained off-treatment HBeAg response in telbivudine and lamivudine treated HBeAg-positive patients from the GLOBE study. *J Hepatol.* 2007;46(Suppl.1):S27.
92. Dienstag JL, Cianciara J, Karayalcin S, et al. Durability of serologic response after lamivudine treatment of chronic hepatitis B. *Hepatology.* 2003 Apr;37(4):748-55.
93. Bonino F, Lau GKK, Marcellin P, et al. The first detailed analysis of predictors of response in HBeAg-negative chronic hepatitis B: data from a multicenter, randomized, partially double-blind study of peginterferon-alfa-2a (4-KD) (Pegasys®) alone or in combination with lamivudine vs lamivudine alone. *Hepatology.* 2004;40(S4):A1142.
94. Cooksley G, Lau GKK, Liaw YF, et al. Effects of genotype and other baseline factors on response to peginterferon alfa-2a (40 kDa) (Pegasys®) in HBeAg-positive chronic hepatitis B: results from a large, randomised study. *J Hepatol.* 2005;42(Suppl.2):S30.
95. Hadziyannis SJ, Papatheodoridis GV. Adefovir dipivoxil in the treatment of chronic hepatitis B virus infection. *Expert Rev Anti Infect Ther.* 2004 Aug;2(4):475-83.
96. Carr A, Miller J, Law M, Cooper DA. A syndrome of lipoatrophy, lactic acidemia and liver dysfunction associated with HIV nucleoside analogue therapy: contribution to protease inhibitor-related lipodystrophy syndrome. *Aids.* 2000 Feb 18;14(3):F25-32.
97. [Locarnini S, Hatzakis A, Heathcote J, et al. Management of antiviral resistance in patients with chronic hepatitis B. *Antivir Ther.* 2004 Oct;9(5):679-93.
98. Lampertico P, Vigano M, Manenti E, Iavarone M, Lunghi G, Colombo M. Adefovir rapidly suppresses hepatitis B in HBeAg-negative patients developing genotypic resistance to lamivudine. *Hepatology.* 2005 Dec;42(6):1414-9.
99. Lampertico P, Marzano A, Levrero M, et al. Adefovir and lamivudine combination therapy is superior to adefovir monotherapy for lamivudine-resistant patients with HBeAg-negative chronic hepatitis B. *Hepatology.* 2006;44(Suppl.1):693A-4A.
100. Fattovich G, Giustina G, Favarato S, Ruol A. A survey of adverse events in 11,241 patients with chronic viral hepatitis treated with alfa interferon. *J Hepatol.* 1996 Jan;24(1):38-47.
101. Fried MW. Side effects of therapy of hepatitis C and their management. *Hepatology.* 2002 Nov;36(5 Suppl 1):S237-44.
102. Manns MP, Wedemeyer H, Cornberg M. Treating viral hepatitis C: efficacy, side effects, and complications. *Gut.* 2006 Sep;55(9):1350-9.
103. Hoofnagle JH, Peters M, Mullen KD, et al. Randomized, controlled trial of recombinant human alpha-interferon in patients with chronic hepatitis B. *Gastroenterology.* 1988 Nov;95(5):1318-25.
104. Janssen HL, Gerken G, Carreno V, et al. Interferon alfa for chronic hepatitis B infection: increased efficacy of prolonged treatment. The European Concerted Action on Viral Hepatitis (EUROHEP). *Hepatology.* 1999 Jul;30(1):238-43.
105. Korenman J, Baker B, Waggoner J, Everhart JE, Di Bisceglie AM, Hoofnagle JH. Long-term remission of chronic hepatitis B after alpha-interferon therapy. *Ann Intern Med.* 1991;114(8):629-34.
106. Perrillo RP, Schiff ER, Davis GL, et al. A randomized, controlled trial of interferon alfa-2b alone and after prednisone withdrawal for the treatment of chronic hepatitis B. The Hepatitis Interventional Therapy Group. *N Engl J Med.* 1990 Aug 2;323(5):295-301.
107. Wong DK, Cheung AM, O'Rourke K, Naylor CD, Detsky AS, Heathcote J. Effect of alpha-interferon treatment in patients with hepatitis B e antigen-positive chronic hepatitis B. A meta-analysis. *Ann Intern Med.* 1993;119(4):312-23.
108. Krogsgaard K. The long-term effect of treatment with interferon-alpha 2a in chronic hepatitis B. The Long-Term Follow-up Investigator Group. The European Study Group on Viral Hepatitis (EUROHEP). Executive Team on Anti-Viral Treatment. *J Viral Hepat.* 1998;5(6):389-97.
109. Fattovich G, Farci P, Rugge M, et al. A randomized controlled trial of lymphoblastoid interferon-alpha in patients with chronic hepatitis B lacking HBeAg. *Hepatology.* 1992 Apr;15(4):584-9.
110. Hadziyannis S, Bramou T, Makris A, Moussoulis G, Zignego L, Papaioannou C. Interferon alfa-2b treatment of HBeAg negative/serum HBV DNA positive chronic active hepatitis type B. *J Hepatol.* 1990;11 Suppl 1:S133-6.
111. Lampertico P, Del Ninno E, Manzin A, et al. A randomized, controlled trial of a 24-month course of interferon alfa 2b in patients with chronic hepatitis B who had hepatitis B virus DNA without hepatitis B e antigen in serum. *Hepatology.* 1997 Dec;26(6):1621-5.
112. Lok AS, Heathcote EJ, Hoofnagle JH. Management of hepatitis B: 2000--summary of a workshop. *Gastroenterology.* 2001 Jun;120(7):1828-53.
113. Lok AS, Wu PC, Lai CL, et al. A controlled trial of interferon with or without prednisone priming for chronic hepatitis B. *Gastroenterology.* 1992 Jun;102(6):2091-7.
114. Manesis EK, Hadziyannis SJ. Interferon alpha treatment and retreatment of hepatitis B e antigen-negative chronic hepatitis B. *Gastroenterology.* 2001 Jul;121(1):101-9.
115. Pastore G, Santantonio T, Milella M, et al. Anti-HBe-positive chronic hepatitis B with HBV-DNA in the serum response to a 6-month course of lymphoblastoid interferon. *J Hepatol.* 1992 Mar;14(2-3):221-5.
116. Lai CL, Dienstag J, Schiff E, et al. Prevalence and clinical correlates of YMDD variants during lamivudine therapy for patients with chronic hepatitis B. *Clin Infect Dis.* 2003 Mar 15;36(6):687-96.
117. Moskovitz DN, Osiowy C, Giles E, Tomlinson G, Heathcote EJ. Response to long-term lamivudine treatment (up to 5 years) in patients with severe chronic hepatitis B, role of genotype and drug resistance. *J Viral Hepat.* 2005 Jul;12(4):398-404.
118. Chang TT, Gish RG, Hadziyannis SJ, et al. A dose-ranging study of the efficacy and tolerability of entecavir in Lamivudine-refractory chronic hepatitis B patients. *Gastroenterology.* 2005 Oct;129(4):1198-209.

Sudden onset of dorsal swelling of hands and feet

Y.-C. Chao¹, C.-Y. Ma², L.-H. Lin^{1*}

Departments of ¹Allergy, Immunology and Rheumatology, and ²Radiology, Buddhist Dalin Tzu Chi General Hospital, Chia-Yi County, Taiwan, *corresponding author: tel.: +886 5-264 80 00, fax: +886 5-264 80 06, e-mail: liping@tzuchi.com.tw

CASE REPORT

This 54-year-old man had a sudden onset of swelling of the dorsal hands and feet in November 2006. Two days later, he was seen by his family physician, who prescribed diclofenac (50 mg three times/day for six days). A few days after completing the treatment, the patient was admitted to our unit.

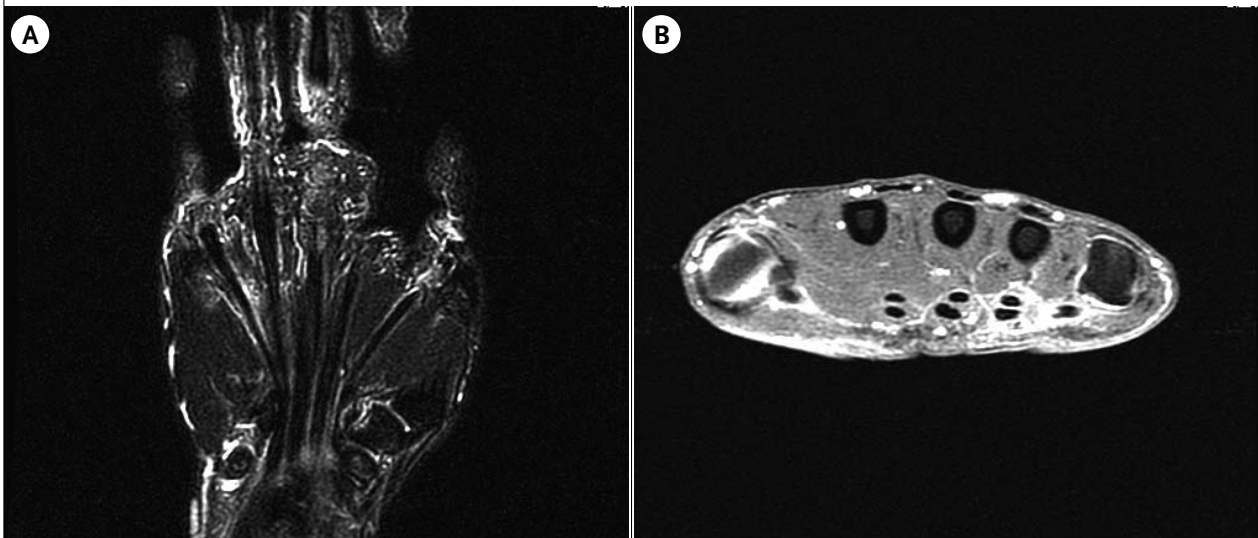
At physical examination, there was swelling of the wrists, ankles, dorsal hands and feet with pitting oedema. In particular, there were signs of diffuse, symmetrical and blanching discoloration followed by cyanosis of the extremities. No joint pain could be elicited. He complained of tingling or burning sensation in the muscles. His clinical history was unremarkable. Routine laboratory tests performed before the onset of the disease, in January 1997, were normal with an erythrocyte sedimentation rate of 49 mm/1st h (normal 2 to 6 mm/1st h) and C-reactive protein

7.3 mg/dl (normal <0.5 mg/dl). IgM rheumatoid factor, antinuclear antibodies, and a panel of antiviral antibodies were negative. X-rays of the hands and sacroiliac joints were normal. HLA phenotypes were HLA-DR4, HLA-DR11(5), HLA-B51(5) and HLA-B60(40) positive. Magnetic resonance imaging (MRI) of the hands is presented in figures 1A and 1B. Sequences included axial and coronal T1 and T2 weighted gradient echo and short inversion recovery (STIR). A whole-body bone scintigraphy with Tc-99m hydroxymethylene diphosphonate also showed symmetrically increased uptake in the joints of the extremities.

WHAT IS YOUR DIAGNOSIS?

See page 308 for the answer to this photo quiz.

Figure 1. A) Coronal T2WI (FSE 5067/95) of the right palm with fat suppression and B) Axial T1WI (FSE 450/8) of the right palm with fat suppression and intravenous administration of contrast medium



DIAGNOSIS

Coronal T2WI (FSE 5067/95) of the right palm with fat suppression revealed increased signal intensity of the synovial sheath of the 5th flexor tendon due to oedema (*figure 1A*). The contour and signal intensity of the flexor tendons appeared unchanged. Axial T1WI (FSE 450/8) with fat suppression and intravenous administration of contrast medium revealed increased enhancement of the synovial tissue around the 4th and 5th flexor tendons confirming synovitis (*figure 1B*).

An early diagnosis of remitting seronegative symmetrical synovitis with pitting oedema (RS3PE) with acute compartment syndrome was made and treatment with methylprednisolone 80 mg/day and nimesulide 100 mg twice daily was started. The signs and symptoms resolved completely after few days.

RS3PE is associated with various rheumatological and neoplastic diseases, typically in elderly men. An abrupt onset of pitting oedema of the dorsum of the hands associated with synovitis of the wrist carpus, small joints, and tendon sheaths have been reported as clinical feature, as in this case. Clinical examination usually suggests RS3PE, but the diagnostic gap between determination of RS3PE and clinical findings requires MRI imaging to establish the final diagnosis.¹ Although the RS3PE syndrome appeared to be a well-characterised entity, recent research has demonstrated that it can represent the inaugural form of various types of rheumatic diseases and paraneoplastic conditions in the elderly.²

The underlying pathogenic mechanism of RS3PE is still not completely clear. The association between HLA-A2, B7 CREG and seronegative spondyloarthropathies has already been mentioned.^{3,4} However, because of the presenting nature of HLA phenotypes in our case, we think that RS3PE was an ongoing inflammatory response of both spondyloarthropathy and rheumatoid arthritis or one of the ways in which late-onset polyarthritis and spondyloarthritis can present. However, this needs to be proven by further investigation.

In summary, although RS3PE is a rare disease, from the rheumatologist's perspective, we should always keep in mind that it is one of the possibilities presenting with polyarthritis in our daily clinical practice.

REFERENCES

1. Cantini F, Salvarani C, Olivieri I, et al. Remitting seronegative symmetrical synovitis with pitting oedema (RS3PE) syndrome: a prospective follow up and magnetic resonance imaging study. *Ann Rheum Dis* 1999;58:230-6.
2. Schaefferbeke T, Fatout E, Marce S, et al. Remitting seronegative symmetrical synovitis with pitting oedema: disease or syndrome? *Ann Rheum Dis* 1995;54:681-4.
3. Wendling D, Cedor JP, Viel JF. HLA B7 CREG and spondyloarthropathies. An epidemiological approach. *Arthritis Rheum* 1994;37:S355.
4. Woodrow JC. Genetic aspects of the spondyloarthropathies. *Clin Rheum Dis* 1985;11:1-24.

Binocular vertical double vision in a diabetic patient

D. Ilhan¹, S. Aydin², E. Gulcan^{3*}

Departments of ¹Neurology, ²Ophthalmology and ³Internal Medicine, Dumlupinar University Faculty of Medicine, Merkez Kampus Kutahya, Turkey, *corresponding author: e-mail: drerimgulcan@gmail.com

CASE REPORT

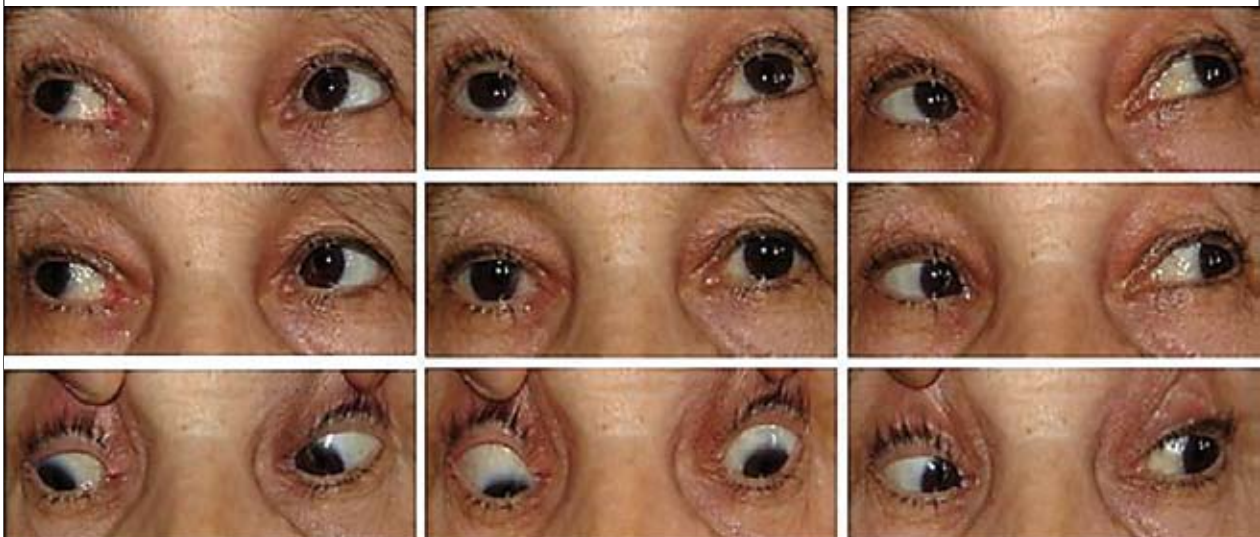A 73-year-old woman was admitted to our neurology department complaining of acute onset of binocular vertical double vision. She reported having diplopia for one week. She was not complaining of headache, nausea, or vomiting. She had no ocular history of trauma or ocular misalignment. The patient noticed a sudden onset of vertical diplopia, especially when she gazed in the lower-left direction. She did not have any other symptoms, and a neurological examination revealed no other findings. On examination, her visual acuity was 20/20 bilaterally. Pupil sizes and light reflexes were normal; there was no relative afferent

pupillary defect. Ptosis was absent in both eyes. Slit-lamp biomicroscopy, intraocular pressure measurements, and ophthalmoscopy were normal. There were no optic atrophy and optic disc oedema. Results of automated (Humphrey) visual field tests were normal. Extraocular motility examination was performed (*figure 1*).

WHAT IS YOUR DIAGNOSIS?

See page 310 for the answer to this photo quiz.

Figure 1. Extraocular movements in nine cardinal positions. Left downward eye movement is limited, left eye shows hypertropia and infraduction deficit



ANSWER TO PHOTO QUIZ (ON PAGE 309)

BINOCULAR VERTICAL DOUBLE VISION IN A DIABETIC PATIENT

DIAGNOSIS

The patient had a history of type 2 diabetes mellitus (DM), hypertension and hyperlipidaemia for five years. She had been on treatment with antihypertensive, antilipidaemic and oral hypoglycaemic agents and had poor glycaemic control. Fasting blood glucose was 16.7 mmol/l. Results of intravenous infusion of edrophonium (10 mg) and forced duction tests were negative. Computed tomography, magnetic resonance imaging (MRI) with and without contrast agents and diffusion MRI scans did not show any abnormalities, including the midbrain and the orbit. Also, MRI angiography did not reveal an aneurysm or arteriovenous malformation.

She was discharged after normalisation of blood glucose concentrations. Over the next one month, the patient's diplopia resolved completely and there was no residual ophthalmoplegia (*figure 2*).

In the light of these data, the diagnosis was considered to be isolated inferior rectus muscle (IRM) palsy. The differential diagnosis of an isolated IRM palsy includes orbital lesion (orbital pseudotumour, tumour, traumatic or postsurgical restrictive disease, thyroid ophthalmopathy), neuromuscular junction lesion (myasthenia gravis), multiple sclerosis, congenital, partial third nerve palsy and idiopathic causes.^{1,2} The cause of most IRM palsies is believed to be microvascular ischaemia, frequently associated with DM or systemic hypertension. Microvascular third nerve palsies

are frequently quite painful but usually resolve after two to four months.^{3,4}

Other reasons for the IRM palsy were excluded. In the differential diagnosis, we suspected that vascular ischaemic lesion related to DM was causing this clinic manifestation. Improvement in the patient's clinical condition after the regulation of blood glucose supported our diagnosis.

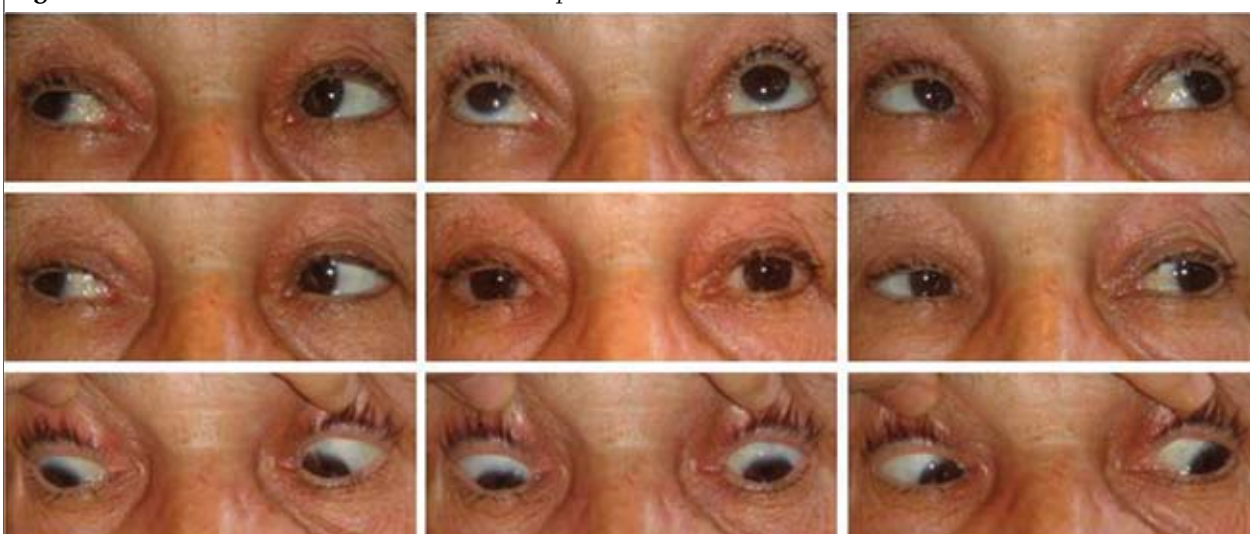CONCLUSION

The diagnosis is isolated IRM palsy from microvascular ischaemia involving the oculomotor nucleus caused by type 2 DM.

REFERENCES

1. Lee AG, Tang RA, Wong GG, et al. Isolated inferior rectus muscle palsy resulting from a nuclear third nerve lesion as the initial manifestation of multiple sclerosis. *J Neuroophthalmol* 2000;20:246-7.
2. Takano M, Aoki K. Midbrain infarction presenting isolated inferior rectus nuclear palsy. *Rinsho Shinkeigaku* 2000;40:832-5.
3. Bortolami R, D'Alessandro R, Mani E. The origin of pain in 'ischemic-diabetic' third-nerve palsy. *Arch Neurol* 1993;50:795.
4. Lee DK, Kim JS. Isolated inferior rectus palsy due to midbrain infarction detected by diffusion-weighted MRI. *Neurology* 2006;66:1956-7.

Figure 2. Extraocular movements in nine cardinal positions



Improvement of patient's clinical condition after the regulation of blood glucose. There is no limitation in any gaze direction.

Treatment of chronic hepatitis C virus infection – Dutch national guidelines

J. de Bruijne¹, E.H.C.J. Buster², H.C. Gelderblom¹, J.T. Brouwer³, R.J. de Knecht², K.J. van Erpecum⁴, S.W. Schalm², C.M. Bakker⁵, H.L. Zaaijer⁶, H.L.A. Janssen², H.W. Reesink^{1*}, for the Netherlands Association of Gastroenterologists and Hepatologists

Departments of ¹Gastroenterology and Hepatology, and ⁶Clinical Virology, Academic Medical Centre Amsterdam, the Netherlands, ²Department of Gastroenterology and Hepatology, Erasmus MC, University Medical Centre Rotterdam, the Netherlands, ³Department of Internal Medicine, Gastroenterology and Hepatology, Reinier de Graaf Group, Delft, the Netherlands, ⁴Department of Gastroenterology and Hepatology, University Medical Centre Utrecht, the Netherlands, ⁵Department of Gastroenterology and Hepatology, Atrium Medical Centre, Heerlen, the Netherlands, *corresponding author: tel.: +31 (0)20-566 47 02, fax: +31 (0)20-566 95 82, e-mail: h.w.reesink@amc.nl

ABSTRACT

The development of this guideline was initiated and coordinated by the Netherlands Association of Gastroenterologists and Hepatologists (Nederlandse Vereniging van Maag-Darm-Leverartsen). The aim is the establishment of practical guidelines in the evaluation and antiviral treatment of patients with chronic hepatitis C virus (HCV) infection. This includes recommendations for the initial evaluation of patients, the choice and duration of antiviral therapy and the follow-up after antiviral therapy. Hepatitis C is a slowly progressive disease. The initial evaluation of chronically HCV-infected patients should include liver biochemistry testing, virological testing and abdominal ultrasound imaging. Liver biopsy is no longer a routine procedure.

Antiviral treatment should be considered for all HCV-infected patients. Current antiviral treatment is a long-term process and is associated with substantial side effects. When deciding whether to start treatment or not, the chance of successful treatment (80% with hepatitis C genotype 2 and 3 and 50% with hepatitis C genotype 1 and 4), the fibrosis stage, the expected side effects and the compliance of the patient should be taken into consideration. In the absence of significant fibrosis and necroinflammation in liver biopsy, postponing treatment is an option. Current antiviral treatment is contraindicated in patients with Child-Pugh-class B or C cirrhosis. The possibility of a liver transplantation should be investigated in these patients. Significant comorbidity with a limited life expectancy is an absolute contraindication for antiviral treatment.

Treatment of chronic hepatitis C consists of administration of peginterferon and ribavirin for 24 or 48 weeks. Patients with hepatitis C genotype 1 or 4 are treated for 48 weeks. Patients with hepatitis C genotype 2 or 3 are treated for 24 weeks. In patients with undetectable HCV RNA after four weeks (28 days) of treatment, a shorter treatment is equally effective (12 to 16 weeks for hepatitis C genotype 2 or 3; 24 weeks for hepatitis C genotype 1 or 4). Outpatient clinic visits are recommended at the start and after 2, 4, 8, and 12 weeks of treatment, and thereafter every four to six weeks until the end of treatment. It is recommended to stop treatment if the HCV RNA level has not decreased by at least 2 log₁₀ IU/ml (c/ml) after 12 weeks of treatment or when HCV RNA is still detectable after 24 weeks of treatment.

The recommended frequency of outpatient clinic visits for patients who are not being treated is once every six months in patients with cirrhosis, otherwise every 12 months.

It is expected that new anti-HCV-medication (STAT-C, specifically targeted antiviral therapy for HCV) will become available in the near future. Therefore treatment of chronic HCV infection will probably be more effective in the future.

INTRODUCTION

Over 130 million people suffer from chronic hepatitis C virus infection (HCV infection) worldwide.^{1,3} In the Netherlands the number of people with chronic HCV infection is estimated to be 60,000.⁴ (Estimated

seroprevalence of anti-HCV in the Netherlands is 0.5%, 75% of the people with anti-HCV are viraemic). HCV is an RNA virus that belongs to the family of the *Flaviviridae*. The main route of transmission is parenteral via contaminated blood (blood transfusion, re-use of inadequately sterilised instruments, intravenous drug use). Sexual transmission is rare. Six HCV genotypes exist, of which the genotypes 1, 2, 3 and 4 are prevalent in the Netherlands. Hepatitis C is a slowly progressive disease which initially causes no or few symptoms in most HCV-infected patients. Approximately 10 to 20% of HCV-infected patients develop cirrhosis over a period of 10 to 30 years. Per year, 1 to 5% of patients with cirrhosis develop hepatocellular carcinoma (HCC). Cirrhosis and HCC as a result of chronic HCV infection are currently the major indications for liver transplantation in Europe and the United States.⁵ Liver transplantation is an effective treatment for decompensated cirrhosis (Child-Pugh class B or C) and for small HCCs.⁶ However, the transplanted donor liver will be re-infected with HCV. As a result 10 to 41% of the patients will develop cirrhosis of the donor liver after five to ten years.^{5,7}

No vaccine or immunoglobulin is available for the prevention of HCV infection. The main groups at risk for HCV infection are persons who have ever used intravenous drugs, recipients of blood or blood products before 1992 and immigrants from high endemic areas. Chronic HCV infection can be treated with combination therapy consisting of peginterferon- α (a cytokine) and ribavirin (a nucleoside analogue) for 24 to 48 weeks. The duration of the treatment depends on the HCV genotype, the quantity of HCV in plasma at the start of treatment and the viral decline during treatment.

Multiple consensus guidelines for the treatment of chronic hepatitis C have been published in the last few years.^{8,9} A committee was convened by the Netherlands Association of Gastroenterologists and Hepatologists (Nederlandse Vereniging van Maag-Darm-Leverartsen) to formulate a consensus-based guideline for the treatment of chronic HCV infection. The guideline provides recommendations on the initial evaluation of chronically HCV-infected adults, choice of the (initial) antiviral therapy and the follow-up during and after antiviral therapy. Management of patients with co-infection of hepatitis B virus (HBV) and hepatitis C virus (HCV) or human immunodeficiency virus (HIV) will not be discussed in this guideline. This guideline will only discuss the treatment with pegylated interferon- α and ribavirin. The level of recommendation was determined according to the Dutch Institute for Quality of Healthcare (CBO) (http://www.cbo.nl/product/richtlijnen/handleiding_ebro/article20060207153532) (tables 1A and 1B).

Table 1A. *Quality of studies on which a recommendation is based*

Grade	Definition
A1	Systematic review of at least two independent studies of A2 level
A2	Randomised double-blind controlled study of adequate quality and size
B	Comparative study not fulfilling the characteristics of A2 level studies (including case-control studies and cohort studies)
C	Noncomparative studies
D	Expert opinion

Table 1B. *Quality of evidence on which a recommendation is based*

Grade	Definition
I	Study of level A1 or at least two independent studies of level A2
II	Single level A2 study or at least two independent level B studies
III	Single level B or C study
IV	Expert opinion

NATURAL HISTORY

Acute hepatitis C virus infection is rarely observed. The course of HCV infection is usually asymptomatic,¹⁰⁻¹² fulminant hepatitis is rare.¹³ HCV RNA is first detectable seven to ten days after exposure,^{14,15} HCV-specific antibodies are detectable after 49 to 70 days.^{16,17} About 75% of HCV-infected patients develop chronic infection and in 25% the infection resolves spontaneously.¹⁸⁻²¹ In patients with a suspected acute HCV infection (for example after needlestick injury with an HCV RNA-positive source) it is recommended to determine the HCV RNA load regularly and to start treatment if viraemia develops within 12 weeks after exposure.^{10,22} Studies have shown that the chance of achieving a sustained viral response is 90 to 100% after treatment with interferon or peginterferon monotherapy for 24 weeks, independent of the genotype.^{10,22}

Chronic HCV infection is defined by the presence of HCV RNA for more than six months. The grade of hepatitis can vary from minimal inflammation to serious inflammatory activity with fibrosis or cirrhosis. The course of the infection is independent of the level of the enzyme alanine aminotransferase (ALAT) in plasma. Fibrosis and cirrhosis can emerge despite normal levels of ALAT. After 10 to 30 years, 10 to 20% of the patients develop cirrhosis. Progression of the disease is slower in females and in those who are young at the time of infection, but faster in patients with a high inflammatory activity, alcohol consumption, or co-infection with HBV or HIV.²³ In patients with cirrhosis, the incidence of HCC is 1 to 5% per year. Death of patients with chronic HCV infection and

cirrhosis can occur due to decompensation of the cirrhosis or to development of HCC.^{2,3,24-26} The incidence of HCC and the mortality due to HCV will probably increase in the coming decades.^{27,28}

Cohort studies (retrospective – prospective) show that after 25 to 35 years, 5 to 12% of the infected patients will develop decompensated cirrhosis or HCC.²⁹⁻³¹ Few studies have investigated the natural course of chronic HCV infection.^{25,26,32} Studying the natural course of chronic HCV infection is difficult because the majority of hepatitis C infected patients have not yet been identified. Many HCV-infected individuals are unaware of their infectious status and do not have symptoms. Chronic HCV infection is a disease with nonspecific symptoms, such as fatigue. It often is diagnosed accidentally. Some extrahepatic manifestations, such as lichen planus, Sjögren's syndrome and vasculitis on the basis of cryoglobulinaemia are associated with chronic HCV infection.^{33,34}

It is not clear whether the route of transmission influences the course of disease. Among young intravenous drug users with chronic HCV infection the mortality rate is higher due to complications related to the intravenous drug use as compared with liver disease related to the hepatitis C virus infection.³⁵

Although death as a result of end-stage liver disease due to chronic HCV infection occurs in probably less than 30% of all HCV-infected patients,³⁶ the worldwide epidemic leads to a mortality rate of approximately 350,000 deaths per year. This number will probably increase in the coming years.³⁷

INITIAL EVALUATION

The initial evaluation of patients with chronic HCV infection should include a detailed history, with special emphasis on risk factors for blood-borne infectious diseases and alcohol abuse. Physical examination should focus on signs of chronic liver disease and cirrhosis (palmar erythema, spider nevi, gynaecomastia, flapping tremor and testicular atrophy), portal hypertension (ascites, splenomegaly, caput medusae) and liver failure (jaundice and hepatic encephalopathy).

Laboratory tests should include assessment of liver enzymes (aminotransferases), liver function tests (albumin, bilirubin and prothrombin time), full blood cell count and kidney function tests. The replication status (quantitative HCV RNA) and the HCV genotype should be determined when antiviral treatment is considered. In addition, the patient must be tested for HBV or HIV co-infection. Abdominal ultrasound should be performed in all patients, with special emphasis on signs of cirrhosis (irregular liver surface, blunt liver edge and narrowed hepatic veins), portal hypertension (diminished portal flow, splenomegaly, venous collaterals and ascites) and focal liver lesions.

Liver biopsy does not have to be routinely performed in all HCV-infected patients. A liver biopsy could be considered for assessing the need for antiviral treatment, to assess baseline necroinflammatory activity and fibrosis stage (table 2). In patients with genotype 2 or 3, with successful treatment rates of 80% or more, liver biopsy often has no added value.

Table 2. Recommendations for the management of chronic hepatitis C based on fibrosis stage and presence of (decompensated) cirrhosis

Fibrosis/cirrhosis	Recommended management
None	Antiviral therapy is not strictly indicated, yearly monitoring
Moderate	Antiviral therapy is indicated
Compensated cirrhosis	Antiviral therapy is indicated, 6-monthly monitoring
Decompensated cirrhosis	Liver transplantation indication, monitor more than twice a year

Specific tests prior to treatment should include autoantibodies (antinuclear antibodies, ANA) and thyroid stimulating hormone. A chest X-ray (in case of pulmonary symptoms, older age, to rule out sarcoidosis and tuberculosis) and an electrocardiogram (ECG) (in case of cardiac symptoms, older age) should be performed on indication (table 3). Patients with diabetes mellitus or pre-existing eye disease should undergo fundoscopy. A pregnancy test should be carried out in fertile females. Females should not become pregnant during ribavirin treatment or within four months after ribavirin treatment has been stopped.³⁸⁻⁴¹ Males should not cause pregnancy during ribavirin treatment or within seven months after ribavirin treatment has been stopped.³⁸⁻⁴¹ Due to the long half-life of ribavirin it takes eight to ten weeks before ribavirin is eliminated from the body. If pregnancy occurs during or just after ribavirin treatment is stopped, the possibilities of side effects on the foetus should be discussed; however it should be noted that the risk of foetal abnormalities is regarded to be small. In the literature pregnancies have been described during or just after the use of ribavirin; none of these pregnancies have led to congenital disorders.⁴²⁻⁴⁶ The outcomes of such pregnancies are registered (www.ribavirinpregnancyregistry.com) in an international database. As a precaution, the American Food and Drug Administration (FDA) classified ribavirin in the FDA Pregnancy category X.⁴⁷ Surveillance for HCC, by abdominal ultrasound every six to 12 months, is recommended for all chronically HCV-infected patients with cirrhosis.^{48,49} Screening for HCC results in the detection of HCC in an earlier stage and is associated with better survival rates.⁵⁰ Routine measurement of α -fetoprotein is not useful as this does not improve the efficacy of screening and leads to an increase in false-positive findings.⁴⁸ In patients with cirrhosis,

Table 3. Recommendations for minimal laboratory testing prior to, at start and during antiviral therapy with peginterferon and ribavirin

	Prior	At start	W1	W2	W4	W8	W12	W16	W20	W24	W28	W32	W36	W40	W44	W48
Routine laboratory	X	X	X	X	X	X	X	X	X	X	X	X	X	X	X	X
Screening	X															
Endocrinology	X						X			X			X			X
Level of HCV RNA		X			X		X			X						X
Radiology	X															X
ECG	X															
Pregnancy test	X															
Routine laboratory	Haemoglobin, leucocytes with differential WBC, thrombocytes, ALAT, ASAT, alkaline phosphatase, gamma-GT, LDH, glucose, HbA _{1c} if glucose is elevated (routine assessment of glucose and leucocyte differentiation only during treatment)															
Screening	PT, APT, AT III, albumin, creatinine, antinuclear antibodies, HBsAg, anti-HBs, anti-HBc, anti-HIV															
Endocrinology	TSH, and when elevated FT ₄															
Level of HCV RNA	HCV RNA-concentration quantitative and/or qualitative															
Quantitative	Prior to treatment, preferably just before the first peginterferon injection and at week 4 and week 12															
Qualitative	After 4, 12, 24 en 48 weeks of treatment, and 24 weeks after stopping treatment															
Radiology	Abdominal ultrasound of liver and spleen, including Doppler ultrasound test, chest X-ray on indication															
ECG	On indication															
Pregnancy test	Only in females in the age of procreation															

upper gastrointestinal endoscopy should be considered to confirm or exclude the presence of oesophageal varices.

Hepatitis A virus (HAV) immunity should be established in all patients with chronic hepatitis C, since the risk of a fulminant course of acute HAV infection is increased as compared with healthy controls.⁵¹ Despite the fact that the actual risk of fulminant HAV infection is low, HAV vaccination is recommended for all chronically HCV-infected patients not immune to HAV infection.

Co-infection with HBV can accelerate the progression of chronic HCV infection.⁵² Therefore, HBV vaccination is recommended in all patients with chronic HCV infection without protective HBV immunity.^{8,51,52}

Recommendations	
The initial evaluation of chronically HCV-infected patients should include a detailed history and physical examination. Blood chemistry, full blood cell count, virus serology (including determination of the HCV genotype and quantification of plasma HCV RNA) and abdominal ultrasound should also be performed.	Level 4
Surveillance for hepatocellular carcinoma by abdominal ultrasound every 6 to 12 months is recommended in patients with cirrhosis.	Level 3
Hepatitis A vaccination is recommended in all chronically infected hepatitis C patients without hepatitis A immunity because of the increased risk of developing fulminant acute hepatitis A virus infection.	Level 1
Co-infection with hepatitis B virus can accelerate the disease progression. Therefore, hepatitis B vaccination is recommended in all chronically HCV-infected patients without protective immunity to hepatitis B.	Level 1

INDICATIONS AND CONTRAINDICATIONS FOR ANTIVIRAL THERAPY

Antiviral treatment should be considered in all chronically HCV-infected patients. Current antiviral treatment is a long-term process and is accompanied with a number of side effects. When deciding whether or not to start treatment, the chance of successful treatment (80% with hepatitis C genotype 2 and 3 after 12 to 24 weeks treatment, 50% with hepatitis C genotype 1 and 4 after 24 to 48 weeks treatment), the fibrosis stage, the expected side effects and the motivation of the patient should be taken into consideration. In the absence of fibrosis and inflammation in the liver biopsy, postponing treatment can be considered.

Contraindications for antiviral treatment are the presence of Child-Pugh-class B or C cirrhosis or significant comorbidity (severe cardiac disease, chronic obstructive pulmonary disease (COPD), systemic lupus erythematosus (SLE), other autoimmune diseases or severe psychiatric disorders). Relative contraindications are age of 70 years or above, mild comorbidity and various social factors. In patients with pre-existing comorbidity such as depression, COPD, psoriasis, diabetes mellitus, one should be alert for exacerbations of these diseases during antiviral therapy. It is recommended to consult other specialists (psychiatrist, pulmonologist, dermatologist, internist, ophthalmologist) before starting antiviral therapy and take precautionary measures if necessary (for example to start treatment with a selective serotonin reuptake inhibitor (SSRI) in a patient with a history of depression).⁵³ When relative contraindications are present, the stage of the liver

disease, the HCV genotype and the chance of achieving a sustained viral response (SVR), the expected duration of antiviral therapy and other factors associated with response have to be taken into account as well. Important factors predisposing for nonresponse are age above 40 years, male gender, negroid race,^{54,55} obesity⁵⁶ and high γ -GT levels.^{57,58} If the indications for treatment are not clear or contraindications exist, it is recommended to consult an expertise centre.

Recommendations	
Antiviral treatment should be considered in all chronically HCV-infected patients.	Level 4
Considering whether or not to start treatment, the chance of successful treatment (80% with hepatitis C genotype 2 and 3 after 12 to 24 weeks treatment, 50% with hepatitis C genotype 1 and 4 after 24 to 48 weeks treatment), the fibrosis stage, the expected side effects and the compliance of the patient should be taken into account. In the absence of fibrosis and inflammation in the liver biopsy, postponing antiviral treatment can be considered.	Level 1

MONITORING PATIENTS NOT REQUIRING ANTIVIRAL THERAPY

Patients without indication for antiviral therapy, patients with contraindications for antiviral therapy (COPD, diabetes mellitus with organ injury, etc), patients who do not want to be treated and patients who did not achieve an SVR after antiviral therapy (nonresponse, breakthrough, relapse) should be monitored by a hepatologist. These patients should be monitored yearly for routine assessment of blood tests (ALAT, ASAT, albumin, bilirubin, PT, full blood cell count). Abdominal ultrasound should be considered every three to five years. Patients with cirrhosis should be monitored every six months, including abdominal ultrasound.

Nonresponders, relapsers, patients with breakthrough and other difficult to treat patients

Approximately 20% (genotype 2 and 3) to 50% (genotype 1 and 4) of patients do not respond to current standard peginterferon and ribavirin therapy. Three types of non-SVR can be distinguished: nonresponse, breakthrough and relapse (table 4). The most important viral factor associated with non-SVR is genotype 1 or 4. A number of studies showed that an initial high viral load is associated with a lower chance of achieving an SVR.⁹ The SVR rate after retreatment with standard therapy is usually low (less than 25%). Retreatment of non-SVR patients should preferentially be done in an investigational setting. Patients with non-SVR after IFN monotherapy have a slightly higher chance of achieving an SVR after retreatment with

Table 4. Antiviral therapy outcomes

Treatment outcome	HCV RNA
SVR	Undetectable HCV RNA with qualitative PCR-test 24 weeks after end of antiviral therapy
Non-SVR	Nonresponse
	Breakthrough
	Relapse
	Detectable HCV RNA with qualitative PCR-test during and at end of antiviral therapy Detectable HCV RNA at any time during treatment after previous undetectable HCV RNA with qualitative PCR-test during antiviral therapy Undetectable HCV RNA with qualitative PCR-test at end of treatment, but detectable 24 weeks after stopping antiviral therapy

SVR = sustained viral response.

peginterferon and ribavirin as compared with retreatment of patients with non-SVR after combination therapy with peginterferon and ribavirin. Also patients with extensive comorbidity, such as end-stage kidney failure with or without haemodialysis, status after transplantation, autoimmune disease (SLE) are considered difficult to treat. Patients with non-SVR and other difficult to treat patients can be referred to an expertise centre for retreatment, preferably in an investigational setting.

Recommendation	
Every chronically HCV-infected patient not receiving antiviral therapy should be monitored at least once yearly for the routine assessment of blood tests. Patients with cirrhosis should be monitored every 6 months.	Level 4

ANTIVIRAL THERAPY

The current standard antiviral therapy for chronic HCV infection consists of administration of peginterferon and ribavirin for 24 or 48 weeks.⁵⁹⁻⁶² Peginterferon is administered subcutaneously once a week and ribavirin should be taken orally twice daily. The goal of antiviral therapy is to achieve an SVR, thereby resolving liver inflammation and the progression to cirrhosis and HCC.⁶³

In patients with genotype 1, treatment with peginterferon and ribavirin results in an SVR in 41 to 52% of the patients after 48 weeks of treatment^{59-61,64} and in patients with genotype 4 in 77%.⁵⁹ In patients with genotype 1, the SVR rate after a shorter treatment of 24 weeks is diminished to 29 to 42%.^{60,64} In patients with genotype 2 and 3, treatment for 24 weeks (79 to 93%) results in an equal SVR rate as compared with 48 weeks of treatment (76 to 88%).^{59-61,64,65} The duration of antiviral therapy is dependent on the genotype and the

Table 5. Recommendations for evaluation of the viral response during treatment

Time point	Response	HCV RNA	Clinical meaning
Week 4	Rapid viral response (RVR)	Undetectable with qualitative PCR-test	RVR results in a better chance of an SVR, possibility of shorter treatment
Week 12	Early viral response (EVR)	> 2 log ₁₀ IU/ml (c/ml) decline compared with start of therapy	If EVR is not achieved, the chance of an SVR is nil, stop treatment

HCV RNA load at the start of therapy and during treatment (table 5).^{8,62,66} Antiviral therapy with peginterferon and ribavirin is costly and most patients suffer from significant side effects (table 6).^{9,67,68}

There are two types of peginterferon, which have comparable efficacy in clinical practice. The dose of peginterferon- α -2b is weight-based: 1.5 μ g/kg/week, the dose of peginterferon- α -2a is always 180 μ g/week.⁶⁹ Recent studies suggest that weight-based dosing of ribavirin is associated with a higher chance of achieving an SVR.^{70,71} However, these studies were performed exclusively with peginterferon α -2b.

Antiviral therapy of HCV genotype 1

The treatment of HCV genotype 1 consists of the administration of peginterferon- α -2a 180 μ g/week in combination with 800 mg ribavirin daily or peginterferon- α -2b at a weekly dose of 1.5 μ g/kg in combination with weight-based ribavirin (800 mg from \leq 65 kg, 1000 mg from 65 to 85 kg, 1200 mg from 85 to 105 kg and 1400 mg from \geq 105 kg) (tables 7 and 8). The duration of antiviral therapy is 48 weeks. After 12 weeks of antiviral therapy HCV RNA should be tested to determine the viral response. If the HCV RNA level after 12 weeks has decreased less than 2 log₁₀ IU/ml (c/ml) (99%) compared with the pretreatment HCV RNA level, it is advised to stop treatment because an SVR will rarely occur (figure 1A).

Table 6. Side effects during treatment with peginterferon and ribavirin^{22,67,68}

Frequency	Peginterferon	Ribavirin
>30% (very frequent)	Flu-like symptoms Headache Fatigue Pyrexia Chills Myalgia Thrombocytopenia Induction of autoantibodies	Haemolysis Nausea
1-30% (frequent)	Anorexia Erythema at injection site Insomnia Alopecia Lack of motivation Lack of concentration Irritability, agitation Emotional instability Depression Diarrhoea Autoimmune disease (thyroiditis, Sjögren's disease) Neutropenia Change of taste	Anaemia Obstructed nose Pruritus Diarrhoea Eczema
<1% (rare)	Polynuropathy Paranoia of suicidal ideation Diabetes mellitus Retinopathy Optic neuritis Hearing loss Seizures Loss of libido Cardiotoxicity	Gout Interstitial pneumonia

Table 7. Recommendations given by the manufacturer for dosing and duration of combination therapy with peginterferon-alpha-2a and ribavirin^{38,39}

HCV genotype	RVR	HCV RNA at start of therapy	Peginterferon-alpha-2a (weekly)	Weight (kg)	Ribavirin (daily)	Treatment duration (weeks)
Genotype 1	Yes	\leq 600,000 IU/ml	180 μ g	<75 kg \geq 75 kg	1000 1200	24 or 48
			180 μ g	<75 kg \geq 75 kg	1000 1200	48
	No	-	180 μ g	<75 kg \geq 75 kg	1000 1200	48
			180 μ g	<75 kg \geq 75 kg	800 mg [*]	24
Genotype 2 or 3	-	-	180 μ g			24
Genotype 4	Yes	-	180 μ g	<75 kg \geq 75 kg	1000 1200	24 or 48
			180 μ g	<75 kg \geq 75 kg	1000 1200	48

RVR = rapid viral response (HCV RNA \leq 50 IU/ml after 4 weeks). *Retrospective studies with peginterferon-alpha-2b show higher SVR rates with weight-based dosing of ribavirin in patients with genotype 2 or 3.^{70,71}

Table 8. Recommendations given by the manufacturer for dosing and duration of combination therapy with peginterferon- α -2a and ribavirin^{46,47}

HCV genotype	RVR	HCV RNA at start of therapy	Peginterferon- α -2b (weekly)	Weight (kg)	Ribavirin (mg/day)	Treatment duration (weeks)
Genotype 1	Yes	$\leq 600,000$ IU/ml	1.5 μ g/kg	<65	800	24 or 48
				65-85	1000	
				>85	1200	
	No	>600,000 IU/ml	1.5 μ g/kg	<65	800	48
				65-85	1000	
				>85	1200	
Genotype 2 or 3	-	-	1.5 μ g/kg	<65	800	24
				65-85	1000	
				>85	1200	
Genotype 4	Yes	-	1.5 μ g/kg	<65	800	24 or 48
				65-85	1000	
				>85	1200	
	No	-	1.5 μ g/kg	<65	800	48
				65-85	1000	
				>85	1200	

RVR = rapid viral response (HCV RNA ≤ 50 IU/ml at week 4); EVR = early viral response (HCV RNA 2 \log_{10} IU/ml (copies/ml 99%) decline at week 12).

Shortened antiviral treatment of HCV genotype 1

In patients with HCV RNA load less than 600,000 IU/ml at the start of treatment, who have an undetectable HCV RNA load with a qualitative PCR test at week 4 (rapid viral response, RVR), a shorter treatment of 24 weeks is as effective as a treatment of 48 weeks (figure 1A).^{64,72,73}

Antiviral therapy of HCV genotype 2 and 3

The treatment of HCV genotype 2 and 3 consists of the administration of peginterferon- α -2a 180 μ g/week in combination with 800 mg ribavirin daily or peginterferon- α -2b at a weekly dose of 1.5 μ g/kg in combination with weight-based ribavirin (tables 7 and 8). The duration of antiviral therapy is 24 weeks.

Shortened antiviral treatment of HCV genotype 2 and 3

Three randomised trials and one nonrandomised trial have shown that patients with genotype 2 and 3 with undetectable HCV RNA, by qualitative PCR after four weeks (RVR), can stop antiviral treatment after 12 to 16 weeks (figure 1C).⁷⁴⁻⁸³ Of all patients with genotype 2 and 3, 63 to 78% achieve an RVR and can receive a shorter treatment of 12 to 16 weeks, resulting in SVR rates of 71 to 100%.⁷⁴⁻⁸³ One study testing shorter treatment found a slightly higher relapse rate (statistically not significant).⁷⁷ However, for most patients with an RVR, 12 weeks of treatment turned out to be sufficient and nine out of ten patients with a relapse achieved an SVR after retreatment for 24 weeks.⁷⁷ The two other randomised trials showed no difference between the relapse rate after 16 or 24 weeks of treatment.^{74,82} In all published trials investigating 12 to 16 weeks of treatment, weight-based ribavirin dosing (1000 to 1200 mg/day) was used.⁷⁴⁻⁸³

Shorter treatment in patients with genotype 2 and 3 with an RVR is not yet registered, but is recommended internationally.^{9,22,84} In practice, this means that a shorter treatment can be considered in patients with an RVR who suffer from significant side effects.

Antiviral therapy of HCV genotype 4

The treatment of HCV genotype 4 consists of the administration of peginterferon- α -2a 180 μ g/week in combination with 800 mg ribavirin daily or peginterferon- α -2b at a weekly dose of 1.5 μ g/kg in combination with weight-based ribavirin (tables 7 and 8). The duration of antiviral therapy is 48 weeks. After 12 weeks of antiviral therapy HCV RNA should be tested to determine the viral response. If the HCV RNA level at week 12 has decreased by less than 2 \log_{10} IU/ml (c/ml) (99%) compared with the pretreatment HCV RNA level, it is advised to stop treatment because an SVR will rarely occur (figure 1B). After 24 weeks of antiviral therapy HCV RNA should be tested again: if HCV RNA is detectable it is advised to stop treatment because achieving an SVR is rare (figure 1B).

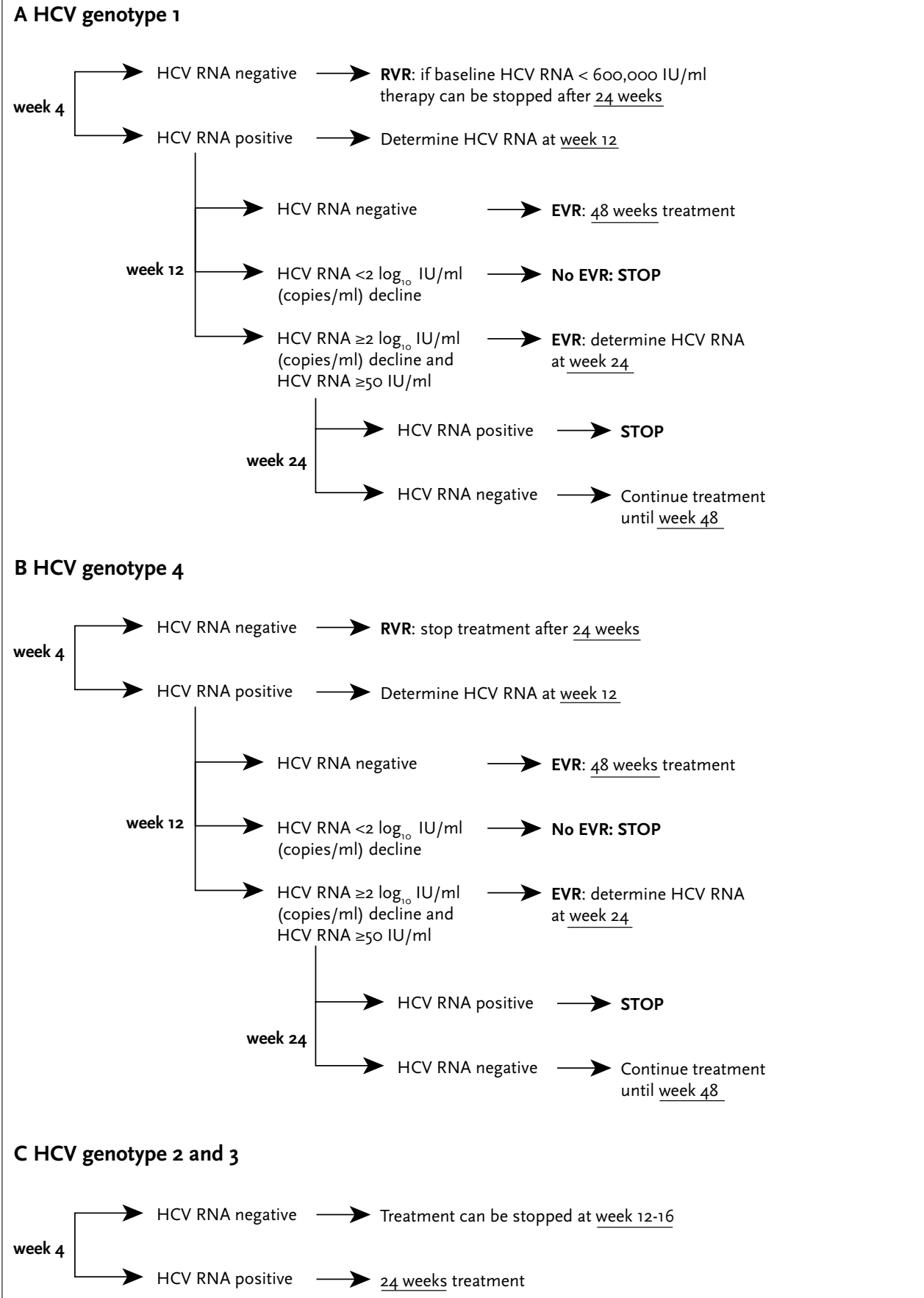
Shortened antiviral treatment of HCV genotype 4

In patients who have undetectable HCV RNA by qualitative PCR test at week 4 (RVR), a shorter treatment of 24 weeks is as effective as treatment for 48 weeks (figure 1B).^{60,73}

Antiviral therapy of HCV genotype 5 and 6

Limited data are available concerning the optimal treatment of HCV genotype 5 and 6. It is recommended to treat HCV genotype 5 and 6 like HCV genotype 1 (48 weeks).

Figure 1. Flowchart for the treatment of chronic hepatitis C²²



Recommendations	
Antiviral therapy consists of the administration of peginterferon and ribavirin for 24 or 48 weeks. Patients with HCV genotype 1 or 4 are treated for 48 weeks. Patients with HCV genotype 2 or 3 are treated for 24 weeks.	Level 1
In patients with an undetectable HCV RNA after 4 weeks of treatment and baseline HCV RNA <600,000 IU/ml, a shorter treatment is equally effective (12 to 16 weeks for HCV genotype 2 or 3, 24 weeks for HCV genotype 1 or 4 with baseline HCV RNA ≤600,000 IU/ml).	Level 1

Recommendations	
Monitoring is recommended at the start of treatment with peginterferon and ribavirin, after 2, 4, 8 and 12 weeks of treatment, and thereafter every 4 to 6 weeks until the end of treatment.	Level 2
HCV RNA assessment is recommended at the start of treatment, after 4, 12, 24 and 48 weeks of treatment, and 24 weeks after completion of treatment.	Level 1
Based on HCV RNA load at the start and after 4 weeks (28 days) of treatment, shortened treatment can be considered. HCV RNA assessment after 12 and 24 weeks should serve to predict non-SVR and antiviral therapy should be stopped early according to the stopping rules.	Level 1

FOLLOW-UP DURING ANTIVIRAL THERAPY

Patients who are treated with peginterferon and ribavirin should be monitored regularly at an outpatient clinic to evaluate the viral response and to monitor side effects (at the start, after 2, 4, 8 and 12 weeks of treatment, and afterwards every four to six weeks until the end of treatment; *table 3*). Blood tests (liver enzymes, glucose and full blood cell count) should be routinely done at every visit. Physical examination should be performed when indicated; it is recommended to assess the patient's weight at every visit. Every 12 weeks TSH should be assessed (*table 3*).⁸⁵ To keep the treatment as short as possible, HCV RNA should be tested at fixed time points (*table 5*). The HCV RNA load should be determined at the start and after 4, 12, 24 and 48 weeks of treatment (if treatment duration is 48 weeks; *tables 3 and 5*). Antiviral therapy can be stopped earlier if patients have no chance of achieving an SVR.^{8,66,86} and in patients who develop an RVR which warrants shorter treatment (*table 5*).^{60,62,73} The time it takes for patients to become HCV RNA negative is the strongest predictor for successful outcome of antiviral therapy, independent of the genotype.^{62,64,72-74,77,82,83,86,87} For reliable application of stopping rules at the various time points during treatment, it is necessary that baseline HCV RNA load is determined shortly before treatment. In patients with cirrhosis, abdominal ultrasound of the liver should be done every six months during treatment.

Side effects

The most important side effects during treatment with peginterferon and ribavirin are flu-like symptoms, depression, anaemia and neutropenia. Dose reduction is indicated in case of serious anaemia, thrombocytopenia or neutropenia (see paragraph about dose reduction and *table 9*). An overview of the most important side effects can be found in *table 6*. Intensive supportive care during treatment contributes to therapy compliance of patients and reduces the chance of premature discontinuation of treatment. Supportive care can be given by the treating physician and/or a specialised nurse. Supportive care of patients should preferably be provided by dedicated nurses, who should be easily accessible for the patient. Patients with significant side effects should be monitored more often at the outpatient clinic. If side effects occur, it is important to have easy access to other specialists (psychiatrist, dermatologist, ophthalmologist, dietician, social work).

Dose reduction of peginterferon and/or ribavirin

Leucopenia, anaemia and thrombocytopenia are frequent side effects of combination therapy with peginterferon and ribavirin. Dose reduction of peginterferon and ribavirin reduces the chance of an SVR.⁸⁸ Dose reduction should therefore only be applied when strictly indicated (*table 9*),⁸⁹ anaemia can be treated initially with erythropoietin and subsequently with blood transfusion. Although

Table 9. Recommendations for dose reduction during antiviral therapy

	Peginterferon-alpha-2a/2b	Ribavirin	Other treatments
Anaemia			
• Hb <5.0 mmol/l	-	-	Erythropoietin
• Hb <4.0 mmol/l	-	Dose to 800 mg/day	Transfusion and erythropoietin
Neutropenia			
• Neutrophil granulocytes <0.75 x 10 ⁹ /l	Dose to 75%	-	-
• Neutrophil granulocytes <0.375 x 10 ⁹ /l	Dose to 50%	-	-
Thrombocytopenia			
• Thrombocytes <50 x 10 ⁹ /l	Dose to 75%	-	-
• Thrombocytes <25 x 10 ⁹ /l	Dose to 50%	-	-
Modified to Bezemer <i>et al.</i> , ⁸⁹ evidence value grade 4.			

severe consequences of thrombocytopenia (bleeding) and neutropenia (infection) during treatment with peginterferon and ribavirin have not been observed,⁹⁰⁻⁹² it is recommended to reduce the dose and to monitor the patient more frequently if thrombocytopenia or neutropenia occurs. The peginterferon and ribavirin dose should be increased again if blood cell count has normalised.

FOLLOW-UP AFTER ANTIVIRAL THERAPY

HCV RNA should be determined with a qualitative PCR test (sensitivity of ≤ 50 IU/ml) 24 weeks after stopping antiviral therapy; a negative result indicates an SVR. Routine blood tests (liver enzymes, full blood cell count, TSH) should also be determined. Physical examination should be done when indicated. Monitoring should be continued in cirrhotic patients with an SVR because of the risk (reduced but still present) of HCC and decompensated cirrhosis. Noncirrhotic patients with an SVR can be discharged from the outpatient clinic. In these patients, HCV RNA testing can be considered after one to two years, since the chance of a late relapse is around 1 to 5%.⁶³ Monitoring should be continued in patients with nonresponse, breakthrough or relapse.

Hypothyroidism can occur after stopping antiviral therapy with peginterferon and ribavirin, therefore the TSH level should be determined in all patients one or two years after treatment.⁹³ Hypothyroidism during treatment with peginterferon and ribavirin is often reversible. Patients who developed hypothyroidism and receive thyroid hormone treatment may stop the hormone supplementation one or two years after antiviral treatment.⁹⁴⁻⁹⁷

THE FUTURE

Several specific inhibitors of viral enzymes (the NS3 serineprotease, NS3 helicase, NS5B RNA-polymerase), therapeutic vaccination, Toll-like-receptor agonists and other immune modulators, monoclonal and polyclonal antibodies, antisense RNA, modified forms of interferon and ribavirin and other molecules are currently being tested in phase I, II, III and IV clinical trials.⁹⁸⁻¹⁰³

Some of these drugs are promising. These new specific-HCV inhibitors are referred to as STAT-C (specifically targeted antiviral therapy for HCV). It is expected that the first new-generation anti-HCV drugs will be registered within the next three years. Treatment of chronic hepatitis C infection will probably be more effective and shorter. New treatment regimes will probably consist of a combination of peginterferon and ribavirin together with one or more new drugs.

HCV genotype 1 is the most difficult to treat and the most prevalent genotype in Europe, North America and Japan.

Therefore, some of the new drugs are specially developed for HCV genotype 1. This means that antiviral therapy may be postponed in patients with HCV genotype 1 infection without a strict indication for antiviral therapy; or these patients can participate in clinical trials where new drugs are being investigated.

ACKNOWLEDGEMENT

We thank Prof. Dr. J.P.H. Drenth and Dr. P.H.G.M. Stadhouders for their extensive peer review of the manuscript. Furthermore, we thank Christine J. Weegink for her substantial contribution to this guideline.

NOTE

Guidelines Committee for the Netherlands Association of Gastroenterologists and Hepatologists: H.L.A. Janssen, chairman; E.H.C.J. Buster, H.C. Gelderblom, secretaries; C.M. Bakker, J.T. Brouwer, K.J. van Erpecum, R.J. de Knecht, H.W. Reesink, S.W. Schalm, H.L. Zaaijer, members.

REFERENCES

1. Anonymous. Hepatitis C - global prevalence (update). *Weekly Epidemiological Record* 1999;74:425-427.
2. Lauer GM, Walker BD. Hepatitis C virus infection. *N Engl J Med* 2001;345:41-52.
3. Poynard T, Yuen MF, Ratziu V, Lai CL. Viral hepatitis C. *Lancet* 2003;362:2095-2100.
4. Hattum van HJ. Health strategy on HCV in The Netherlands. *Acta Gastroenterol Belg* 2002;65:115-117.
5. Terrault NA, Berenguer M. Treating hepatitis C infection in liver transplant recipients. *Liver Transpl* 2006;12:1192-1204.
6. Brown RS. Hepatitis C and liver transplantation. *Nature* 2005;436:973-978.
7. Yilmaz N, Shiffman ML, Stravitz RT, et al. A prospective evaluation of fibrosis progression in patients with recurrent hepatitis C virus following liver transplantation. *Liver Transpl* 2007;13:975-983.
8. National Institutes of Health Consensus Development Conference Statement: Management of hepatitis C: 2002-June 10-12, 2002. *Hepatology* 2002;36:S3-20.
9. Dienstag JL, McHutchison JG. American Gastroenterological Association technical review on the management of hepatitis C. *Gastroenterology* 2006;130:231-264.
10. Gerlach JT, Diepolder HM, Zachoval R, et al. Acute hepatitis C: high rate of both spontaneous and treatment-induced viral clearance. *Gastroenterology* 2003;125:80-88.
11. Nomura H, Sou S, Tanimoto H, et al. Short-term interferon- α therapy for acute hepatitis C: a randomized controlled trial. *Hepatology* 2004;39:1213-1219.
12. Wawrzynowicz-Syczewska M, Kubicka J, Lewandowski Z, Boron-Kaczmarek A, Radkowski M. Natural history of acute symptomatic hepatitis type C. *Infection* 2004;32:138-143.
13. Farci P, Alter HJ, Shimoda A, et al. Hepatitis C virus-associated fulminant hepatic failure. *N Engl J Med* 1996;335:631-634.

14. Jackson BR, Busch MP, Stramer SL, AuBuchon JP. The cost-effectiveness of NAT for HIV, HCV, and HBV in whole-blood donations. *Transfusion* 2003;43:721-729.
15. Kolk DP, Dockter J, Linnen J, et al. Significant closure of the human immunodeficiency virus type 1 and hepatitis C virus preseroconversion detection windows with a transcription-mediated-amplification-driven assay. *J Clin Microbiol* 2002;40:1761-1766.
16. Busch MP, Rawal BD, Feibig EW, Operskalski EA, Mosley JW. Dynamics of HCV viremia and seroconversion in transfusion-acquired HCV infections. *Transfusion* 1998;38(Suppl):265.
17. Dodd RY, Notari EP, Stramer SL. Current prevalence and incidence of infectious disease markers and estimated window-period risk in the American Red Cross blood donor population. *Transfusion* 2002;42:975-979.
18. Conry-Cantilena C, VanRaden M, Gobble J, et al. Routes of infection, viremia, and liver disease in blood donors found to have hepatitis C virus infection. *N Engl J Med* 1996;334:1691-1696.
19. Harris HE, Ramsay ME, Andrews N, Eldridge KP. Clinical course of hepatitis C virus during the first decade of infection: cohort study. *BMJ* 2002;324:450-453.
20. Pillonel J, Laperche S, Saura C, Desenclos JC, Courouze AM. Trends in residual risk of transfusion-transmitted viral infections in France between 1992 and 2000. *Transfusion* 2002;42:980-988.
21. Soldan K, Barbara JA, Ramsay ME, Hall AJ. Estimation of the risk of hepatitis B virus, hepatitis C virus and human immunodeficiency virus infectious donations entering the blood supply in England, 1993-2001. *Vox Sang* 2003;84:274-286.
22. Manns MP, Wedemeyer H, Cornberg M. Treating viral hepatitis C: efficacy, side effects, and complications. *Gut* 2006;55:1350-1359.
23. Minola E, Prati D, Suter F, et al. Age at infection affects the long-term outcome of transfusion-associated chronic hepatitis C. *Blood* 2002;99:4588-4591.
24. Marcellin P. Hepatitis C: the clinical spectrum of the disease. *J Hepatol* 1999;31 Suppl 1:9-16.
25. Sangiovanni A, Prati GM, Fasani P, et al. The natural history of compensated cirrhosis due to hepatitis C virus: A 17-year cohort study of 214 patients. *Hepatology* 2006;43:1303-1310.
26. Seeff LB. Natural history of chronic hepatitis C. *Hepatology* 2002;36:S35-S46.
27. Armstrong GL, Wasley A, Simard EP, McQuillan GM, Kuhnert WL, Alter MJ. The prevalence of hepatitis C virus infection in the United States, 1999 through 2002. *Ann Intern Med* 2006;144:705-714.
28. Tanaka Y, Hanada K, Mizokami M, et al. Inaugural Article: A comparison of the molecular clock of hepatitis C virus in the United States and Japan predicts that hepatocellular carcinoma incidence in the United States will increase over the next two decades. *Proc Natl Acad Sci U S A* 2002;99:15584-15589.
29. Kenny-Walsh E. Clinical outcomes after hepatitis C infection from contaminated anti-D immune globulin. Irish Hepatology Research Group. *N Engl J Med* 1999;340:1228-1233.
30. Posthouwer D, Makris M, Yee TT, et al. Progression to end-stage liver disease in patients with inherited bleeding disorders and hepatitis C: an international, multicenter cohort study. *Blood* 2007;109:3667-3671.
31. Wiese M, Grungreiff K, Guthoff W, Lafrenz M, Oesen U, Porst H. Outcome in a hepatitis C (genotype 1b) single source outbreak in Germany--a 25-year multicenter study. *J Hepatol* 2005;43:590-598.
32. Koretz RL, Abbey H, Coleman E, Gitnick G. Non-A, non-B post-transfusion hepatitis. Looking back in the second decade. *Ann Intern Med* 1993;119:110-115.
33. Agnello V, De Rosa FG. Extrahepatic disease manifestations of HCV infection: some current issues. *J Hepatol* 2004;40:341-352.
34. Ramos-Casals M, Font J. Extrahepatic manifestations in patients with chronic hepatitis C virus infection. *Curr Opin Rheumatol* 2005;17:447-455.
35. Amin J, Law MG, Bartlett M, Kaldor JM, Dore GJ. Causes of death after diagnosis of hepatitis B or hepatitis C infection: a large community-based linkage study. *Lancet* 2006;368:938-945.
36. Alter HJ. HCV natural history: the retrospective and prospective in perspective. *J Hepatol* 2005;43:550-552.
37. Perz JF, Armstrong GL, Farrington LA, Hutin YJ, Bell BP. The contributions of hepatitis B virus and hepatitis C virus infections to cirrhosis and primary liver cancer worldwide. *J Hepatol* 2006;45:529-538.
38. www.emea.europa.eu/humandocs/PDFs/EPAR/Pegintron/H-280-Pl-nl.pdf. PegIntron (peginterferon-alfa-2b) summary of product characteristics.
39. www.emea.europa.eu/humandocs/PDFs/EPAR/Rebetol/H-246-Pl-nl.pdf. Rebetol (ribavirin) summary of product characteristics.
40. www.roche.nl/producten/spc/peg180S.pdf. Pegasys (peginterferon-alfa-2a) summary of product characteristics.
41. www.roche.nl/producten/spc/cop200tab.pdf. Copegus (ribavirin) summary of product characteristics.
42. Bianca S, Ettore G. Male periconceptional ribavirin-interferon alpha-2b exposure with no adverse fetal effects. *Birth Defects Res A Clin Mol Teratol* 2003;67:77-78.
43. Hillyard IW. The preclinical toxicology and safety of ribavirin. In: Smith RA, Kirkpatrick W (Eds). *Ribavirin: a broad spectrum antiviral agent*. New York: Academic Press 1980;59-72.
44. Johnson EM. Developmental toxicity and safety evaluations of ribavirin. *Pediatr Infect Dis J* 1990;9:S85-S87.
45. Polifka JE, Friedman JM. Developmental toxicity of ribavirin/IFalpha combination therapy: is the label more dangerous than the drugs? *Birth Defects Res A Clin Mol Teratol* 2003;67:8-12.
46. Rezvani M, Koren G. Pregnancy outcome after exposure to injectable ribavirin during embryogenesis. *Reprod Toxicol* 2006;21:113-115.
47. FDA Pregnancy Category X http://a257.g.akamaitech.net/7/257/2422/14mar20010800/edocket.access.gpo.gov/cfr_2003/apr/qtr/pdf/21cfr201.57.pdf.
48. Bruix J, Sherman M. Management of hepatocellular carcinoma. *Hepatology* 2005;42:1208-1236.
49. Trevisani F, De NS, Rapaccini G, et al. Semiannual and annual surveillance of cirrhotic patients for hepatocellular carcinoma: effects on cancer stage and patient survival (Italian experience). *Am J Gastroenterol* 2002;97:734-744.
50. Zhang BH, Yang BH, Tang ZY. Randomized controlled trial of screening for hepatocellular carcinoma. *J Cancer Res Clin Oncol* 2004;130:417-422.
51. Reiss G, Keeffe EB. Review article: hepatitis vaccination in patients with chronic liver disease. *Aliment Pharmacol Ther* 2004;19:715-727.
52. Mast EE, Weinbaum CM, Fiore AE, et al. A comprehensive immunization strategy to eliminate transmission of hepatitis B virus infection in the United States: recommendations of the Advisory Committee on Immunization Practices (ACIP) Part II: immunization of adults. *MMWR Recomm Rep* 2006;55:1-33.
53. Kraus MR, Schafer A, Al-Taie O, Scheurlen M. Prophylactic SSRI during interferon alpha re-therapy in patients with chronic hepatitis C and a history of interferon-induced depression. *J Viral Hepat* 2005;12:96-100.
54. Layden-Almer JE, Ribeiro RM, Wiley T, Perelson AS, Layden TJ. Viral dynamics and response differences in HCV infected African American and white patients treated with IFN and ribavirin. *Hepatology* 2003;37:1343-1350.
55. Muir AJ, Bornstein JD, Killenberg PG. Peginterferon alfa-2b and ribavirin for the treatment of chronic hepatitis C in blacks and non-Hispanic whites. *N Engl J Med* 2004;350:2265-2271.
56. Charlton MR, Pockros PJ, Harrison SA. Impact of obesity on treatment of chronic hepatitis C. *Hepatology* 2006;43:1177-1186.
57. Berg T, Sarrazin C, Herrmann E, et al. Prediction of treatment outcome in patients with chronic hepatitis C: significance of baseline parameters and viral dynamics during therapy. *Hepatology* 2003;37:600-609.
58. Weegink CJ, Sentjens RE, Beld MG, Dijkgraaf MG, Reesink HW. Chronic hepatitis C patients with a post-treatment virological relapse re-treated with an induction dose of 18 MU interferon-alpha in combination with ribavirin and amantadine: a two-arm randomized pilot study. *J Viral Hepat* 2003;10:174-182.
59. Fried MW, Shiffman ML, Reddy KR, et al. Peginterferon alfa-2a plus ribavirin for chronic hepatitis C virus infection. *N Engl J Med* 2002;347:975-982.
60. Hadziyannis SJ, Sette H Jr, Morgan TR, et al. Peginterferon-alpha2a and ribavirin combination therapy in chronic hepatitis C: a randomized

- study of treatment duration and ribavirin dose. *Ann Intern Med* 2004;140:346-355.
61. Manns MP, McHutchison JG, Gordon SC, et al. Peginterferon alfa-2b plus ribavirin compared with interferon alfa-2b plus ribavirin for initial treatment of chronic hepatitis C: a randomised trial. *Lancet* 2001;358:958-965.
 62. Zeuzem S, Buti M, Ferenci P, et al. Efficacy of 24 weeks treatment with peginterferon alfa-2b plus ribavirin in patients with chronic hepatitis C infected with genotype 1 and low pretreatment viremia. *J Hepatol* 2006;44:97-103.
 63. Veldt BJ, Saracco G, Boyer N, et al. Long term clinical outcome of chronic hepatitis C patients with sustained virological response to interferon monotherapy. *Gut* 2004;53:1504-1508.
 64. Jensen DM, Morgan TR, Marcellin P, et al. Early identification of HCV genotype 1 patients responding to 24 weeks peginterferon alpha-2a (40 kd)/ribavirin therapy. *Hepatology* 2006;43:954-960.
 65. Zeuzem S, Hultcrantz R, Bourliere M, et al. Peginterferon alfa-2b plus ribavirin for treatment of chronic hepatitis C in previously untreated patients infected with HCV genotypes 2 or 3. *J Hepatol* 2004;40:993-999.
 66. Davis GL, Wong JB, McHutchison JG, Manns MP, Harvey J, Albrecht J. Early virological response to treatment with peginterferon alfa-2b plus ribavirin in patients with chronic hepatitis C. *Hepatology* 2003;38:645-652.
 67. Fattovich G, Giustina G, Favarato S, Ruol A. A survey of adverse events in 11,241 patients with chronic viral hepatitis treated with alfa interferon. *J Hepatol* 1996;24:38-47.
 68. Fried MW. Side effects of therapy of hepatitis C and their management. *Hepatology* 2002;36:S237-S244.
 69. Jansen PL, Reesink HW. Antiviral effect of peginterferon alfa-2b and alfa-2a compared. *J Hepatol* 2006;45:172-173.
 70. Jacobson IM, Brown RS Jr, Freilich B, et al. Peginterferon alfa-2b and weight-based or flat-dose ribavirin in chronic hepatitis C patients: a randomized trial. *Hepatology* 2007;46:971-981.
 71. Jacobson IM, Brown RS Jr, McCone J, et al. Impact of weight-based ribavirin with peginterferon alfa-2b in African Americans with hepatitis C virus genotype 1. *Hepatology* 2007;46:982-990.
 72. Ferenci P, Bergholz U, Laferl H, et al. Is shorter treatment with peginterferon alfa-2a (40KD) (PEGASYS (R)) plus ribavirin (COPEGUS (R)) possible in HCV genotype 1 'super-responders'? preliminary results of a prospective randomized clinical trial. *Hepatology* 2005;42:218A.
 73. Ferenci P, Scherzer T, Laferl H, et al. High SVR rate, with 24 weeks of peginterferon alpha-2a (40KD) (PEGASYS (R)) plus ribavirin (COPEGUS (R)) in HCV genotype 1 or 4 patients with a week-4 virological response. *J Clin Virol* 2006;36:S50.
 74. Dalgard O, Bjoro K, Hellum KB, et al. Treatment with pegylated interferon and ribavirin in HCV infection with genotype 2 or 3 for 14 weeks: a pilot study. *Hepatology* 2004;40:1260-1265.
 75. Dalgard O, Bjoro K, Ring-Larsen H, et al. Pegylated interferon alfa and ribavirin for 14 versus 24 weeks in patients with hepatitis C virus genotype 2 or 3 and rapid virological response. *Hepatology* 2008;47:35-42.
 76. Lagging M, Langeland N, Pedersen C, et al. Comparison of Peginterferon alfa-2a and Ribavirin for 12 or 24 weeks in patients with HCV genotype 2/3: the NORDynamic trial. *ABSTRACT EASL* 2007. 46 ed. 2007.
 77. Mangia A, Santoro R, Minerva N, et al. Peginterferon alfa-2b and ribavirin for 12 vs. 24 weeks in HCV genotype 2 or 3. *N Engl J Med* 2005;352:2609-2617.
 78. Shiffman M, Minola E, Barange K, et al. Characterisation of hepatitis C virus genotype 2/3 patients without a rapid virological response (RVR): optimising treatment by predicting slower responders to peginterferon alfa-2a (40 KD) (PEGASYS(r)) plus ribavirin (COPEGUS(r)) *ABSTRACT EASL* 2007. 46 ed. 2007.
 79. Shiffman M, Pappas S, Bacon B, et al. Utility of virological response at weeks 4 and 12 in the prediction of SVR rates in genotype 2/3 patients treated with Peginterferon alfa-2a (40kd) plus ribavirin: Findings from accelerate. *Hepatology* 2006;44:316A-317A.
 80. Shiffman M, Pappas S, Greenbloom S, et al. Effect of drug exposure on sustained virological response (SVR) in patients with chronic hepatitis C virus genotype 2 or 3 treated with Peginterferon alfa-2a (40kd) (PEGASYS (R)) plus ribavirin (COPEGUS (R)) for 16 or 24 weeks. *Hepatology* 2006;44:317A-318A.
 81. Shiffman ML, Pappas S, Nyberg L, et al. Peginterferon alpha-2a (PEGASYS) plus ribavirin (COPEGUS) for 16 or 24 weeks in patients with HCV genotype 2 or 3. Final results of the accelerate trial. *J Hepatol* 2006;44:S271.
 82. Wagner von M, Huber M, Berg T, et al. Peginterferon-alpha-2a (40KD) and ribavirin for 16 or 24 weeks in patients with genotype 2 or 3 chronic hepatitis C. *Gastroenterology* 2005;129:522-527.
 83. Yu ML, Dai CY, Huang JF, et al. A randomised study of peginterferon and ribavirin for 16 versus 24 weeks in patients with genotype 2 chronic hepatitis C. *Gut* 2007;56:553-559.
 84. Hoofnagle JH, Seeff LB. Peginterferon and ribavirin for chronic hepatitis C. *N Engl J Med* 2006;355:2444-2451.
 85. Prummel MF, Laurberg P. Interferon-alpha and autoimmune thyroid disease. *Thyroid* 2003;13:547-551.
 86. Ferenci P, Fried MW, Shiffman ML, et al. Predicting sustained virological responses in chronic hepatitis C patients treated with peginterferon alfa-2a (40 KD)/ribavirin. *J Hepatol* 2005;43:425-433.
 87. Lukasiewicz E, Hellstrand K, Westin J, et al. Predicting treatment outcome following 24 weeks peginterferon alpha-2a/ribavirin therapy in patients infected with HCV genotype 1: utility of HCV RNA at day 0, day 22, day 29, and week 6. *Hepatology* 2007;45:258-259.
 88. McHutchison JG, Manns M, Patel K, et al. Adherence to combination therapy enhances sustained response in genotype-1-infected patients with chronic hepatitis C. *Gastroenterology* 2002;123:1061-1069.
 89. Bezemer G, Schalm SW, van Gool AR, de Kneegt RJ. [Changes in the management of patients with side effects from the treatment of hepatitis C]. *Ned Tijdschr Geneesk* 2007;151:525-530.
 90. Cooper CL, Al-Bedwawi S, Lee C, Garber G. Rate of infectious complications during interferon-based therapy for hepatitis C is not related to neutropenia. *Clin Infect Dis* 2006;42:1674-1678.
 91. Renou C, Harafa A, Cummins C, et al. Threshold for neutropenia in the adjustment of interferon treatment in HCV infection. *Hepatology* 2003;37:949-950.
 92. Soza A, Everhart JE, Ghany MG, et al. Neutropenia during combination therapy of interferon alfa and ribavirin for chronic hepatitis C. *Hepatology* 2002;36:1273-1279.
 93. Carella C, Mazziotti G, Morisco F, et al. Long-term outcome of interferon-alpha-induced thyroid autoimmunity and prognostic influence of thyroid autoantibody pattern at the end of treatment. *J Clin Endocrinol Metab* 2001;86:1925-1929.
 94. Bini EJ, Mehandru S. Incidence of thyroid dysfunction during interferon alfa-2b and ribavirin therapy in men with chronic hepatitis C: a prospective cohort study. *Arch Intern Med* 2004;164:2371-2376.
 95. Doi F, Kakizaki S, Takagi H, et al. Long-term outcome of interferon-alpha-induced autoimmune thyroid disorders in chronic hepatitis C. *Liver Int* 2005;25:242-246.
 96. Kee KM, Lee CM, Wang JH, et al. Thyroid dysfunction in patients with chronic hepatitis C receiving a combined therapy of interferon and ribavirin: incidence, associated factors and prognosis. *J Gastroenterol Hepatol* 2006;21:319-326.
 97. Moncoucy X, Leymarie F, Delemer B, et al. Risk factors and long-term course of thyroid dysfunction during antiviral treatments in 221 patients with chronic hepatitis C. *Gastroenterol Clin Biol* 2005;29:339-345.
 98. McHutchison JG, Bartenschlager R, Patel K, Pawlowsky JM. The face of future hepatitis C antiviral drug development: recent biological and virologic advances and their translation to drug development and clinical practice. *J Hepatol* 2006;44:411-421.
 99. Pawlowsky JM. Therapy of hepatitis C: from empiricism to eradication. *Hepatology* 2006;43:S207-S220.
 100. Reesink HW, Zeuzem S, Weegink CJ, et al. Rapid decline of viral RNA in hepatitis C patients treated with VX-950: a phase Ib, placebo-controlled, randomized study. *Gastroenterology* 2006;131:997-1002.
 101. www.hcvadvocate.org/hepatitis/hepC/HCVDrugs.html. HCV Advocate.
 102. www.hcvdrugs.com. Hepatitis C New Drug Pipeline.
 103. www.hivandhepatitis.com/hep_c.html. HIV and Hepatitis.com.

Award for the best article published in *Netherlands Journal of Medicine* in 2007

As in the previous year, the *Netherlands Journal of Medicine* has chosen one paper published in 2007 as the best article. All papers in 2007 were reviewed independently by three jury members. The following criteria played a role in the selection process:

- articles from general hospitals received some preference;
- retrospective studies received lower scores;
- articles with practical implications scored higher;
- articles from junior investigators scored higher.

In reviewing the papers the jury particularly paid attention to originality and scientific value, clarity of research question, methods of investigation, clinical relevance and the way the paper was written.

The short lists showed some differences, but the jury was unanimous with respect to the nomination of the paper by Van der Eerden *et al.*¹ This study concerns a well-performed diagnostic investigation of patients with Cushing's syndrome

with respect to bone mineral density. The results show that even younger patients with Cushing's syndrome have decreased bone mineral density and that treatment with bisphosphonates should always be considered. It is written by a young investigator and has practical implications. The winner received a certificate and € 500, which were presented by the Chairman of the *NIV-dagen* in Maastricht in April 2008.

P. de Leeuw, M. Levi, A. Stalenhoef

*Members of the Jury, Netherlands Journal of Medicine
Award 2007*

REFERENCE

1. Van der Eerden AW, den Heijer M, Oyen WJ, Hermus AR. Cushing's syndrome and bone mineral density: lowest Z scores in young patients. *Neth J Med* 2007;65(4):137-41.

Erratum

In the original article 'Clinical course and prognostic factors of clinically early IgA nephropathy' by P. Shen, L. He and D. Huang, published in *Neth J Med* 2008;66(6):242-7, the corresponding author should be L. He. Furthermore the following note should have been included: the article was supported by Shanghai Leading Academic Discipline Project (project number: Y0302).

MONTHLY NJM ONLINE HITLIST

The table lists online hits for all articles published in the April issue of the Netherlands Journal of Medicine 2008 (available online on PubMed since 21 april 2008).

Article	Hits
EDITORIAL	
The pathophysiology of organophosphorus pesticide self-poisoning is not so simple	189
REVIEW	
Organophosphorus pesticide poisoning: cases and developments	197
ORIGINAL ARTICLE	
Preoperative levosimendan in heart failure patients undergoing noncardiac surgery	155
CASE REPORTS	
Visceral involvement in an immunocompetent male: a rare presentation of cat scratch disease	135
Paraganglioma of the urinary bladder	100
Acute renal failure in <i>Plasmodium malariae</i> infection	125
SPECIAL REPORTS	
Clinical practice guideline for cardiovascular risk management in the Netherlands	123
50 Years <i>Netherlands Journal of Medicine</i>	57
PHOTO QUIZZES	
Unusual cause of chronic ascites	118
Erythematous pigmentation of the arm for more than ten years	86
LETTER TO THE EDITOR	
Comments on the review article: Ascites in cirrhosis: a review of management and complications	121
Response to letter to the editor	112
MONTHLY NJM ONLINE HITLIST	
For all articles published in January 2008	
Total	61

Aims and scope

The Netherlands Journal of Medicine publishes papers in all relevant fields of internal medicine. In addition to reports of original clinical and experimental studies, reviews on topics of interest or importance, case reports, book reviews and letters to the editor are welcomed.

Manuscripts

Manuscripts submitted to the Journal should report original research not previously published or being considered for publication elsewhere. Submission of a manuscript to this Journal gives the publisher the right to publish the paper if it is accepted. Manuscripts may be edited to improve clarity and expression.

Language

The language of the Journal is English. English idiom and spelling is used in accordance with the Oxford dictionary. Thus: Centre and not Center, Tumour and not Tumor, Haematology and not Hematology.

Submission

All submissions to the *Netherlands Journal of Medicine* should be submitted online through Manuscript Central at <http://mc.manuscriptcentral.com/nethjmed>. Authors should create an account and follow the instructions. If you are unable to submit through Manuscript Central contact the editorial office at g.derksen@aig.umcn.nl, tel.: +31 (0)24-361 04 59 or fax: +31 (0) 24-354 17 34.

Preparation of manuscripts

Type all pages with double spacing and wide margins on one side of the paper. To facilitate the reviewing process, number the lines in the margin and the pages.

Subheadings should not exceed 55 characters, including spaces.

Abbreviations: Measurements should be abbreviated according to SI units. All other abbreviations or acronyms should be defined on the first appearance in the text. Use a capital letter for generic names of substances and materials.

A *Covering letter* should accompany the manuscript, identifying the corresponding person (with the address, telephone number, fax number and e-mail address). Conflicts of interest, commercial affiliations, consultations, stock or equity interests should be specified. In the letter one to three sentences should be dedicated to what this study adds. The letter should make it clear that the final manuscript has been seen and approved by all authors. All authors should sign the letter. The letter should either be submitted through <http://mc.manuscriptcentral.com/nethjmed> or faxed to the editorial office (+31 (0)24-354 17 34).

Divide the manuscript into the following sections: Title page, Abstract, Keywords, Introduction, Materials and Methods, Results, Discussion, Acknowledgements, References, Tables and Figures with Legends.

The *Title page* should include authors' names, degrees, academic addresses, correspondence address, including telephone number, fax number, e-mail address and grant support. Also the contribution of each author should be specified.

The title should be informative and not exceed 90 characters, including spaces. Avoid use of extraneous words such as 'study', 'investigation' as well as priority claims (new, novel, first). Give a running title of less than 50 characters. If data from the manuscript have been presented at a meeting, list the name, date and location of the meeting and reference and previously published abstracts in the bibliography. Give a word count (including references, excluding tables and legends) at the bottom of this page.

The *Abstract*, not exceeding 250 words, should be written in a structured manner and with particular care. In original articles, the Abstract should consist of the following paragraphs: Background, Methods, Results and Conclusion. They should briefly describe the problem being addressed in the study, how the study was performed and which measurements were carried out, the most relevant results, and what the authors conclude from the results.

Keywords: Include three to five keywords.

The *Introduction* should be brief and set out the purposes for which the study has been performed.

The *Materials and methods* should be sufficiently detailed so that readers and reviewers can understand precisely what has been done without studying the references directly. The description may be abbreviated when well-accepted techniques are used.

The *Results* should be presented precisely, without discussion.

The *Discussion* should directly relate to the study being reported. Do not include a general review of the topic, but discuss the pertinent literature.

Acknowledgement: All funding sources should be credited here. Also a statement of conflicts of interest should be mentioned.

References should be numbered consecutively as they appear in the text (after the punctuation and in square brackets). Type the reference list with double spacing on a separate page. References should be in the language they are published in, conform the 'Vancouver' style for biomedical journals (N Engl J Med 1991;324:424-8).

Journal abbreviations should conform to the style used in the Cumulated Index Medicus. Examples:

1. Smilde TJ, van Wissen S, Wollersheim H, Kastelein JJP, Stalenhoef AFH. Genetic and metabolic factors predicting risk of cardiovascular disease in familial hypercholesterolemia. *Neth J Med* 2001;59:184-95.
2. Kaplan NM. *Clinical Hypertension*. 7th ed. Baltimore: Williams & Wilkins; 1998.
3. Powell LW, Isselbacher KJ. Hemochromatosis. In: Braunwald E, Fauci AS, Kasper DL, et al., editors. *Harrison's Principles of Internal Medicine*. 15th edition. New York: McGraw-Hill; 2001. p. 2257-61.

Please note that all authors should be listed when six or less; when seven or more, list only the first three and add et al. Do not include references to personal communications, unpublished data or manuscripts either 'in preparation' or 'submitted for publication'. If essential, such material may be incorporated into the appropriate place in the text. Recheck references in the text against the reference list after your manuscript has been revised.

The use of bibliographic software programmes that are designed to generate reference lists such as Reference Manager[®] or Endnote[®] is highly encouraged. Authors can use the predefined output 'Vancouver' style from these programmes.

Tables should be typed with double spacing each on a separate page, numbered consecutively with Arabic numerals, and should contain only horizontal lines. Provide a short descriptive heading above each table with footnotes and/or explanation underneath.

Figures must be suitable for high-quality reproduction (>300 DPI). Submit line drawings made in Word or other computer programmes but not in a PowerPoint file. Colour figures are occasionally possible and will be charged to the authors.

Legends for figures should be typed, with double spacing, on a separate page.

Case reports

Case reports containing concise reports on original work will be considered for publication. Case reports which are relevant for understanding the pathophysiology or clinical presentation of disease may also be accepted under this heading. Selection of case reports will be based on criteria as outlined in a special report by the editors (Drenth et al. The case for case reports in the Netherlands Journal of Medicine.

Neth J Med 2006;64(7):262-4). We advise potential authors to take notice of the instructions in this report. Articles published in this section should be no longer than 1000 words, and supplied with a summary of about 60 words, preferably no more than two figures and/or tables, and no more than 15 references.

Mini reviews

Mini reviews are concise notes that bring the reader up to date with the recent developments in the field under discussion. The review article should mention any previous important reviews in the field and contain a comprehensive discussion starting with the general background of the field. It should then go on to discuss the salient features of recent developments. The authors should avoid presenting material which has already been published in a previous review. The manuscript should be divided as follows: title page, abstract and main text. The text may be subdivided further according to the areas to be discussed. The text should not exceed 2500 words.

Letters to the editor (correspondence)

Letters to the editor will be considered by the editorial board. Letters should be no more than 400 words. Please use SI units for measurements and provide the references conform the Vancouver style (N Engl J Med 1991;324:424-8). No more than one figure is allowed. For letters referring to articles previously published in the Journal, the referred article should be quoted in the list of references.

Photo quiz

A photo quiz should not exceed 500 words and include no more than two figures and four references conform the Vancouver style. Abbreviations of measurements should be quoted in SI units.

Book reviews

The editorial board will consider articles reviewing books.

Reviewing process

After external and editorial review of the manuscript the authors will be informed about acceptance, rejection or revision. We require revision as stated in our letter.

Proofs

Proofs will be sent to the authors to be carefully checked for printer's errors. Changes or additions to the edited manuscript cannot be allowed at this stage. Corrected proofs should be returned to the editorial office within two days of receipt.

Offprints

These are not available. The first author receives a sample copy of the Journal with the published article.