

# Spots inside out

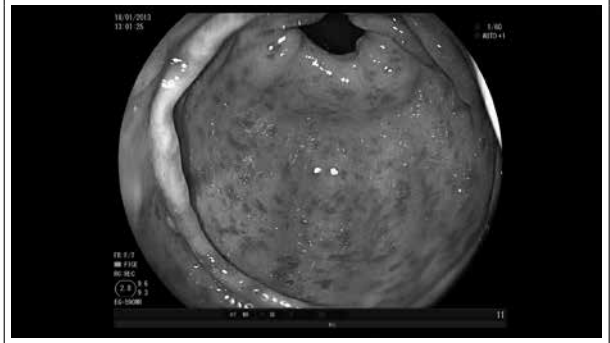
P. Krijnsen, C. Halma

Medical Centre Leeuwarden, Leeuwarden, the Netherlands

## CASE REPORT

A 73-year-old male patient presented with dyspnoea, coughing, loss of appetite because of abdominal discomfort, bloody stools and a spontaneous haematoma on the buttocks. In the weeks prior to admission the patient had been treated with two different antibiotics and glimepiride had recently been started for diabetes mellitus. His further medical history included tuberculosis, alcohol abuse, morbid obesity and COPD. Physical examination revealed petechiae on his ankles and lower back and a sizeable haematoma on the buttocks. Laboratory results showed a slightly elevated C-reactive protein (76;  $n \leq 6$  mg/l), leucocytosis ( $20.6; n=4-11 \times 10^9/l$ ) normal platelet count ( $313; n=150-400 \times 10^9/l$ ) and acute on chronic kidney failure (creatinine=168; 95 previously;  $n=50-110 \mu\text{mol/l}$ ), no proteinuria (urine protein/creatinine ratio 0.12;  $n < 0.13$ ) and microscopic erythrocyturia. Because of the abdominal pain and melaena, a duodenoscopy was performed which showed purpuric lesions of the antrum (*figure 1*)

Figure 1. Purpuric lesions of the antrum



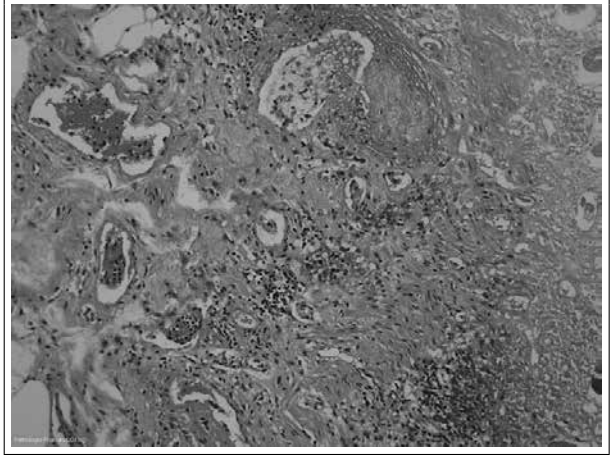
## WHAT IS YOUR DIAGNOSIS?

See page 36 for the answer to this photo quiz.

## DIAGNOSIS

Biopsies from the antrum and duodenum showed mild inflammation. The definitive diagnosis was made after a biopsy of the haematoma on the buttocks, which showed a perivascular infiltrate of mixed cells (leukocytoclastic vasculitis) with vascular deposits positive for IgA on immunofluorescence consistent with IgA vasculitis (figure 2). IgA vasculitis/Henoch-Schönlein purpura (IgAV) is a small-vessel vasculitis with IgA immune complex depositions. It is characterised by a tetrad of clinical manifestations: palpable purpura (lower limb predominance), arthritis/arthralgia, diffuse abdominal pain and proteinuria/haematuria.<sup>1</sup> It is a typical childhood disease with an incidence of 17:100,000 but it may be seen in adults. It generally occurs outside the summer season and half of the episodes are preceded by an upper respiratory tract infection.<sup>2</sup> A variety of infectious, genetic and chemical triggers are suggested as causes of IgAV.<sup>3</sup> Because of deteriorating renal function, the patient was treated with methylprednisolone. On the 12th hospital day he was transferred to the intensive care unit (ICU) because of an unexplained coma later shown to be caused by metabolic encephalopathy (serum ammonia 2.46; n <30 µmol/l). On the ICU he died within 24 hours due to multiple organ dysfunction. At autopsy complete ischaemia of the jejunum and ileum was found probably due to an arterial occlusion caused by extensive atherosclerosis of the abdominal circulation, although a microvascular cause (IgAV) could not be ruled out. A similar case report was recently published.<sup>4</sup> Unfortunately, immunofluorescence or microscopy of the kidney was not possible because of autolysis.

Figure 2. Perivascular infiltration



## REFERENCES

1. Ozen S, Pistorio A, Iusan SM, et al. EULAR/PRINTO/PRES criteria for Henoch-Schönlein purpura, childhood polyarteritis nodosa, childhood Wegener granulomatosis and childhood Takayasu arteritis: Ankara 2008. Part II: Final classification criteria. *Ann Rheum Dis.* 2010;69:798-806.
2. Farley TA, Gillespie S, Rasoulpour M, Tolentino N, Hadler JL, Hurwitz E. Epidemiology of a Cluster of Henoch-Schönlein Purpura. *Am J Dis Child.* 1989;143:798-803.
3. Saulsbury FT. Henoch-Schönlein purpura. *Curr Opin Rheumatol.* 2010;22:598-602.
4. Oshikata C, Tsurikisawa N, Takigawa M, et al. An adult patient with Henoch-Schönlein purpura and non-occlusive mesenteric ischemia. *BMC Res Notes.* 2013;6:26.