The Netherlands Journal of Medicine

REVIEW

Oxybutynin: dry days for patients with hyperhidrosis

G.S. Mijnhout[1*], H. Kloosterman[2], S. Simsek[1], R.J.M. Strack van Schijndel[3], J.C. Netelenbos[1]

Departments of [1]Endocrinology and [3]Internal Medicine, VU University Medical Centre, Amsterdam, the Netherlands, [2]General Practitioner, Den Helder, the Netherlands, [*]corresponding author: tel.: +31 (0)20-444 41 01, fax: +31 (0)20-444 05 02, e-mail: g.s.mijnhout@isala.nl

ABSTRACT

We report the case of a 56-year-old postmenopausal woman who was referred to our Endocrinology Outpatient Clinic because of severe hyperhidrosis. She had a four-year history of excessive sweating of her face and upper body. On presentation no sweating could be documented. Physical examination was also unremarkable. It appeared that five days earlier her general practitioner had prescribed oxybutynin for urge incontinence and this accidentally cured her hyperhidrosis. She was diagnosed with idiopathic hyperhidrosis. We advised her to continue the oxybutynin and six months later, she was still symptom-free. Oral anticholinergic drugs are known to be effective for hyperhidrosis, but only anecdotal reports on oxybutynin can be found in the literature. Oxybutynin is not approved for hyperhidrosis, explaining the unfamiliarity with this medicine. This case shows that oxybutynin can be a very effective and simple treatment with only mild side effects. Therefore, oxybutynin merits consideration in patients with idiopathic hyperhidrosis. This report includes a concise review of the causes and treatment options of hyperhidrosis.

KEYWORDS

Anticholinergics, hyperhidrosis, oxybutynin, sweating

Table 1. *Causes of hyperhidrosis*

Generalised
Menopausal
Endocrine diseases: hyperthyroidism, carcinoid syndrome, pheochromocytoma, mastocytosis, diabetes mellitus, hypoglycaemia, acromegaly
Serotonin syndrome
Chronic infections: e.g. endocarditis, tuberculosis, HIV infection
Malignancy: lymphoma, bronchial carcinoma with compression of the sympathetic chain
Neurological: brain damage, spinal cord injuries, autonomic dysreflexia, Parkinson's disease, Shapiro's syndrome
Drug-induced: antidepressants, antipyretics, antimigraine drugs, cholinergic agonists, GnRH agonists, sympathomimetic agents, β-blockers, cyclosporine and many others
Focal
Idiopathic palmar, plantar, axillary and/or facial hyperhidrosis
Hexsel's hyperhidrosis: inguinal hyperhidrosis
Localised unilateral hyperhidrosis (LUH): restricted to an area smaller than 10 x 10 cm on the forearm or forehead, unknown pathogenesis
Ross' syndrome: a progressive segmental anhidrosis of the trunk with a compensatory band of excessive hyperhidrosis
Frey's syndrome (gustatory sweating): preauricular hyperhidrosis and flushing in response to eating, a common complication after parotid gland surgery
Harlequin syndrome: episodic unilateral facial flushing and sweating

INTRODUCTION

Hyperhidrosis, or excessive sweating beyond physiological needs, is not a rare problem (prevalence 1%).[1] Not only endocrinologists, but particularly general practitioners, internists and dermatologists are confronted with this disorder. Hyperhidrosis may be either focal (localised) or generalised (*table 1*).[2] According to its aetiology, it may be primary or secondary. Primary hyperhidrosis is usually idiopathic and focal, affecting the palms, axillae, plantar surfaces, face and neck. The condition is frequently brought on by emotional response. In addition, there is evidence of a genetic predisposition. Studies are currently being performed to identify the responsible gene(s). Secondary hyperhidrosis tends to be generalised and is typically associated with endocrine diseases (including hyperthyroidism, diabetes, pheochromocytoma, carcinoid,

systemic mastocytosis) but also occurs with malignancy and neurological diseases. In addition, hyperhidrosis can be a side effect of many drugs. Secondary hyperhidrosis is usually caused by a resetting of the sweat centre in the hypothalamus. Besides primary and secondary hyperhidrosis, several rare forms of focal hyperhidrosis occur in association with specific syndromes: localised unilateral hyperhidrosis (LUH), Ross' syndrome, Frey's syndrome and Harlequin syndrome (*table 1*).

Even today, hyperhidrosis is often misconceived to be an untreatable disorder. For idiopathic hyperhidrosis, several proven effective treatments are available: local treatment with aluminium (hydro)chloride, local resection of sweat glands, iontophoresis, botulinum toxin, and endoscopic sympathectomy (*table 2*).[3-6] We describe a patient who was successfully treated with oxybutynin.

Table 2. *Current therapeutic options for hyperhidrosis (in step-wise order)*

Generalised hyperhidrosis
Treat the underlying disorder, if present
Hormone-replacement therapy in menopausal hyperhidrosis
Anticholinergics
Focal hyperhidrosis
Treat the underlying disorder, if present
Local antiperspirants: aluminium chloride 20%, aluminium hydrochloride 15%
Anticholinergics
Iontophoresis
Botulinum toxin
Thoracoscopic sympathectomy
Local excision of skin and subcutis with sweat glands

CASE REPORT

A 56-year-old woman was referred by her general practitioner to our endocrinology outpatient clinic because of a four-year history of excessive sweating of her face and upper body. She had to wash and change clothes many times a day and could not leave the house without towels. The palms and soles remained dry. She had no flushing. Her last menstruation was three years ago. Her general practitioner (GP) considered climacterial hyperhidrosis, but she refused hormone-replacement therapy because her mother had had breast cancer. The sweating was continuous, had no diurnal variation and was not related to social situations. However, on presentation no sweating could be documented. Further extensive physical examination was also unremarkable. It appeared that the GP had started oxybutynin (2.5 mg three times daily) five days earlier because of urge incontinence. Since then, she had had no more complaints of excessive sweating. Underlying causes of hyperhidrosis, e.g. endocrinopathies, infections and malignancy, were excluded by blood testing and a chest X-ray. The diagnosis of idiopathic hyperhidrosis was made. We advised her to continue taking the oxybutynin. Six months later, she was still symptom-free.

DISCUSSION

Comment on the case report

This cases illustrates that hyperhidrosis is a socially embarrassing disorder with a profound effect on the patient's quality of life. Furthermore, it is striking how long hyperhidrosis usually exists before patients consult a doctor. This patient responded remarkably well to low-dose oxybutynin (brand name Dridase, named after its effect: 'dry days'). Oxybutynin is a parasympathicolytic drug with a spasmolytic effect on the detrusor muscle of the bladder due to antagonism of the muscarine receptors. Although the sweat glands are innervated by sympathetic postganglionic nerve fibres, they use acetylcholine, the neurotransmitter that is generally used exclusively by parasympathetic nerves (*figure 1*). Thus, the anticholinergic effect of oxybutynin is responsible for its effectiveness against excessive sweating.[7] Understanding of the mechanism of sweating and the first use of anticholinergics dates back to the 19th century, when it was accidentally discovered that elixirs from atropine plants improved hyperhidrosis.[8] Although today the effectiveness of oral anticholinergics in hyperhidrosis is commonly known, experience with oxybutynin in hyperhidrosis is limited: only anecdotal reports exist in the literature.[9] Oxybutynin is not approved for hyperhidrosis in Europe, explaining the unfamiliarity with this medicine. None of the anticholinergic drugs available in Europe are registered for use in hyperhidrosis. In the USA, glycopyrrolate

Figure 1. *Overview of the autonomous nervous system and effect of oxybutynin on the eccrine sweat glands*

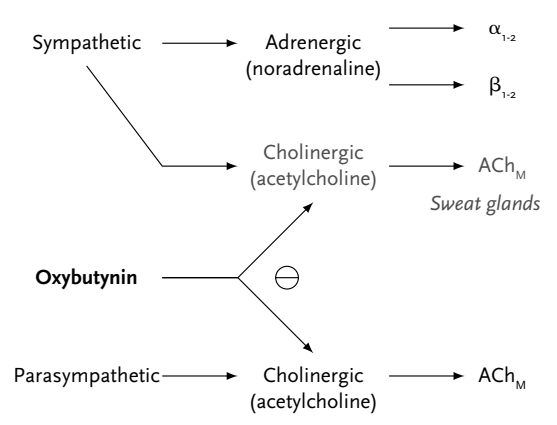

(Robinul) is available for this indication. The result in the above-mentioned patient suggests that oxybutynin, primarily indicated for urge incontinence, should be considered as a useful alternative. Potential side effects include dry mouth, constipation, nausea, blurred vision and urinary retention. The side effects of oxybutynin are mild as compared with other anticholinergics such as atropine. The statement that use of anticholinergics should not be recommended because of unacceptable side effects at dosages required for efficacy cannot be confirmed by our experience with this patient. During the six months' follow-up, dose increment was not necessary to maintain effectiveness. However, long-term use, although probably safe, is a major drawback for many patients and should not be recommended.[10] Because of its rapid resorption (T_{max} <1 hour), oxybutynin would also be suitable for use 'on demand', for example in specific social situations that provoke hyperhidrosis. A placebo-controlled clinical trial should be the next step to study the effectiveness and side effects of oxybutynin in a large group of patients with hyperhidrosis.

Current treatment options in hyperhidrosis: overview of the literature

The initial treatment of focal idiopathic hyperhidrosis[3-6] consists of local application of aluminium (hydro)chloride. If unsuccessful, an oral anticholinergic can be tried.

Axillary hyperhidrosis can be treated with en bloc excision of skin and subcutaneous tissue containing the sweat glands. However, this procedure is rarely performed because it is invasive and has a significant failure rate.

Iontophoresis is an effective treatment for palmoplantar hyperhidrosis. Iontophoresis involves immersion of the palms and/or soles in small basins filled with warm tap water and the use of a D/C generator that leads a low intensity electrical current (15 mA) through the water.[3,5] Charged ions are driven into the skin and temporarily disrupt the function of the sweat glands. Various devices are commercially available for home use. Treatment is time-consuming (multiple sessions are required per week), but safe, simple and effective in 85% of cases. Adding anticholinergics to the water can increase the effect.

Intradermal injections with botulinum toxin can by applied in axillary and palmar hyperhidrosis. Botulinum toxin inhibits the release of acetylcholine at the cholinergic synapse and binds to acetylcholine receptors at the synaptic end-plate.[2,7] The effect lasts for three to six months. Botulinum toxin is the first-line treatment of Frey's syndrome.

Severe therapy-resistant axillary or palmar hyperhidrosis can be treated surgically with an endoscopic thoracic sympathectomy.[11] This involves endoscopic removal of the sympathetic ganglia at Th2 for facial hyperhidrosis, Th2-3 for palmar hyperhidrosis and Th2-4 for axillary hyperhidrosis. The treatment is very effective (sweat control in 75 to 95% of patients) but is often complicated by compensatory sweating of the trunk and legs.[12,13]

In idiopathic generalised hyperhidrosis, a low-dose oral anticholinergic is the best available treatment. Other oral or systemic medications that have been tried include β-blockers, sedatives, antidepressants, clonidine, calcium antagonists and NSAIDs, but none have proven to be effective.

REFERENCES

1. Leung AKC, Chan PYH, Choi MCK. Hyperhidrosis. Int J Dermatol 1999;38:561-7.
2. Kreyden OP, Scheidegger EP. Anatomy of the sweat glands, pharmacology of botulinum toxin, and distinctive syndromes associated with hyperhidrosis. Clin Dermatol 2004;22:40-4.
3. Togel B, Greve B, Raulin C. Current therapeutic strategies for hyperhidrosis: a review. Eur J Dermatol 2002;12:219-23.
4. Hornberger J, Grimes K, Naumann M, et al. Recognition, diagnosis, and treatment of primary focal hyperhidrosis. J Am Acad Dermatol 2004;51:274-86.
5. Nyamekye IK. Current therapeutic options for treating primary hyperhidrosis. Eur J Vasc Endovasc Surg 2004;27:571-6.
6. Eisenach JH, Atkinson JLD, Fealey RD. Hyperhidrosis: evolving therapies for a well-established phenomenon. Mayo Clin Proc 2005;80:657-66.
7. Cheung JS, Solomon BA. Disorders of sweat glands: hyperhidrosis: unapproved treatments. Clin Dermatol 2002;20:638-42.
8. Ringer S. Some additional observations on the action of atropia on sweating. Practitioner 1872;9:224-5.
9. Van der Linden J, Sinnige HA, van den Dorpel MA. Gustatory sweating and diabetes. Neth J Med 2000;56:159-62.
10. Altman RS, Schwartz RA. Treatment of palmoplantar hyperhidrosis. Acta Dermatovenerologica Alpina, Pannonica et Adriatica 2002;11(1).
11. Doolabh N, Horswell S, Williams M, et al. Thoracoscopic sympathectomy for hyperhidrosis: indications and results. Ann Thorac Surg 2004:77:410-4.
12. Moya J, Ramos R, Vives N, et al. Compensatory sweating after upper thoracic sympathectomy. Prospective study of 123 cases. Arch Bronconeumol 2004;40:360-3.
13. Licht PB, Pilegaard HK. Severity of compensatory sweating after thoracoscopic sympathectomy. Ann Thorac Surg 2004;78:427-31.