

Antinuclear antibody (ANA) positivity caused by paraneoplastic antibodies due to abundant p53 expression in early hepatic carcinoma

R. Westra¹, T.L.Th.A. Jansen¹, A.S.H. Gouw², K.P. de Jong³

¹Department of Rheumatology, Medical Centre Leeuwarden, PO Box 888, 8901 BR Leeuwarden, the Netherlands, ²Department of Pathology and Laboratory of Medicine, University Hospital Groningen, Hanzeplein 1, 9713 GZ Groningen, the Netherlands, ³Department of Hepatobiliary Surgery, University Hospital Groningen, Hanzeplein 1, 9713 GZ Groningen, the Netherlands

ABSTRACT

A 51-year-old patient is described who presented with locomotor pain and highly significant positive ANA due to p53 antibodies, which appeared to be associated with primary hepatic carcinoma.

INTRODUCTION

In clinical oncology a diversity of tumour markers may be used, including α -fetoprotein (AFP) for hepatic carcinoma, carcino-embryonal antigen (CEA) for colorectal carcinoma and β -human chorion gonadotropin (β -hCG) for chorio-carcinoma. These markers are commonly applied in the follow-up of a specific tumour. For screening purposes, however, most of these markers cannot be used. In rheumatology antinuclear antibodies (ANA) may be used for screening purposes in several connective tissue diseases, particularly in systemic lupus erythematosus, but low ANA titres can be found in healthy individuals as well. ANA serology may become positive early in the course of some tumours due to tumour-associated antibodies. The patient presented here had a highly significant positive idiopathic ANA which turned out to be due to p53 antibodies. ANA may also be applied as a diagnostic marker in oncology.

CASE REPORT

A 51-year-old woman with no relevant medical history was seen at the Rheumatology Outpatient Department because

of persistent locomotor pain which had started five years before. Consultation of an orthopaedic surgeon and neurologist did not deliver an explanation nor a diagnosis. The locomotor pain worsened during exercise. There were no signs of arthritis, synovitis nor fever. She complained of fatigue, loss of energy (about 30%) and photosensitivity of the skin when exposed to sunlight. Family history was negative for any disease. Physical examination revealed no abnormalities of the thorax and abdomen. The locomotor system revealed some degenerative joint disease, compatible with her age, and no symptoms suggestive of arthritis or synovitis. Five out of 18 tender points according to criteria set by the American College of Rheumatology (ACR) were positive. An additional chest X-ray was normal. Laboratory examination revealed the following: erythrocyte sedimentation rate (ESR) 8 mm/hr (normal: <12 mm/hr), C-reactive protein (CRP) 5 mg/l (normal: <10 mg/l), haemoglobin 8.2 mmol/l (normal: >7.2 mmol/l), with further unremarkable haematology parameters. Renal and liver function tests: ASAT 20 U/l (normal: <45 U/l), ALAT 27 U/l (normal: <45 U/L), alkaline phosphatase 57 U/l (normal: <105 U/l), gamma-glutamyltranspeptidase 66 U/l (normal <35 U/l). Iron saturation was 36% (normal 15-50%). Because anamnesis suggested photosensitivity, antinuclear antigens were determined which were highly positive (titre 1:320) with a speckled pattern but without known specificity for extractable nucleolar antigens (ENA) nor antibodies to DNA or centromeres.

In conclusion, this 51-year-old woman presented with degenerative joint disease and enthesopathy, photosensitivity and a speckled ANA, so far without known

specificity. The differential diagnosis of idiopathic ANA positivity primarily consists of neoplastic or lymphoproliferative disorders as no signs were found for autoimmune disease. Abdominal ultrasonography was requested as the biochemistry was normal. Ultrasonography of the liver revealed an intrahepatic process with a diameter of 5 cm, suggestive of a hepatocellular carcinoma. Additional laboratory investigation revealed a normal AFP: 3 kU/l (normal: <8 kU/l). The patient was sent to an internist/hepatologist for biopsy of the intrahepatic lesion and further investigations.

An extensive oncological work-up was carried out, including computerised tomography (CT) of the abdomen, which revealed a solitary highly vascularised tumour in the left lower lobe of the liver. No signs were found of liver cirrhosis. A biopsy of the intrahepatic lesion confirmed the suspected hepatocellular carcinoma with a diameter of 8 cm with nine satellite metastases (figure 1). The patient was sent for a hepatobiliary procedure as the hepatic tumour appeared to be the primary process. Hemihepatectomy was performed aiming at a curative procedure. Six months later the patient was seen again at the outpatient department because of progressive pain due to enthesopathy: 16 of the 18 tender points were positive. Serological investigation revealed a positive ANA (titre 1:160). Recurrence of the hepatocellular carcinoma was suspected. At a three-monthly ultrasonogram the tumour indeed appeared to have recurred at the resection site, which was confirmed by CT scanning. Dissemination investigation was negative. Then treatment was started with ablative radiofrequency, aiming at lysis of tumour cells due to heating. Further investigation of the initial highly positive ANA revealed that there were circulating p53 antibodies.

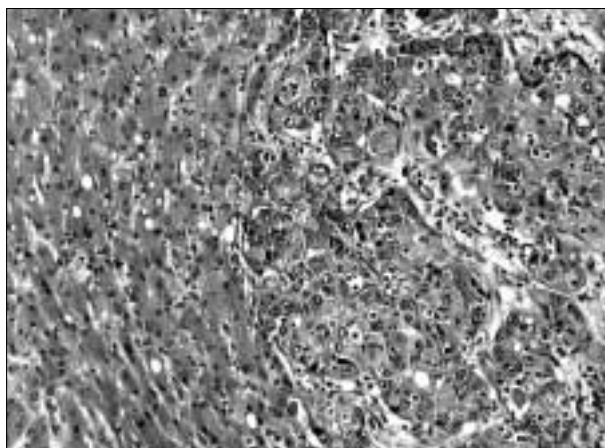


Figure 1
Microscopy of histology specimen: primary hepatocellular carcinoma

CONCLUSION

Tests for ANA are performed in an indirect immunofluorescence in cells derived from liver, kidney, possibly fibroblast or *in vitro* cultured nasopharynx carcinoma (Hep2). Most of these antibodies are directed against DNA- and/or RNA-protein complexes.^{1,2} In rheumatic diseases ANA is often determined to obtain the probability of autoimmune diseases such as systemic lupus erythematosus (SLE), Sjögren's disease, scleroderma or polymyositis.⁶ However low ANA titres may also be present in healthy persons: titres up to 1:80 occur in 13% of healthy individuals. This percentage of occurrence decreases to 3% for titres 1:320.^{7,8} Similar to other autoantibodies ANA seropositivity is age dependent: 36% of the elderly (i.e. over 65 years) are ANA positive.⁸ Cytoplasmatic and nuclear autoantibodies may also occur in malignancy,⁹⁻¹⁰ namely melanoma,¹¹ leukaemia,¹² lung carcinoma,¹³ breast cancer,¹⁴ gastrointestinal carcinoma,¹⁵ as well as nasopharyngeal carcinoma.¹⁶ In carcinomas 'single-stranded' DNA and histone proteins may behave as autoantigens. Most autoantigens in malignancy are

Table 1

Disorders associated with positivity for antinuclear antibodies (ANA)

RHEUMATIC DISORDERS

SLE (anti-DNA)	
Systemic sclerosis	(anti-scl70)
Sjögren's disease	(SSA/SSB)
Mixed connective tissue disease	(anti-RNP)
Poly-/dermatomyositis	(anti-Jo1)
RA (RF)	

CAUSES IN GENERAL MEDICINE

Infections: Pfeiffer's disease, <i>E. coli</i> , malaria
Gastrointestinal disorders: IBD, PBC, liver cirrhosis, hepatocellular carcinoma
Pulmonary disorders: lung fibrosis, pulmonary hypertension
Endocrinopathy: Graves' disease
Haematology disorders: AML, ALL, CML, Hodgkin's disease
Neoplasia: melanoma, lung, breast and nasopharyngeal carcinoma

PHYSIOLOGICAL CAUSES

Pregnancy
Ageing
Drug-induced: procainamide, hydralazine

SLE = systemic lupus erythematosus, RA = rheumatoid arthritis, anti-DNA = anti-deoxyribonucleic acid, SSA = Sjögren syndrome antigen A, SSB = Sjögren syndrome antigen B, RF = rheumatoid factor, IBD = inflammatory bowel disease, PBC = primary biliary cirrhosis, AML = acute myeloid leukaemia, ALL = acute lymphatic leukaemia, CML = chronic lymphatic leukaemia.

Table 2

Tumour-associated autoantibodies possibly determined by in vitro ANA testing^{7,8}

NUCLEIC PROTEINS	HEPATOCELLULAR CARCINOMA	LUNG CARCINOMA	BREAST CARCINOMA	OTHER
p53	+	+	-	Ovarian carcinoma
c-myc	-	+	+	SLE
c-myb	-	+	+	SLE
CENP-F	+	+	+	-
NOR-90	+	-	-	-
fibrillarin	+	-	-	-
B23	+	-	-	-

SLE = systemic lupus erythematosus.

still unknown, though during the last decade several nuclear antigenic epitopes have been recognised in primary hepatocellular carcinoma (HCC): fibrillarin and centromere protein p330^d/CENP-F, both of which are involved in processing precursor ribosomal RNA, and the non-snRNP splicing factor SC35, which is involved in splicing messenger RNA.⁷

Another important potentially antigenic protein is p53. In normal cells p53 is responsible for temporarily arresting cell growth in response to certain types of molecular and/or biochemical damage. Several types of damage, physiological stress included, act by way of the p53 protein to trigger a programme of apoptosis, i.e. programmed cell suicide, to eliminate the damaged cell. Elimination of functioning p53 appears to be sufficient to inactivate the apoptotic machinery in many cancer cells. In HCC patients p53 is expressed supraphysiologically in 12 to 32%.^{17,18} Characterisation of ANA specificities similar to these anti-p53-antibodies early in the course of tumours may help in understanding the processes involved in carcinogenesis. The immune response mechanism in carcinomas appears to have an antigen-driven character, in which abundant expression of antigenic target proteins plays a central role. In this process often mutant proteins with important cellular functions are involved.^{19,20} In both primary hepatic carcinoma and breast cancer, tumour size and ANA seropositivity have been described to be inversely interrelated.^{10,14} Patients with extensive disease are often cachectic and have a lower prevalence of ANA seropositivity.¹⁰ In 204 HCC patients, Covini *et al.* found ANA positivity in 31% (speckled pattern in 15%, nucleolar in 10%, homogeneous in 8%).¹⁰

The finding of a highly positive tumour-associated ANA, as in our patient, probably caused by p53 antibodies, is suggested in the literature to be a useful prognostic sign. As described earlier there is an association between idiopathic ANA and malignancy.¹⁰ Six months after the primary hemihepatectomy the tumour had recurred and the patient was ANA positive, at a much lower titre. It is questionable whether a recurrent positivity of the ANA

really suggests a poor prognosis, and this warrants further investigation.

In conclusion the presented case must not lead to over-estimation of the value of ANA.²¹ Clinicians must bear in mind that a highly significant ANA which cannot be explained rheumatologically may well be evoked by arousal of autoimmunity due to abundant p53 expression in carcinoma, for example in primary hepatic carcinoma. Prompt analysis and specific treatment may be worthwhile, particularly when very high ANA titres are found.

REFERENCES

1. Venrooij WJ van, Maini RN (eds). Manual of biological markers of disease, section B: Autoantigens. Dordrecht: Kluwer Academic Publishers, 1994.
2. Muhlen CA von, Tan EM. Autoantibodies in the diagnosis of systemic rheumatic diseases. *Semin Arthritis Rheum* 1995;24:323-58.
3. Reichlin M, Harley JB. Antinuclear antibodies: an overview. In: Dubois' Lupus erythematosus. 5th edition. Wallace DJ, Hahn BH (eds). Baltimore: Williams and Wilkins, 1997:397-405.
4. Rothfield NF, Stollar BD. The relation of immunoglobulin class, pattern of antinuclear antibody, and complement-fixing antibodies to DNA in sera from patients with systemic lupus erythematosus. *J Clin Invest* 1967;46:1785-92.
5. Schur PH, Sandson J. Immunologic factors and clinical activity in systemic lupus erythematosus. *N Engl J Med* 1968;278:533-8.
6. Slater CA, Davis RB, Shmerling RH. Antinuclear antibody testing: a study of clinical utility. *Arch Intern Med* 1996;156:1421-5.
7. Tan EM, Feltkamp TE, Smolen JS, et al. Range of antinuclear antibodies in 'healthy' individuals. *Arthritis Rheum* 1997;40:1601-11.
8. Forslid J, Heigl Z, Jonsson J, Scheynius A. The prevalence of antinuclear antibodies in healthy young persons and adults, comparing rat liver tissue sections with HEp-2 cells as antigen substrate. *Clin Exp Rheumatol* 1994;12:137-41.
9. Abu-Shakra M, Buskila D, Ehrenfeld M, Conrad K, Shoenfeld Y. Cancer and autoimmunity: autoimmune and rheumatic features in patients with malignancies. *Ann Rheum Dis* 2001;60:433-40.
10. Covini G, Muhlen CA von, Pacchetti S, Colombo M, Chan EKL, Tan EM. Diversity of antinuclear antibody responses in hepatocellular carcinoma. *J Hepatol* 1997;26:1255-65.

11. Thomas PJ, Kaur JS, Aitchison CT, Robinson WA, Tan EM. Antinuclear, antinucleolar, and anticytoplasmic antibodies in patients with malignant melanoma. *Cancer Res* 1983;43:1372-80.
12. Klein G, Steiner M, Wiener F, Klein E. Human leukemia-associated antinuclear reactivity. *Proc Natl Acad Sci USA* 1974;71:685-9.
13. Hodson ME, Turner-Warwick M. Autoantibodies in patients with bronchial carcinoma. *Thorax* 1975;30:367-70.
14. Wasserman J, Glas U, Blomgren H. Autoantibodies in patients with carcinoma of the breast. Correlation with prognosis. *Clin Exp Immunol* 1975;19:417-22.
15. Schattner A, Shani A, Talpaz M, Bentwich Z. Rheumatoid factors in the sera of patients with gastrointestinal carcinoma. *Cancer* 1983;52:2156-61.
16. Lamelin JP, De-The G, Revillard JP, Gabbiani G. Autoantibodies (cold lymphocytotoxins, antiactin antibodies and antinuclear factors) in nasopharyngeal carcinoma patients. *IARC Sci Publ* 1978;20:523-36.
17. Shiota G, Kishimoto Y, Suyama A, et al. Prognostic significance of serum anti-p53 antibody in patients with hepatocellular carcinoma. *J Hepatology* 1997;27(4):661-8.
18. Sitruk V, Vaysse J, Chevret S, et al. Prevalence and prognostic value of serum anti-p53 antibodies in hepatocellular carcinoma. *Gastroenterol Clin Biol* 2000;24(12):1159-63.
19. Volkmann M, Muller M, Hofmann WJ, et al. The humoral immune response to p53 in patients with hepatocellular carcinoma is specific for malignancy and independent of the alpha-fetoprotein status. *Hepatology* 1993;18:559-65.
20. Imai H, Ochs RL, Kiyosawa K, Furuta S, Nakamura RM, Tan EM. Nucleolar antigens and autoantibodies in hepatocellular carcinoma and other malignancies. *Am J Pathol* 1992;140:859-70.
21. Bernelot Moens HJ. Immunologie in de medische praktijk. XXI. Laboratoriumdiagnostiek van immunologische ziekten. *Ned Tijdschr Geneesk* 1999;143:2343.