

Acute abdomen and liver enzyme abnormalities

E. Nur^{1,2,3*}, A.B. Arntzenius³, N. Bokani⁴, W. Bruins-Slot³

¹Department of Internal Medicine, Slotervaart Hospital, Amsterdam, the Netherlands, ²Department of Internal Medicine, Academic Medical Center, Amsterdam, the Netherlands, Departments of ³Internal Medicine and Gastroenterology, ⁴Radiology, Spaarne Hospital, Hoofddorp, the Netherlands, *corresponding author: tel.: +31 (0)20-512 54 29, fax: +31 (0)20-691 97 43, e-mail: e.nur@amc.uva.nl

KEYWORDS

Acalculous cholecystitis, viral hepatitis, hepatitis B

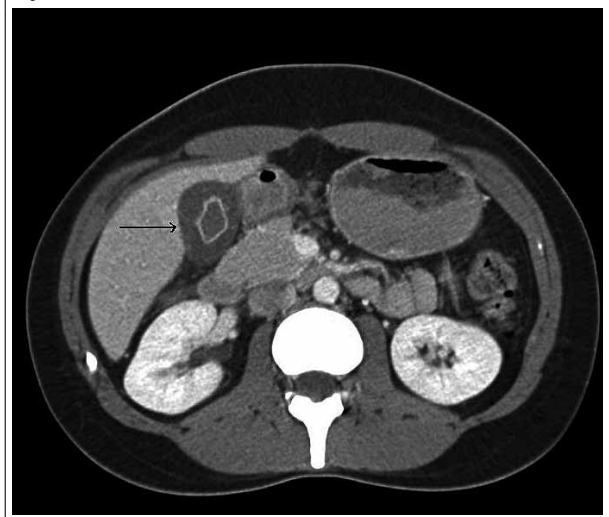
CASE REPORT

A 23-year-old woman of Turkish descent presented to our emergency department with severe pain in the epigastrium and right hypochondrium since three days. Accompanying symptoms were anorexia, nausea and vomiting. She had returned from a family visit in Turkey a few days earlier. Past medical and family histories did not reveal further relevant information.

On physical examination she was anicteric, ill, had no fever and there was right hypochondrial tenderness. There were also guarding, rebound tenderness and a positive Murphy's sign in the right upper abdomen.

Laboratory results showed elevated C-reactive protein (67 mg/l), total bilirubin (109 µmol/l), aspartate transaminase (2206 U/l), alanine transaminase (2646 U/l), lactate dehydrogenase (1174 U/l). Marked gallbladder wall thickening was seen on a post contrast computed tomography (CT) (*figure 1*).

Figure 1. CT-scan image of gallbladder wall thickening (arrow) during the course of an acute hepatitis B virus infection



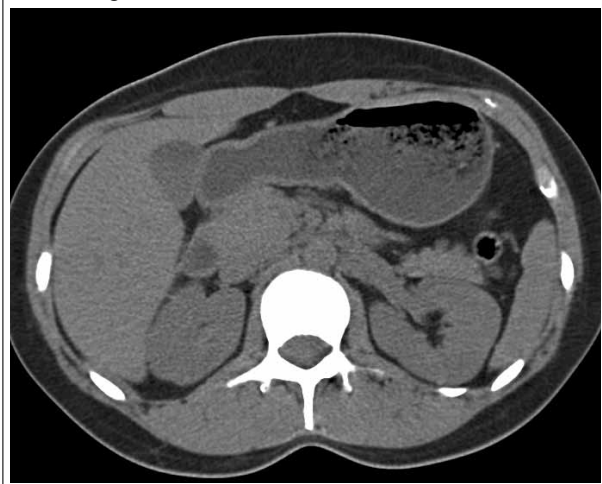
WHAT IS YOUR DIAGNOSIS?

See page 271 for the answer to this photo quiz.

DIAGNOSIS

CT imaging showed no stones in the gallbladder and there were no signs of (chronic) liver disease or dilatation of the bile duct and no splenomegaly. Viral serology revealed an acute hepatitis B virus (HBV) infection (HBsAg⁺, HBeAg⁺, IgM Anti-HBcAg⁺, Anti-HBsAg 13.7 IE/l, Anti-HBeAg⁺). The abdominal pain subsided during the hospital stay and made way for jaundice and pruritus and full clinical recovery, respectively. A second abdominal CT six weeks after discharge from hospital revealed full regression of the gallbladder wall thickening (figure 2). Repeated HBV serology, six months after the acute episode, showed the patient had cleared the virus and

Figure 2. Abdominal CT-scan image of the gallbladder after the acute episode of hepatitis B virus infection. Notice the complete regression of the gallbladder wall thickening



was immunised by natural infection (HBsAg⁻, HBeAg⁻, IgG anti-HBcAg⁺; anti-HBsAg 67 IE/ml; anti-HBeAg⁺). She had recently married and was probably infected by her husband as his serology showed a chronic HBV infection (HBsAg⁺, HBeAg⁻, IgM anti-HBcAg⁻, IgG anti-HbcAg⁺, Anti-HBsAg⁻, Anti-HBeAg⁺).

Symptomatic disease occurs in approximately 30% of patients with HBV infection. Some degree of right hypochondrial pain and tenderness, attributed to liver inflammation, is common with acute infectious hepatitis. An acute abdominal pain due to acalculous cholecystitis is a rare presentation of hepatitis and has been described primarily during the course of acute hepatitis A virus (HAV) infection.¹ Acute HBV infection presenting as acute acalculous cholecystitis has been described only twice before.^{2,3}

Though some gallbladder wall thickening is common in patients with (viral) hepatitis,⁴ possibly caused by hepatocyte necrosis, direct viral invasion and infection of the gallbladder are suggested to be the cause of acute acalculous cholecystitis.¹

REFERENCES

1. Mourani S, Dobbs SM, Genta RM, Tandon AK, Yoffe B. Hepatitis A virus-associated cholecystitis. *Ann Intern Med.* 1994;120(5):398-400.
2. Unal H, Korkmaz M, Kirbas I, Selcuk H, Yilmaz U. Acute acalculous cholecystitis associated with acute hepatitis B virus infection. *Int J Infect Dis.* 2009;13(5):e310-2.
3. Singh DS, Saxena SR, Singh AK, Gambhir IS. Acute non-calculus cholecystitis in virus B hepatitis. *J Indian Med Assoc.* 1996;94(2):66, 75.
4. Juttner HU, Ralls PW, Quinn MF, Jenney JM. Thickening of the gallbladder wall in acute hepatitis: ultrasound demonstration. *Radiology.* 1982;142(2):465-6.