

Emphysematous pyelonephritis in a renal transplant patient

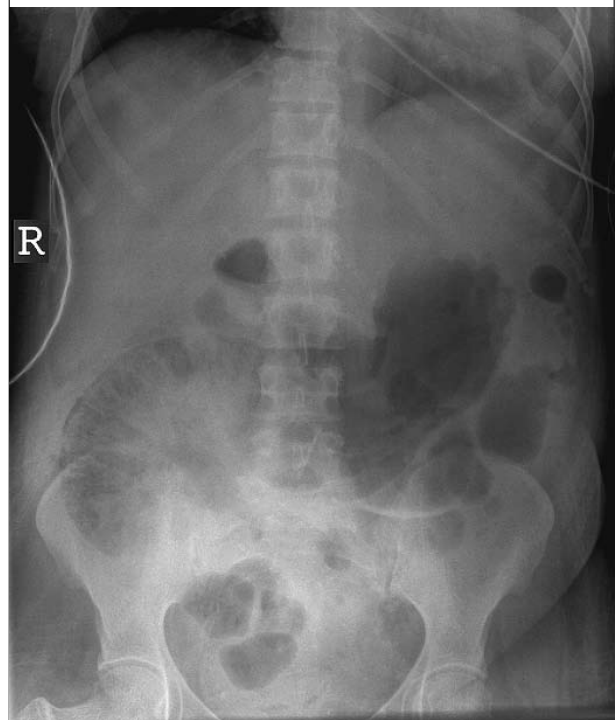
M.C. Baas*, K.A.M.I. van Donselaar-van der Pant, F.J. Bemelman

Renal Transplant Unit, Department of Nephrology, Academic Medical Centre, Amsterdam, the Netherlands, *corresponding author: tel.: +31 (0)20-566 59 90, fax: +31 (0)20-566 92 41, e-mail: m.c.baas@amc.uva.nl

CASE REPORT

A 60-year-old woman, who had received a post-mortal donor renal transplant six weeks ago because of unknown end-stage renal disease, was re-admitted because of fever. Her post-transplant course had been complicated by steroid-induced diabetes mellitus and bladder retention for which she had learned self-catheterisation. Immunosuppressive therapy consisted of prednisolone, tacrolimus and mycophenolate-sodium. On admission, she complained of general malaise and fever for the last 24 hours. On physical examination, she was disoriented and hypotensive with a temperature of 38.4°C. The abdomen was distended and high pinched bowel sounds were heard. The renal transplant in the right iliac fossa was slightly tender on palpation. Laboratory investigation demonstrated a rise in plasma creatinine from 93 $\mu\text{mol/l}$ to 539 $\mu\text{mol/l}$; C-reactive protein was 390 mg/l and leucocytes were $15.8 \times 10^9/\text{l}$. Urinary sediment showed >20 leucocytes/high power field. An abdominal X-ray was performed because concomitant ileus was suspected (*figure 1*).

Figure 1. Abdominal X-ray (137 x 161 mm)



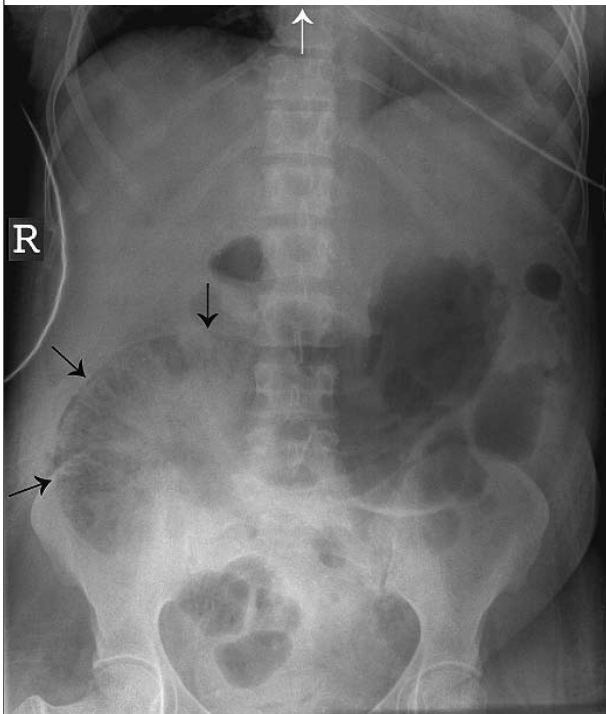
WHAT IS YOUR DIAGNOSIS?

See page 404 for the answer to this photo quiz.

DIAGNOSIS

The abdominal X-ray revealed subcapsular and parenchymatous air accumulation in the renal transplant (figure 2, black arrows). This is compatible with the diagnosis of emphysematous pyelonephritis. She was

Figure 2. Abdominal X-ray revealing subcapsular and parenchymatous air accumulation in the renal transplant located in the right iliac fossa (black arrows)



admitted to the intensive care unit, where she became anuric and dependent on vasopressive medication. Despite antibiotic treatment with vancomycin and gentamicin, based on previous urine cultures, a transplantectomy had to be performed 24 hours after admission, due to ongoing haemodynamic instability. Cultures from blood, urine and the transplant tissue showed growth of *Escherichia coli*, susceptible to the prescribed antibiotics. After transplantectomy, the clinical condition of the patient improved rapidly. However, the postoperative course was complicated by recurrent abscesses for which prolonged treatment with antibiotics and repetitive drainage were necessary.

Emphysematous pyelonephritis is a rare, but serious complication after renal transplantation. Only 15 cases, not including our patient, have been reported so far.¹ It is a gas-producing infection of the kidney and peri-renal tissue, most often caused by *E. coli* or *Klebsiella pneumoniae*. As with emphysematous pyelonephritis of native kidneys, the presence of diabetes mellitus is known to be a major risk factor for its development in renal transplant recipients. In 13 of the 15 reported cases diabetes was present,¹ as in our patient. The mortality is high. Nephrectomy is almost always necessary.

REFERENCE

1. Schmidt S, Foert E, Zidek W, van der Giet M, Westhoff TH. Emphysematous pyelonephritis in a kidney allograft. *Am J Kidney Dis.* 2009;53:895-7.