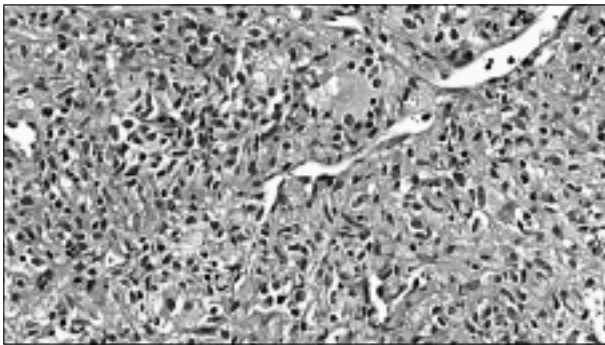


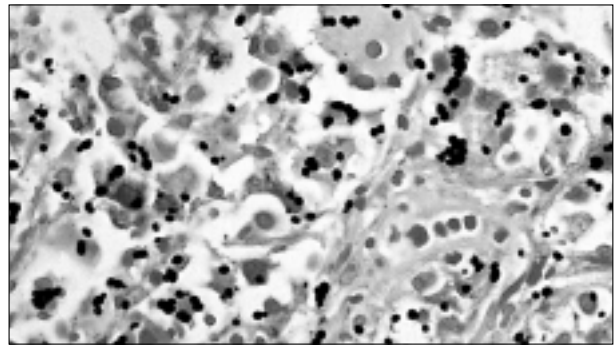
ANSWER TO PHOTO QUIZ (ON PAGE 49)

BILATERAL ADRENAL TUMOUR

The clinical presentation and normal urinary excretion of catecholamines ruled out pheochromocytoma. The final diagnosis was made from a CT-guided biopsy of the adrenal gland, showing granulomas, lymphohistiocytic aggregates (figure 2) and micro-organisms that were identified as yeasts (figure 3).



**Figure 2**  
Adrenal biopsy showing clusters of histiocytes with a few multinucleated giant cells (H&E, 200x)



**Figure 3**  
Multiple yeasts within histiocytes, consistent with *Histoplasma capsulatum* (Grocott, 400x)

Initially the tissue was not sent in for culture. The snap frozen material was cultured, but the cultures remained negative. Leishmaniasis was ruled out morphologically and based on the presence of budding organisms. Morphology and measurements of the organisms (2-5  $\mu\text{m}$ ) left a differential diagnosis of *Candida albicans*, *Candida glabrata* and *Histoplasma capsulatum*. Since the organisms were mainly present within histiocytes a diagnosis of generalised *C. glabrata* infection was unlikely. *C. albicans* was thought to be less likely, because of the absence of pseudohyphae and the mainly intracytoplasmic localisation of the micro-organisms. Therefore, the preferred diagnosis was that of a disseminated *Histoplasma capsulatum* infection.

Repeated questioning revealed that this patient frequently travelled to areas in Indonesia with many bat caves, although his last visit was two years ago. He was tested HIV negative and his cellular immunity was normal. After supplementation of cortisol and treatment with itraconazol his clinical condition improved rapidly and his symptoms resolved. After six months of treatment the adrenal glands were reduced to their normal size.

## CONCLUSION

Adrenal tumours larger than 4 cm are highly suspect for malignancy.<sup>1,2</sup> Although disseminated histoplasmosis with bilateral adrenal gland involvement and adrenal insufficiency is very rare in western Europe, this case shows that bilateral enlargement of the adrenal glands of more than 4 cm is not by definition malignant, and hormonal testing and histology are imperative.

## REFERENCES

1. Kasperlik-Zeluska AA, Roslonowska E, Slowinska-Srzednicka J, et al. Incidentally discovered adrenal mass incidentaloma: investigation and management of 208 patients. *Clin Endocrinol (Oxf)* 1997;46(1):29-37.
2. Mantero F, Terzolo M, Arnaldi G, et al. A survey on adrenal incidentaloma in Italy. Study Group on Adrenal Tumors of the Italian Society of Endocrinology. *J Clin Endocrinol Metab* 2000;85(2):637-44.
3. Shu KN, Anekthanaon T, Marius PR. Gastrointestinal histoplasmosis in patients with AIDS: case report and review. *Clin Infect Dis* 2001;32(3):483-91.
4. Giacaglia LR, Lin CJ, Lucon AM, Goldman J. Disseminated histoplasmosis presenting as bilateral adrenal masses. *Rev Hosp Clin Pac Med Soa Paulo* 1998;53(5):254-6.