

Whipple's disease: easily diagnosed, if considered

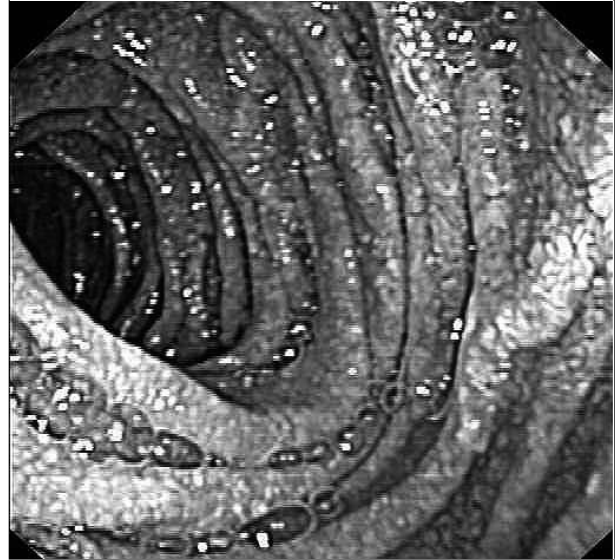
Dear Editor,

We read with interest the article by Schijf *et al.* 'Whipple's disease: easily diagnosed, if considered'.¹ The diagnosis of Whipple's disease can be difficult if not considered and may even include a diagnostic laparotomy for suspicion of retroperitoneal lymphoma.² But even if the diagnosis is considered it may not be easy. We describe a patient in whom duodenal biopsies showed only one granuloma on microscopic examination, but in whom biopsies of jejunal mucosa showed typical changes consistent with Whipple's disease.

In 2006, a 36-year-old male presented to the outpatient clinic with arthralgia, diarrhoea, weight loss, iron deficiency anaemia and retroperitoneal lymphadenopathy. Gastroduodenoscopy and colonoscopy were performed. Both showed a completely normal appearance of the duodenal and colonic mucosa. Histological examination of the duodenal biopsy showed one granuloma. Tuberculosis, HIV, *Treponema pallidum* haemagglutination assay, Brucellosis, Q-fever, cytomegalovirus and toxoplasmosis were excluded. Sarcoidosis, and autoimmune disorders were all considered but could not be diagnosed. As sarcoidosis of the stomach and duodenum is described as a separate entity, corticosteroid treatment was initiated but without clinical improvement. The patient's anaemia worsened and his weight decreased further.

Then we considered Whipple's disease. As proximal enteroscopy can be misleading we performed jejunoscopy. The duodenal mucosa was normal but the jejunal mucosa was abnormal, showing a whitish reticular pattern consistent with dilated lymphatic vessels (figure 1). Microscopic examination showed foam cells in the villi and lamina propria, consistent with Whipple's disease. Polymerase chain reaction for *Thropheryma whipplei* was positive. Antibiotic treatment sulfamethoxazole-trimethoprim twice daily resulted in a full recovery. After one year, treatment was discontinued and to date no signs of relapse have occurred.

Figure 1. Jejunal mucosa showing a whitish reticular pattern consistent with dilated lymphatic vessels



When suspecting a diagnosis of Whipple's disease proximal endoscopy can be misleading. Jejunal biopsies should always be performed.

S.M. Sanavro*, H.J. Voerman

Amstelland Hospital, Amstelveen, the Netherlands,

**corresponding author: tel.: +31 (0)20-347 47 47, e-mail: sannesarro@hotmail.com*

REFERENCES

1. Schijf LJ, Becx MCJM, de Bruin PC, van der Vegt SGL. Whipple's disease: easily diagnosed, if considered. *Neth J Med.* 2008;66:392-5.
2. Stampfl DA, Grimm IS, Barbot DJ, Rosato FE, Gordon SJ. Sarcoidosis causing duodenal obstruction. Case report and review of gastrointestinal manifestations *Dig Dis Sci.* 1990;35(4):526-32.