

Microscopic colitis: an unfamiliar but treatable disease

E.J. van der Wouden^{1,3*}, A. Karrenbeld², J.H. Kleibeuker³, G. Dijkstra³

¹Department of Gastroenterology, Isala Clinics, PO Box 10400, 8000 GK Zwolle, the Netherlands, ³Department of Gastroenterology and ²Pathology, Groningen University Medical Centre, Groningen, the Netherlands, *corresponding author: tel.: +31 (0)38-424 57 58, fax: +31 (0)38-424 30 56, e-mail: e.j.van.der.wouden@isala.nl

ABSTRACT

Chronic diarrhoea is a frequent complaint in clinical practice. Microscopic colitis is the cause of this symptom in 10% of these cases and the prevalence is rising. To exclude microscopic colitis a colonoscopy with multiple biopsies of different regions of the colon is mandatory. A sigmoidoscopy alone is insufficient. Two histopathological types of microscopic colitis can be distinguished: collagenous colitis and lymphocytic colitis. Nowadays, there is sufficient evidence to recommend budesonide as the first-choice treatment. Bismuth can also be recommended, but this drug is not easily available in the Netherlands. Evidence of efficacy of other drugs is scant.

KEYWORDS

Bismuth, budesonide, collagenous colitis, lymphocytic colitis, microscopic colitis

INTRODUCTION

Chronic diarrhoea is a common complaint in the daily practice of the general practitioner, internist and gastroenterologist. While the exact prevalence of chronic diarrhoea in the general population is unknown, epidemiological data from the United States of America estimate it at 5%.^{1,2} Chronic diarrhoea can be defined in a number of different ways. First, the diarrhoea must be present for longer than four weeks. Additionally, depending on the definition used, defecation frequency must be increased (more than three times daily), consistency must be decreased (porridge-like to watery) and/or the mass of stool must increase (more than 200 grams a day).³

Chronic diarrhoea must be distinguished from irritable bowel syndrome and faecal incontinence. In irritable bowel syndrome, chronic abdominal pain is predominant, accompanied by an altered defecation pattern that may be dominated by diarrhoea. Patients with faecal incontinence often initially present their complaints as diarrhoea, making careful history-taking essential in these cases. The differential diagnosis of chronic diarrhoea is very extensive, and includes chronic bowel infections, inflammatory bowel disease, and malabsorption syndromes (such as coeliac disease and lactose intolerance).³ A less well-known cause of chronic diarrhoea is microscopic colitis.⁴ However, making this diagnosis remains difficult, and watchfulness is required from the internist, gastroenterologist and pathologist. Additionally, the prevalence of this condition is rising and its treatment has recently become clearer. Therefore, we will present four patients with microscopic colitis and discuss the diagnosis and treatment of this disease.

CASE REPORTS

Patient A, a 44-year-old woman, presented in 1999 with a history of diarrhoea lasting for a number of years. Other than chronic back pain and pyrosis due to reflux oesophagitis, she had no significant past medical history. She only took loperamide as needed. She reported passing porridge-like to watery stools six to eight times daily, without blood or mucus. She had also lost a number of kilograms of weight. Additionally, she was sometimes incontinent, which was socially disabling. Physical examination and preliminary laboratory investigations did not reveal any abnormalities. Colonoscopy did not show any

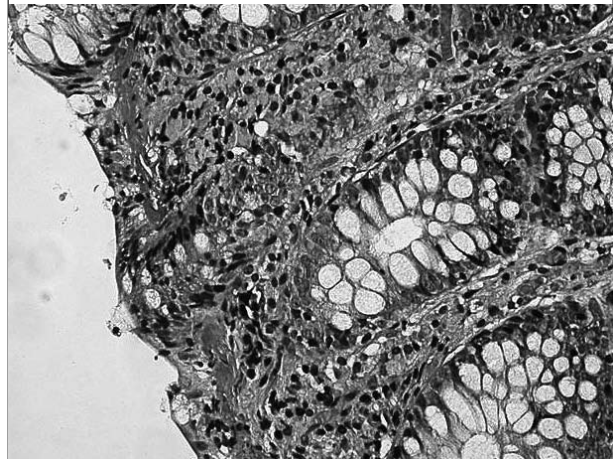
visible abnormalities. However, randomly taken biopsies of macroscopically normal mucosa showed collagenous colitis. Treatment with mesalazine and bismuth subcitrate did not lead to any improvement in her symptoms. Initially, her complaints improved somewhat following treatment with beclomethasone enemas and loperamide, with porridge-like stools two to three times daily without incontinence. Four years later, however, her symptoms increased, with watery stools six to eight times daily. She was now treated with 9 mg of budesonide a day, which resolved her symptoms, with normal stools once to twice daily. Unfortunately, the budesonide could not be completely tapered off, and she continued maintenance therapy of 3 mg of budesonide a day. She was symptom-free during her last check-up in April 2007.

Patient B is a 40-year-old man who presented to our hospital in 2001 for a second opinion for chronic unexplained diarrhoea. His past medical history included trauma with a clavicle and pelvic fracture and a stomach perforation. He also had a history of gout complicated by a urate nephropathy, with a creatinine clearance of 70 ml/minute. He also had psoriasis. He was taking a variety of drugs, but stopping these medications did not lead to any improvement in his symptoms. His chronic diarrhoea had been investigated in various hospitals. Extensive diagnostic procedures had been performed: exhaustive laboratory examinations, a gastroduodenoscopy with small bowel biopsies, a lactose breath test, and repeated colonoscopies with biopsies, none of which had resulted in a diagnosis. One colonoscopy, however, did reveal a number of nonspecific lesions in the distal colon, upon which treatment with mesalazine and 10 mg of prednisone was initiated. When his symptoms failed to significantly improve, he was referred to our hospital.

He reported watery stools six to eight times daily, without blood or mucus, and without incontinence. There was no weight loss. Physical examination and preliminary laboratory investigations once again did not contribute to the diagnosis. Colonoscopy was repeated, during which macroscopically normal mucosa was seen. Pathology of randomly taken colon biopsies showed collagenous colitis (*figure 1*). However, treatment with 9 mg of budesonide a day, loperamide and cholestyramine did not improve his symptoms. He was subsequently treated with bismuth subcitrate for eight weeks. Following this treatment, he had solid stools once daily. He was still symptom-free during a recent check-up 18 months after the bismuth treatment.

Patient C, a 44-year-old man, presented to the outpatient clinic of our hospital with chronic diarrhoea. Other than a cervical laminectomy, he had no past medical history. He was not on any drugs. He reported a long period of passing porridge-like to watery stool five times daily, without blood

Figure 1. Colon biopsies from patient A

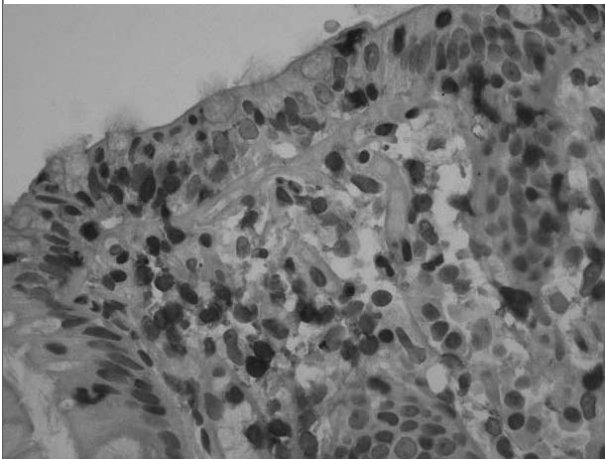


The Masson stain, in which the collagen is stained blue, shows the significantly thickened basal membrane as a sub-epithelial band. The image is of a collagenous colitis.

or mucus, and having lost a number of kilograms. Physical examination and laboratory investigations did not reveal any abnormalities. Colonoscopy revealed normal mucosa everywhere, although randomly taken biopsies showed collagenous colitis. Treatment with 9 mg of budesonide had a positive effect on his symptoms. Unfortunately, tapering off the budesonide quickly resulted in a relapse of his symptoms. He ultimately received maintenance therapy of 6 mg budesonide daily for a number of years. In early 2005, the decision was made to initiate an eight-week test treatment with bismuth subcitrate. He subsequently became symptom-free and budesonide treatment was stopped. During his last check-up in November 2005, he was still passing normal stools once to twice daily.

A 37-year-old man, patient D, was referred due to chronic diarrhoea in 2002. Other than asthma, and arthroscopies of both his left and right knee, he had no past medical history. He used salmeterol and salbutamol inhalers. Other than the chronic diarrhoea, which consisted of porridge-like stools without blood or mucus several times a day, he had no other symptoms. Physical examination and preliminary laboratory investigations did not point to any diagnosis. A gastroduodenoscopy revealed mild reflux oesophagitis, but pathology showed normal small bowel biopsies. Colonoscopy showed normal mucosa. Randomly sampled colon biopsies, however, showed a lymphocytic colitis (*figure 2*). He was treated with 9 mg of budesonide daily, upon which his symptoms disappeared. His symptoms quickly returned upon tapering off the budesonide. He was therefore treated with the lowest effective dose of budesonide: 3 mg every other day. As he remained steroid-dependent, an attempt was made to switch treatment to loperamide

Figure 2. Colon biopsies from patient C



The CD3 stain, in which the lymphocytes are stained brown, shows an increase in lymphocyte numbers (particularly between the epithelial cells). The image is of a lymphocytic colitis.

and cholestyramine in 2003, but this did not result in sufficient symptom alleviation. Treatment with bismuth subcitrate in 2004 was curtailed by the patient due to a lack of effectiveness. He has since been taking 3 mg of budesonide every other day alongside psyllium fibres, and remains symptom-free.

CLINICAL PRESENTATION

Patients with microscopic colitis typically have chronic porridge-like or watery diarrhoea without blood or mucus. Defecation frequency generally lies somewhere between four and nine times daily, with a faecal mass of between 300 and 1700 grams a day.⁵ Abdominal cramps, weight loss and faecal incontinence can also occur. Patients may present with dehydration, but this is uncommon. The clinical course is variable, with episodes of spontaneous improvement and exacerbation. Complications do not arise. Microscopic colitis occurs at all ages in both men and women, but is slightly more common in middle-aged women. Both Spanish as well as Swedish epidemiological studies estimated prevalence at around 10% of all patients with chronic diarrhoea.^{6,7} Additionally, various studies indicate the prevalence is rising, although it cannot be excluded that the observed rising prevalence in these studies is due to an increased awareness by clinicians and does not reflect a true rise in incidence.^{6,8} Laboratory investigations do not contribute to the diagnosis. Endoscopic investigations also practically never show macroscopic abnormalities, although minimal oedema and a few atypical ulcers of the mucosa have been described (patient B).^{9,10} The microscopic abnormalities are diffuse and variably located in the colon, making it necessary to take multiple biopsies from various regions in the

colon during endoscopic investigations. Performing a sigmoidoscopy with biopsies alone would lead to a missed diagnosis in 40% of cases.^{7,11}

PATHOLOGY

Pathological examination distinguishes two forms of microscopic colitis: collagenous colitis and lymphocytic colitis. Both forms may occur independently as well as concurrently. The basal membrane or basal lamina is thickened in collagenous colitis, which is microscopically visible as a varyingly wide sub-epithelial collagenous band (*figure 1*, patient A). The basal lamina is normally thinner than 7 μm ; in collagenous colitis, it is more than 10 μm , and usually between 20 and 60 μm , thick.¹¹ Lymphocytic colitis is defined as an increase in the number of intra-epithelially located mononuclear inflammatory cells to more than 20 per 100 epithelial cells (*figure 2*, patient C). Slight flattening of the epithelial cells, a decrease in the number of goblet cells and an increase in the number of paneth cells may occur in both forms of the disease. Mild cryptitis is also possible. For the microscopic diagnosis of microscopic colitis the haematoxylin and eosin stain is sufficient in most cases. However, the Masson stain or trichrome stain can be used to highlight the sub-epithelial collagenous band in collagenous colitis and a CD13 immunostain is available to show the intraepithelial lymphocytes in lymphocytic colitis (*figures 1 and 2*).

AETIOLOGY AND DIFFERENTIAL DIAGNOSIS

The cause of microscopic colitis remains unclear. It is thought to be the result of an abnormal immune response to bowel contents (bacterial toxins, medicinal products, food) or of abnormal collagen metabolism. There is an association between autoimmune disease and microscopic colitis.¹² Additionally, there seems to be an association between the use of non-steroidal anti-inflammatory drugs (NSAIDs) and collagenous colitis, as a result of which use of these medicinal products is discouraged in patients with this condition.¹³ Recently, an association between selective serotonin reuptake inhibitors and statins and microscopic colitis has been described and patients using these drugs may benefit from an attempt of drug withdrawal.¹⁴ An increased production of nitrogen oxide (NO) seems to play a role in the diarrhoea. Administration of a nitrogen oxide synthase inhibitor decreases net secretion, while administration of the substrate L-arginine leads to an increase in secretion.¹⁵ The differential diagnosis should distinguish the microscopic pathology of microscopic colitis from inflammatory bowel disease (specifically, Crohn's disease). However, the distinction between inflammatory

bowel disease and microscopic colitis can generally be made on clinical grounds. A number of case studies and small patient series showed an association between coeliac disease and lymphocytic colitis. Ruling out coeliac disease is thus recommended in this patient population.¹⁶

TREATMENT

Since the first description of microscopic colitis by Lindstrom in 1976, single uncontrolled case studies have been published describing various therapies for treating the condition.¹⁷ These treatment modalities include steroids (systemic and topical), 5-amino-salicylic acid preparations, cyclosporin, 5-mercaptopurine, azathioprine, fibre compounds, spasmolytic agents, loperamide, probiotics and surgery.¹⁸ These publications have led to placebo-controlled studies with probiotics, a plant extract, bismuth and budesonide. These studies were recently summarised in a meta-analysis.¹⁸ Only one small study examining the use of probiotics was included. In this study, 21 patients used a combination of *Lactobacillus acidophilus* and *Bifidobacterium animalis* subspecies *Lactis* and eight patients were treated with placebo. No statistically significant difference was found between the two groups: 6/21 vs 1/8 noticed some effect, but this may have been due to a type 2 error.¹⁹ Another small placebo-controlled study with a plant extract was also negative.²⁰

Bismuth

Bismuth preparations are commonly prescribed for diarrhoea in the United States. Indications for the effectiveness of bismuth in the treatment of microscopic colitis were found in numerous case studies and one uncontrolled study.²¹⁻²⁴ In the uncontrolled study, 12 patients were treated with eight 262 mg tablets of bismuth subsalicylate a day for eight weeks. Complete remission was achieved in 11 patients. No significant side effects were noted.²⁵ This was confirmed by a small placebo-controlled study. This study was included in the cited meta-analysis.¹⁸ In this study, bismuth subsalicylate was given to four patients at a dose of three 262 mg tablets a day for eight weeks, while five patients received placebo tablets. Only the actively treated group responded to therapy. No notable side effects were found in this study, either.²⁶ However, bismuth subsalicylate is not available in the Netherlands. Bismuth subcitrate, as used in the cases described above, is also no longer authorised or available in the Netherlands. However, bismuth subnitrate is still available via pharmaceutical wholesalers and the production of capsules can be performed easily by every pharmacy in the Netherlands. The equivalent dose of bismuth subnitrate is 600 mg thrice daily for eight weeks. Bismuth is hardly absorbed when administered orally. However, a treatment duration

of no longer than eight weeks is recommended to prevent accumulation in the body. The most important side effect of bismuth is black stools.

Steroids

The use of systemic steroids for the treatment of microscopic colitis has been described in numerous case studies and small patients series.¹⁸

However, only a single, very small, placebo-controlled study with systemic steroids has been published and described in the above-mentioned meta-analysis. Improvements were noted in seven of the nine patients treated with prednisolone 50 mg once daily for two weeks. By comparison, only one of the three patients treated with a placebo showed improvement. However, this was not statistically significant in this small study.²⁶ The significant disadvantage of systemic steroids is the well-known side-effect profile, which does not seem to outweigh the benefits for a 'benign' condition such as microscopic colitis. Budesonide is a glucocorticoid that is quickly absorbed after oral administration, but is quickly and effectively metabolised by the liver, so it barely enters systemic circulation. Delayed release preparations have been proven to be effective in patients with Crohn's disease in administering a local dose in the bowel with minimal systemic side effects.²⁷ This compound has been used in a variety of uncontrolled studies and case reports of microscopic colitis.¹⁸ However, three randomised, double-blind, placebo-controlled studies have also since been published and analysed in the meta-analysis.^{18,28-30} A total of 94 patients were included in these studies. A total of 38 of the 47 patients (81%, 95% confidence interval 70 to 92%) responded to budesonide, compared with eight out of the 47 (17%, 95% confidence interval 6 to 28%) treated with placebo. The number needed to treat was determined to be only two. Additionally, there were significant histological and quality of life improvements.¹⁸ The dose of budesonide used was, depending on the brand of medicinal products used, three 3 mg tablets once daily (Entocort®) or one 3 mg tablet thrice daily (Budenofalk®) for six weeks, after which the dose was slowly tapered off by 3 mg per four to six weeks. The natural history of microscopic colitis is variable and recurrences are frequent. Unfortunately, exacerbation during the tapering-off period or after stopping budesonide treatment is, therefore, common, so many patients remain dependent on a low dose of budesonide.³¹

CONCLUSION

Microscopic colitis is the cause of chronic diarrhoea in 10% of all cases, and its prevalence is rising. Microscopic colitis is a distinct clinical-pathological entity that includes both lymphocytic colitis and collagenous colitis. As the mucosa appears normal at colonoscopy, the analysis of chronic

diarrhoea should include active searching for this condition by performing multiple biopsies from various regions of the colon. As diagnostic yield may be higher from the right side of the colon, sigmoidoscopy alone is not sufficient. Most of the data regarding the treatment of microscopic colitis favour the use of budesonide. There are now also sufficient indications for the effectiveness of bismuth to justify its use. However, the use of bismuth preparations is complicated by the practical difficulties of its availability in the Netherlands. There is limited evidence for the use of other drugs. Given their side-effect profiles, loperamide, spasmolytic agents and fibre preparations are the prime contenders in this category. Finally, the use of NSAIDs should be avoided in patients with microscopic colitis.

REFERENCES

1. Talley NJ, O'keefe EA, Zinmeister AR, Melton LJ 3d. Prevalence of gastrointestinal disorders in the elderly: a population based study. *Gastroenterology* 1992;102:895-901.
2. Talley NJ, Weaver AL, Zinmeister AR, Melton LJ 3d. Onset and disappearance of gastrointestinal symptoms and functional gastrointestinal disorders. *Am J Epidemiol.* 1992;136:165-77.
3. Fine KD, Schiller LR. AGA technical review: evaluation and management of chronic diarrhea. *Gastroenterology.* 1999;116:1464-86.
4. Honkoop P, Ouwendijk RJ, Giard RWM, Bac DJ. Collagene colitis: macroscopisch onzichtbaar, maar niet onbehandelbaar. *Ned Tijdschr Geneesk.* 2003;147:353-6.
5. Bo-Linn GW, Vendrell DD, Lee E, Fordtran JS. An evaluation of the significance of microscopic colitis in patients with chronic diarrhea. *J Clin Invest.* 1985;75:1559-69.
6. Olesen M, Eriksson S, Bohr J, Jarnerot G, Tysk C. Microscopic colitis: a common diarrhoeal disease. An epidemiological study in Orebro, Sweden, 1993-1998. *Gut.* 2004;53:346-50.
7. Fernandez-Banares F, Salas A, Forne M, Esteve M, Espinos J, Viver JM. Incidence of collagenous and lymphocytic colitis: a 5 year population-based study. *Am J Gastroenterol.* 1999;94:418-23.
8. Pardi DS, Loftus EV Jr, Smyrk TC, et al. The epidemiology of microscopic colitis: a population based study in Olmsted County, Minnesota. *Gut.* 2007;56:504-8.
9. Carpenter HA, Tremaine WJ, Batts KP, Czaja AJ. Sequential histologic evaluations in collagenous colitis. Correlations with disease behaviour and sampling strategy. *Dig Dis Sci.* 1992;37:1903-9.
10. Tanaka M, Mazzoleni G, Riddell RH. Distribution of collagenous colitis: utility of flexible sigmoidoscopy. *Gut.* 1992;33:65-70.
11. Thijs WJ, van Baarlen J, Kleibeuker JH, Kolkman JJ. Microscopic colitis: prevalence and distribution throughout the colon in patients with chronic diarrhoea. *Neth J Med.* 2005;63:137-40.
12. Snook J. Are the inflammatory bowel diseases autoimmune disorders? *Gut.* 1990;31:961-3.
13. Riddell RH, Tanaka M, Mazzoleni G. Non-steroidal anti-inflammatory drugs as a possible cause of collagenous colitis: a case-control study. *Gut.* 1992;33:683-6.
14. Fernandez-Banares F, Esteve M, Espinos JC, et al. Drug consumption and the risk of microscopic colitis. *Am J Gastroenterol.* 2007;102:324-330.
15. Perner A, Andresen L, Normark M, et al. Expression of nitric oxide synthases and effects of L-arginine and L-NMMA on nitric oxide production and fluid transport in collagenous colitis. *Gut.* 2001;49:387-94.
16. Freeman HJ. Collagenous colitis as the presenting feature of biopsy-defined celiac disease. *J Clin Gastroenterol.* 2004;38:664-8.
17. Lindstrom CG. 'Collagenous colitis' with watery diarrhoea – a new entity? *Pathol Eur.* 1976;11:87-9.
18. Chande N, McDonald JWD, MacDonald JR. Interventions for treating collagenous colitis. *Cochrane Database Syst Rev.* 2007;24:CD006096.
19. Wildt S, Munck LK, Vinter-Jensen L, et al. Probiotic treatment of collagenous colitis: a randomized, double-blind, placebo-controlled trial with *Lactobacillus acidophilus* and *Bifidobacterium animalis* subsp. *Lactis*. *Inflamm Bowel Dis.* 2006;12:395-401.
20. Madisch A, Mielke S, Eichele E, et al. *Boswellia serrata* extract for the treatment of collagenous colitis: a randomized, double-blind, placebo-controlled trial. *Gastroenterol.* 2005;128(4 suppl 2):A581.
21. Amaro R, Poniecka A, Rogers AI. Collagenous colitis treated successfully with bismuth subsalicylate. *Dig Dis Sci.* 2000;45:1447-50.
22. Girard DE, Keeffe EB. Therapy for collagenous colitis. *Ann Int Med.* 1987;106:909.
23. Buchman AL, Rao S. Pseudomembranous collagenous colitis. *Dig Dis Sci.* 2004;49:1763-7.
24. Fine K, Lee EL. Efficacy of open-label bismuth subsalicylate for the treatment of microscopic colitis. *Gastroenterol.* 1998; 114:29-36.
25. Fine K, Ogunji F, Lee E, Lafon G, Tanzi M. Randomized, double-blind, placebo-controlled trial of bismuth subsalicylate for microscopic colitis. *Gastroenterology.* 1999;116(4):A880.
26. Munck LK, Kjeldsen J, Philipsen E, Fischer Hansen B. Incomplete remission with short-term prednisolone treatment in collagenous colitis: a randomized study. *Scand J Gastroenterol.* 2003;38:606-10.
27. Rutgeerts P, Lofberg R, Malchow H, et al. A comparison of budesonide with prednisolone for active Crohn's disease. *N Engl J Med.* 1994;331:842-5.
28. Baert F, D'Haens G, Dedeurwaerdere F, et al. Budesonide in collagenous colitis: a double-blind placebo-controlled trial with histologic follow-up. *Gastroenterol.* 2002;122:20-5.
29. Mielke S, Heymer P, Bethke B, et al. Budesonide treatment for collagenous colitis: a randomized, double-blind, placebo-controlled, multicenter trial. *Gastroenterol.* 2002;123:978-84.
30. Bonderup OK, Hansen JB, Birket-Smith L, Vestergaard V, Tegelbjaerg PS, Fallingborg J. Budesonide treatment of collagenous colitis: a randomised, double blind, placebo controlled trial with morphometric analysis. *Gut.* 2003;52:248-51.
31. Mielke S, Madisch A, Voss C, et al. Long-term follow-up of collagenous colitis after induction of clinical remission with budesonide. *Aliment Pharmacol Ther.* 2005;22:1115-9.