

# Haemolytic anaemia as a first sign of Wilson's disease

S. Balkema<sup>1\*</sup>, M.E. Hamaker<sup>1</sup>, H.P.J. Visser<sup>2</sup>, G.D.N. Heine<sup>3</sup>, U. Beuers<sup>4</sup>

Departments of <sup>1</sup>Internal Medicine, <sup>2</sup>Haematology and <sup>3</sup>Gastroenterology, Medical Centre Alkmaar, Wilhelminalaan 12, 1815 JD Alkmaar, the Netherlands, <sup>4</sup>Department of Hepatology, Academic Medical Centre, Meibergdreef 9, 1105 AZ Amsterdam, the Netherlands, \*corresponding author: tel.: +31 (0)72-548 28 04, fax: +31 (0)72-548 21 65, e-mail: Sebastiaan.Balkema@mca.nl

## ABSTRACT

A 19-year-old female presented with haemolytic anaemia and subsequently developed liver failure. This raised suspicion of Wilson's disease, which was confirmed by Kayser-Fleischer rings, a low ceruloplasmin level, raised 24-hour urinary copper excretion and two mutations in the 'Wilson gene'. She was successfully treated with D-penicillamine and zinc.

In young patients with unexplained haemolysis, liver dysfunction or neuro-psychiatric symptoms, Wilson's disease should be considered.

## KEYWORDS

Haemolysis, haemolytic anaemia, Wilson's disease

## INTRODUCTION

The differential diagnosis of haemolytic anaemia is extensive and Wilson's disease is generally not the first condition to be considered. It can be difficult to diagnose, due to the low specificity of the presenting symptoms. However, because of the potentially fatal consequences, a timely diagnosis is of utmost importance.

## CASE REPORT

A 19-year-old female student, with no prior medical history, was admitted with a Coombs negative haemolytic anaemia (haemoglobin (Hb) 3.8 mmol/l, mean cell volume (MCV) 109 fl, haptoglobin <0.1 g/l, lactate dehydrogenase (LDH) 784 U/l, aspartate aminotransferase (ASAT) 53 U/l, total bilirubin 84 µmol/l, direct bilirubin 23 µmol/l) and an

elevated gamma-glutamyl transferase (γGT) (144 U/l) with other serum liver tests in the low normal range (alanine aminotransferase (ALAT) 13 U/l, alkaline phosphatase 19 U/l.) The pathological findings were interpreted as a side effect of azithromycin treatment given for a *Chlamydia* infection. Parameters reflecting hepatic protein synthesis were not determined at that time. She was treated with prednisone and a blood transfusion and was discharged in an improved condition. After discharge, her haemoglobin level remained stable (8.0 mmol/l).

Two months later, she presented with jaundice, fatigue and subfebrile temperature. She had not used any drugs or medication, except oral contraceptives; her family history was unremarkable. On examination, she was in moderate distress and jaundiced. Her body temperature was 37.6°C; the other vital signs were normal. There were no palpable lymph nodes; liver and spleen were not enlarged.

Blood examination disclosed a macrocytic anaemia with signs of haemolysis (Hb 4.8 mmol/l, MCV 110 fl, haptoglobin <0.1 g/l, LDH 714 U/l, ASAT 105 U/l, total bilirubin 118 µmol/l, direct bilirubin 48 µmol/l, reticulocytes  $0.202 \times 10^{12}/l$ ) and a leucocytosis ( $17.3 \times 10^9/l$ ) with young erythroid and myeloid cells, but without signs of chronic myeloid leukaemia or other myeloproliferative disorders. Her platelet count was normal. The γGT was elevated (147 U/l), ALAT was normal (22 U/l). The Coombs test was negative. Chest X-ray and abdominal ultrasound were unremarkable. Analyses for enzyme deficiencies, autoantibodies, (viral) infections and paroxysmal nocturnal haematuria were negative.

Haemolysis continued in spite of intravenous treatment with prednisone. The leucocytosis increased to  $80.6 \times 10^9/l$ , presumably in part reactive and in part due to the use of prednisone. A bone marrow biopsy revealed a greatly increased erythropoiesis.

On the seventh day of admission, the patient developed ascites. The aspirate showed a transudate (serum-albumin-

ascites gradient 19 g/l), without signs of infection or malignant cells. Furthermore, the liver synthesis function was impaired (albumin 20.7 g/l, cholinesterase 1.4 kU/l, antithrombin III 24%, international normalised ratio (INR) 1.97).

The combination of haemolysis and signs of liver failure raised suspicion of Wilson's disease. The ophthalmologist diagnosed Kayser-Fleischer rings (*figure 1*). Neurological examination revealed a slight tremor of the left hand. Serum ceruloplasmin level was low (116 mg/l, normal 200 to 600 mg/l). The 24-hour urine copper excretion was elevated more than tenfold (23.4 µmol). Liver biopsy was postponed because of the elevated INR and ascites. Diagnosis was confirmed by a mutation analysis of *ATP7B*, the gene associated with Wilson's disease, which showed two heterozygous mutations, c.2930C>T (p.Thr977Met) and c.3207C>A (p.His1069Gln).

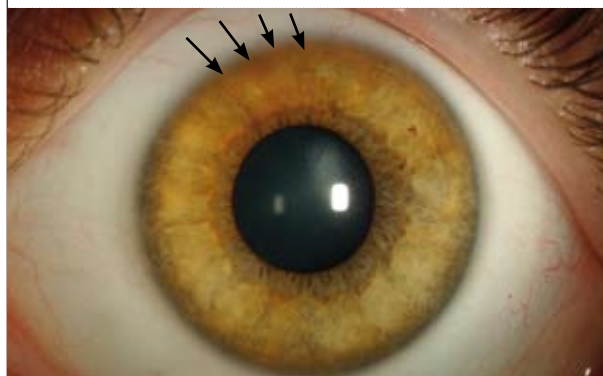
Medical treatment was started with D-penicillamine at low and slowly increasing doses to avoid aggravation of the tremor. Zinc was added strictly separately from the D-penicillamine. The patient tolerated treatment well. The haemolysis diminished within days, the slight tremor completely disappeared, and liver function normalised within months under continuous medical treatment.

## PATHOGENESIS

Wilson's disease is a rare disorder of transmembrane copper transport in hepatic cells.<sup>1</sup> The incidence is 1:30,000 worldwide, and the usual age at presentation is 5 to 30 years.<sup>2</sup> However, Wilson's disease can present even after the age of 50 years. The disorder is caused by autosomal recessive mutations in the *ATP7B* gene on chromosome 13. This gene encodes a transmembrane protein in the hepatocyte that ensures copper transport in the trans-Golgi compartment for incorporation in apoceruloplasmin to form ceruloplasmin and excretion of excess copper through the biliary system.<sup>2,3</sup>

A defect in this gene leads to accumulation of copper in the hepatocyte and subsequently in all extrahepatic organs. In the liver, this leads to disturbances varying from mild elevation of serum liver tests to steatosis, chronic hepatitis and eventually cirrhosis.<sup>2,4</sup> Liver failure in Wilson's disease is sometimes accompanied by severe haemolysis.<sup>2</sup> Copper depositions in the Descemet membrane of the cornea form Kayser-Fleischer rings (*figure 1*). The nuclei lenticulares in the brain are particularly sensitive to copper accumulation. Neurological symptoms such as tremor, dysarthria and parkinsonism have been observed, as well as psychiatric symptoms such as depression and psychosis.<sup>2,4</sup> Haemolysis as the presenting symptom – as seen in our patient – is less common (1 to 12%).<sup>4</sup> It is presumably caused by excess copper released from the liver due to apoptosis/necrosis of

**Figure 1.** Image of the patient's cornea where copper depositions form Kayser-Fleischer rings (arrows), thus obscuring the underlying crypts of the iris (still visible at the lateral and medial sides)

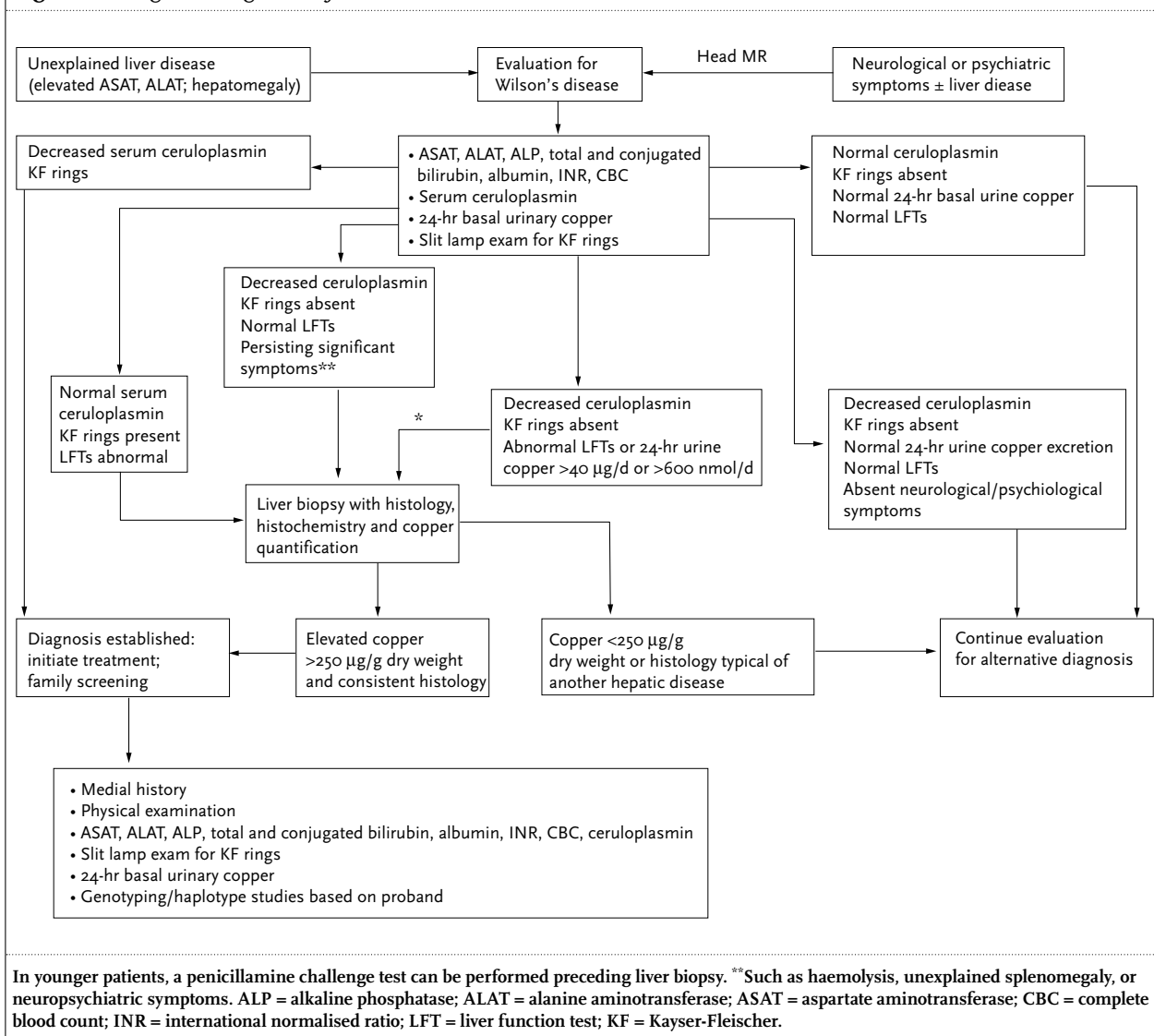


copper-loaded hepatocytes, possibly triggered by external stimuli. This may have direct toxic effects on erythrocytes, resulting in haemolysis.<sup>5</sup>

## DIAGNOSIS

The diagnosis of Wilson's disease is based on a combination of several clinical and biochemical parameters (*figure 2*).<sup>4,6,7</sup> Kayser-Fleischer rings are identified in 50 to 100% of patients, depending on the presenting symptoms.<sup>6,7</sup> They are almost pathognomonic for Wilson's disease but can also be seen in chronic cholestatic diseases.<sup>2,4</sup> Serum ceruloplasmin levels below the normal range are found in more than 85% of patients. Low serum ceruloplasmin levels, however, are not specific for Wilson's disease, but can also be found in malnutrition, in heterozygous carriers of an *ATP7B* gene mutation, Menke's disease or in familial aceruloplasminaemia. Because ceruloplasmin is an acute-phase protein, it can also be in the normal range in patients with Wilson's disease during inflammation.<sup>2,4,6</sup> A normal serum ceruloplasmin may be associated with mutations that allow copper to be transported to the trans-Golgi where ceruloplasmin is formed, but not to bile. Serum liver tests are frequently abnormal. The alkaline phosphatase level will sometimes drop to zero in liver failure associated with Wilson's disease.<sup>2,4</sup> Although serum free copper level is less suitable for making the diagnosis, it can be used for ascertaining the effect of treatment.<sup>3,4,8</sup> Release of copper from the hepatocyte increases the 24-hour urine copper excretion in nearly all symptomatic patients, although in some it can be between 600 and 1600 nmol/day.<sup>9</sup> Other liver diseases, particularly cholestatic diseases, can also elevate urinary copper excretion.<sup>2,4</sup> Liver biopsy shows nonspecific signs such as steatosis, portal and periportal lymphocytic infiltration and cirrhosis. Staining for copper is often false-negative and not reliable

Figure 2. Diagnostic algorithm for Wilson's disease<sup>4</sup>



for a diagnosis of Wilson's disease. The dry copper weight is increased in 80 to 96% of patients but can be false-negative due to extensive fibrosis and false-positive in chronic cholestatic disease.<sup>2,3,10</sup> Radiological imaging plays a minor role in the diagnosis. In patients presenting primarily with neurological symptoms, a cerebral MRI can show abnormalities, particularly of the basal ganglia.<sup>2,4</sup> Once the diagnosis is made, screening of siblings is required.<sup>2,4,8</sup> Therefore, genetic screening for defects in the patient's *ATP7B* gene is useful. More than 200 mutations have been described; in Europe, the most abundant is the H1069Q mutation.<sup>2</sup>

## TREATMENT

Wilson's disease leads to death at an early age without adequate and lifelong medical therapy. Treatment aims

at lowering the copper overload in the body. This is achieved by application of (i) copper chelators such as D-penicillamine or trientine which deplete tissue copper stores and stimulate renal copper secretion, or (ii) zinc which impairs intestinal copper uptake.

In symptomatic patients with Wilson's disease, chelation therapy is an effective treatment strategy. The most frequently used drugs are D-penicillamine and trientine. Both bind copper and are subsequently excreted by the kidneys, thereby providing an alternative route for the defective biliary copper excretion. D-penicillamine is more effective, but also more toxic than trientine: 10 to 20% of patients experience side effects such as allergic reactions, neutropenia, thrombopenia, proteinuria and eventually renal toxicity.<sup>2,8</sup> Furthermore, 20 to 50% of patients with neurological symptoms experience worsening of symptoms during treatment, which can be irreversible.<sup>11</sup>

In asymptomatic patients with Wilson's disease, zinc is a safe and effective treatment when administered at adequate doses. Zinc induces intracellular metallothionein formation in enterocytes (and hepatocytes). Metallothionein binds copper in the cytosol of enterocytes and, thereby, lowers systemic copper uptake. Normal intestinal epithelial turnover leads to shedding of copper-loaded enterocytes resulting in a net copper loss.<sup>2-4</sup> Zinc is administered as a monotherapy in pre-symptomatic patients and as maintenance therapy following effective chelation treatment.<sup>2,8</sup>

Medical treatment must be continued lifelong to prevent disease progression and death. In general, monotherapy with chelators or zinc separate from meals is the recommended form of treatment depending on disease stage and symptoms. If administration of both zinc and a chelator is considered, both drugs need to be administered at different times of the day to avoid drug interactions.

The need for dietary measures in Wilson's disease is debatable; clear evidence for its effectiveness is lacking. Still, patients are informed to avoid copper-rich nutrients such as shellfish, organ meats, nuts, or chocolate.<sup>8</sup>

If the treatment compliance is good, the prognosis is excellent in most cases.<sup>2,4,8</sup> However, if treatment is not tolerated, if the disease is too far advanced before treatment is started, or if patients present with fulminant liver failure, the only option may be a liver transplantation. In patients with only hepatic manifestations, liver transplantation may cure the disease. In patients with primarily neurological symptoms, a transplantation does not guarantee complete remission of symptoms.<sup>12</sup> A relatively new chelator, ammonium tetrathiomolybdate, has shown good treatment results in these patients, but is not yet generally available.<sup>13</sup>

## CONCLUSION

In patients with haemolytic anaemia, liver dysfunction or neuropsychiatric symptoms of unknown cause, Wilson's disease should be considered. A timely diagnosis can be life-saving.

## REFERENCES

1. Wilson SAK. Progressive lenticular degeneration: a familial nervous disease associated with cirrhosis of the liver. *Brain* 1912;34:295-507.
2. Ala A, Walker AP, Ashkan K, Dooley JS, Schilsky ML. Wilson's disease. *Lancet* 2007;369:397-408.
3. Ferenci P. Diagnosis and current therapy of Wilson's disease. *Aliment Pharmacol Ther* 2004;19:157-65.
4. Roberts EA, Schilsky ML. A practice guideline on Wilson disease. *Hepatology* 2003;37:1475-92.
5. Attri S, Sharma N, Jahagirdar S, Thapa BR, Prasad R. Erythrocyte metabolism and antioxidant status of patients with Wilson disease with hemolytic anemia. *Pediatr Res* 2006;59:593-7.
6. Merle U, Schaefer M, Ferenci P, Stremmel W. Clinical presentation, diagnosis and long-term outcome of Wilson's disease. *Gut* 2007;56:115-20.
7. Taly AB, Meenakshi Sundaram S, Sinha S, Swamy HS, Arunodaya GR. Wilson's disease: description of 282 patients evaluated over 3 decades. *Medicine* 2007;86:112-21.
8. Brewer G, Askari F. Wilson's disease: clinical management and therapy. *J Hepatol* 2005;42:S13-21.
9. Müller T, Koppikar S, Taylor RM, et al. Re-evaluation of the penicillamine challenge test in the diagnosis of Wilson's disease in children. *J Hepatol* 2007;47:270-6.
10. Ferenci P, Steindl-Munda P, Vogel W, et al. Diagnostic value of quantitative hepatic copper determination in patients with Wilson disease. *Clin Gastroenterol Hepatol* 2005;8:811-8.
11. Brewer GJ, Terry CA, Aisen AM, Hill GM. Worsening of neurologic syndrome in patients with Wilson's disease with initial penicillamine therapy. *Arch Neurol* 1987;44:490-3.
12. Medici V, Mirante VG, Fassati LR, et al. Liver transplantation for Wilson's disease. *Liver Transpl* 2005;11:1056-63.
13. Brewer GJ, Askari F, Lorincz MT, et al. Treatment of Wilson disease with ammonium tetrathiomolybdate IV. *Arch Neurol* 2006;63:521-7.