

# Overview on visceral manifestations of mitochondrial disorders

J. Finsterer

Neurological Department, Krankenhaus Rudolfstiftung, Vienna, Austria, tel.: +43 (0)1-71165-92085, fax: +43 (0)1-478 17 11, e-mail: duarte@aonmail.at

## ABSTRACT

Mitochondriopathies (MCPs) that reach adult age not only manifest in the central and peripheral nervous systems, eyes, ears, and dermis, but also in visceral organs, such as endocrine organs, heart, liver, guts, kidneys and blood. Visceral manifestations occur as part of a multisystem involvement or rarely as single organ affection. Endocrinological abnormalities are found in the MELAS, MERRF, KSS, MIDD and DIDMOAD syndromes. Cardiac involvement occurs in the MELAS, MERRF, KSS, CPEO, LHON, NARP, and Leigh syndromes. Gastrointestinal manifestations are common in the MERRF, MNGIE, DIDMOAD, and Leigh syndromes. Mitochondrial syndromes with renal manifestations are the KSS, Pearson, DIDMOAD, and Leigh syndromes. The haematopoietic system is affected in the KSS, MERRF, and Leigh syndromes. In addition, visceral manifestations are found in many nonsyndromic MCPs. Although there is no causal therapy for MCPs, adequate symptomatic therapy, particularly of visceral manifestations, markedly improves quality of life and prognosis of these still often neglected or overlooked disorders.

## KEYWORDS

Internal medicine, mitochondrial, neuromuscular, respiratory chain, visceral organs

## INTRODUCTION

Mitochondriopathies (MCPs) were long regarded as disorders affecting almost exclusively the peripheral or central nervous system (encephalomyopathies). However, it turned out that MCPs are multisystem disorders in the majority of cases, also affecting eyes, ears, endocrine organs, heart, guts, liver, kidneys, blood, and dermis.<sup>1,3</sup>

Since MCPs may cause any symptom, in any organ, at any age, the clinical presentation is quite heterogeneous. In rare cases only a single organ is affected, but multisystem involvement may develop with progression of the disease. Possible manifestations of visceral organs are summarised in *table 1*. Various combinations of organ involvement led to the definition of mitochondrial syndromes, of which some are well known for their acronyms. The majority of MCPs, however, do not fit into one of these disease categories. Mitochondrial syndromes with visceral manifestations are listed in *tables 2* and *3*.

## AETIOLOGY

MCPs are either due to genetic causes (primary MCPs) or to nongenetic endogenous or exogenous disturbances of mitochondrial functions (secondary MCPs). Genetic

**Table 1.** Visceral manifestations of mitochondriopathies

### Endocrinological system

Hypopituitarism, short stature, diabetes insipidus, hypothyroidism, hypoparathyroidism, hyperparathyroidism, hyperthyroidism, polyphagia, polydipsia, hyperhidrosis, insufficiency of the suprarenal gland, hyponatraemia, hypokalaemia, hyperlipidaemia, amenorrhoea, hypogonadism, gynaecomastia, sicca syndrome, osteoporosis

### Heart

Cardiomyopathy, rhythm abnormalities, left ventricular hypertrabeculation, Takotsubo phenomenon

### Gastrointestinal

Parodontosis, dysphagia, gastrointestinal dysmotility, pseudo-obstruction, recurrent vomiting, hepatopathy, recurrent pancreatitis, exogene pancreas insufficiency, villous atrophy, malabsorption, diarrhoea, weight loss, anorexia

### Kidneys

Renal cysts, tubulopathy, focal-segmental glomerulosclerosis,<sup>21</sup> Toni-Debre-Fanconi syndrome

### Blood

Anaemia, leucopenia, thrombocytopenia, eosinophilia

**Table 2. Syndromic mitochondrial mitochondriopathies with visceral manifestations**

Acronym	Translation	Endocrine organs	Heart	Guts	Kidney	Blood
CPEO	Chronic progressive external ophthalmoplegia	N	Rhythm abnormalities	N	N	N
KSS	Kearns-Sayre syndrome	Short stature, diabetes, delayed puberty Hypoparathyroidism, osteoporosis, amenorrhoea Hashimoto thyroiditis	Rhythm abnormalities Dysphagia	Hepatopathy	Toni-Debre-Fancon syndrome Anaemia	Megaloblastic
MELAS	Mitochondrial encephalopathy, lactic acidosis, and stroke-like episodes	Short stature, diabetes	Dilative cardiomyopathy, LVHT	Vomiting	N	N N
MERRF	Myoclonic epilepsy and ragged red fibres	Short stature, diabetes	Cardiomyopathy Rhythm abnormalities	Pseudo-obstruction Steatosis hepatis	N	Pancytopenia
MIDD	Maternally inherited diabetes and deafness	Diabetes	N	N	N	N
LHON	Leber's hereditary optic neuropathy	N	Rhythm abnormalities, LVHT	N	N	N
NARP	Neurogenic muscle weakness, ataxia, retinitis pigmentosa	N	Cardiomyopathy	N	N	N
MILS	Maternally inherited Leigh's syndrome	Lactacidosis	Hypotonia	Vomiting	N	N

LVHT = left ventricular hypertrabeculation; N = no manifestation.

**Table 3. Syndromic and nonsyndromic nuclear mitochondriopathies with visceral manifestations**

Syndrome	Mutated gene(s)	Inner organ manifestation
<i>Mutated respiratory chain complexes</i>		
Leigh's syndrome	NDUFS1, NDUFS4, NDUFS7 NDUSF8, NDUFV1, SDHA, CoQ10	Hypotonia, vomiting, cardiomyopathy
Cardioencephalomyopathy syndrome	NDUFS2	Cardiomyopathy
NN	SDHB	Pheochromocytoma, cervical paraganglioma
NN	SDHC, SDHD	Hereditary paraganglioma
<i>Mutated assembly factors</i>		
Leigh's syndrome	SURF1, LRPPRC	Hypotonia, vomiting, hypertrophic cardiomyopathy
NN	SCO1	Ketoacidotic coma, hepatopathy
NN	SCO2	Cardiomyopathy
NN	COX10	Tubulopathy
NN	COX15	Hypertrophic cardiomyopathy
NN	BCS1L	Neonatal proximal tubulopathy, hepatopathy <sup>73</sup>
<i>Mutated proteins responsible for mtDNA stability (depletion and multiple deletions of mtDNA)</i>		
MNGIE	TP	Osteoporosis, malabsorption, gastroparesis, pseudo-obstruction, gastrointestinal dysmotility
MDS	DGUOK	Hepatopathy
DIDMOAD (Wolfram's syndrome)	WFS1, WFS2	Diabetes mellitus, diabetes insipidus, optic atrophy, deafness, dysmotility, hypopituitarism, hypogonadism
<i>Mutated factors involved in the biogenesis of mitochondria</i>		
Ataxia/sideroblastic anaemia syndrome	ABC7	X-chromosomal, sideroblastic anaemia
Barth's syndrome	TAZ	Cardiomyopathy, LVHT, neutropenia, short stature, glutaconic aciduria
Friedreich's ataxia	FRAXA	Hypertrophic cardiomyopathy
Mohr-Tranebjaerg syndrome	DDP1	Deafness, dystonia, cortical blindness, cataract, spasticity, dysphagia

CoQ = coenzyme Q; NN = no name; SDH = succinate dehydrogenase gene; SURF = surfeit locus protein; LRPPRC = leucine-rich pentatricopeptide motif containing protein; COX = cytochrome-c-oxidase; BCS1L gene = human bcl synthesis-like gene; mtDNA = mitochondrial deoxyribonucleic acid; MNGIE = neurogastrointestinal encephalomyopathy, TP = thymidin phosphorylase; MDS = mitochondrial depletion syndrome; DGUOK = deoxy-guanosine-kinase; DIDMOAD = diabetes insipidus, diabetes mellitus, optic atrophy, deafness; WFS = Wolfram's syndrome; TAZ = taffazin; LVHT = left ventricular hypertrabeculation; FRAXA = frataxin; DDP1 = deafness dystonia protein 1 gene.

causes of MCPs are mutations in genes of either the mitochondrial deoxyribonucleic acid (mtDNA) or the nuclear deoxyribonucleic acid (nDNA),<sup>4</sup> indirectly affecting mtDNA or mitochondrial function ('nuclear' MCPs).<sup>5</sup> In adults half of the MCPs are due to mtDNA mutations and the other half to nDNA mutations.<sup>2</sup> In children, the percentage of nuclear MCPs is estimated to be 80%.<sup>6</sup> Mitochondrial and nuclear MCPs may be either sporadic or inherited. Inherited MCPs may be transmitted via an autosomal dominant, autosomal recessive, X-chromosomal, or maternal trait. The most widely appreciated mode of inheritance is that via the maternal line. Maternally inherited mtDNA mutations may simulate dominant traits because of reduced penetrance or complex interaction with genetic and environmental factors.<sup>4</sup> Dominant traits are rare in MCPs and affect the organelle biogenesis and the integrity of the mtDNA, resulting in impaired energy supply, abnormal mitochondrial trafficking, increased toxic damage by oxygen radicals, and mitochondrially driven apoptosis.<sup>4</sup> Both haploinsufficiency and gain-of-function mechanisms underlie nuclear MCPs.

#### Mitochondrial DNA mutations

Human mtDNA is a 16.5kb circular minichromosome consisting of two complementary strands (H and L strand). MtDNA contains 13 mit genes encoding for subunits of the respiratory chain complexes I (NADH dehydrogenase (ND)1-4, ND4L, ND5-6), III (cytochrome b), IV (cytochrome-c-oxidase (COX)I-III) and V (adenosine triphosphatase (ATPase) 6, ATPase8), and 24 syn genes encoding for 22 tRNAs (ribonucleic acid) and two rRNAs.<sup>1</sup> Only the D-loop is a noncoding stretch, containing the promoters for L and H strand transcription. All coding sequences are contiguous with each other without introns.<sup>2</sup> Since the mtDNA genetic code differs from the universal code, the expression of mtDNA genes relies on the specific mitochondrial protein synthesis, depending on the interplay between nuclear encoded transcriptional and translational factors with mitochondrial tRNAs and rRNAs.

Mitochondrial genetics differs from nuclear genetics in the following points:

1. Mitochondrial DNA is maternally inherited.
2. Mitochondria are polyploid, containing 2-10 mtDNA copies per organelle, and each cell contains hundreds of mitochondria.
3. All mtDNA copies are identical (homoplasmy). The propensity of mtDNA to mutate randomly, however, results in the coexistence of wild-type mtDNA and mutant mtDNA in a single cell and organ (heteroplasmy).
4. Mitochondria and mutant mtDNA are stochastically distributed to daughter cells, resulting in changing

mutation loads in different generations and increasing the phenotypic variation of MCPs (bottleneck effect).

5. Because of mitotic segregations and polyploidy phenotypic expression is dependent on a threshold effect. If the load of mutant mtDNA copies exceeds a certain amount, the effect of a mutation can no longer be compensated by wild-type mtDNA.
6. Phenotypic variability is additionally dependent on the pathogenicity of a mutation, the affected gene, the mutation load and its tissue distribution, and the reliance of an organ on the mitochondrial energy supply. Organs that predominantly rely on mitochondrial energy production are the eyes, ears, central and peripheral nervous systems, heart, endocrine system, kidney, guts and liver.

MtDNA mutations are divided into large-scale rearrangements (partial deletions or duplications) and inherited point mutations. Large-scale rearrangements are usually sporadic, while point mutations are usually maternally inherited. Large-scale rearrangements affect several genes and are invariably heteroplasmic, whereas point mutations affect mit and sin genes and can be heteroplasmic or homoplasmic.<sup>1,2,4,5</sup> Phenotype expression of mtDNA mutations often requires the influence of nuclear modifier genes, environmental factors, or the presence of mtDNA haplotypes (polymorphisms). Clusters of mtDNA variants might act as predisposing haplotypes, increasing the risk of disease.<sup>7</sup>

#### Nuclear DNA mutations

Nuclear genes involved in the development of MCPs can be subdivided into four groups: genes encoding for structural components of the respiratory chain; genes encoding for assembly factors of respiratory chain complexes; genes responsible for the mtDNA stability; and genes involved in the biogenesis of mitochondria (*table 3*).<sup>2</sup> Generally, the phenotype-genotype correlation in MCPs is poor.<sup>1</sup>

#### DIAGNOSIS

Diagnosing MCPs is a challenge because of their wide clinical and genetic heterogeneity.<sup>8</sup> Generally, the diagnosis is based on clinical, blood chemical, electrophysiological, imaging, histological, immunohistological, biochemical, polarographic, magnetic spectroscopic, and genetic investigations. Based on these investigations a stepwise strategy can be proposed for the diagnostic work-up (*figure 1*). If an adult patient presents with a classical mitochondrial syndromic MCP, such as chronic progressive external ophthalmoplegia (CPEO), Kearns-Sayre syndrome (KSS), myopathy, encephalopathy, lacticidosis and stroke-like episodes (MELAS) syndrome, myoclonic epilepsy

and ragged red fibres (MERRF) syndrome, neuropathy, ataxia, retinitis pigmentosa (NARP) syndrome, or Leber's hereditary optic neuropathy (LHON), appropriate mtDNA studies should be carried out as a first-line investigation. If the phenotype is classic for a nuclear syndromic MCP (Leigh's syndrome, myoneurogastrointestinal encephalopathy (MNGIE)), nDNA genetic studies should then be performed (figure 1).<sup>9</sup>

If the patient presents with nonsyndromic MCP, it is advisable to individualise the diagnostic approach.<sup>10,11</sup> since there is no golden standard for diagnosing MCPs and since the majority of MCPs are sporadic. If the phenotype is nonsyndromic, but highly suggestive of encephalomyopathy, blood, urine or cerebrospinal fluid (CSF) studies should first be carried out and if negative, followed by a muscle biopsy for histological, immunohistological, biochemical, or polarographic investigations (figure 1).<sup>9,12</sup> If these investigations yield negative results, but there is still suspicion of a mitochondrial MCP, sequencing the entire mtDNA should be considered. Myopathy with or without hyper-creatine-kinase-aemia or lactacidosis is the most common presenting feature.<sup>13</sup> Phenotypes suggestive of MCP include the combinations deafness, cardiomyopathy and diabetes together with encephalomyopathy,<sup>1</sup> short stature, deafness, and ptosis,<sup>9</sup> or leucoencephalopathy of undetermined cause, particularly if ischaemia, multiple sclerosis, and leucodystrophy have been ruled out.<sup>14</sup> Concerning muscle

biopsy, COX staining alone is not sufficient to assess the respiratory function immunohistochemically, which is why it should be always complemented by succinate dehydrogenase (SDH) staining. Generally, MCP should be considered when there is an unexplained association of abnormalities with progressive course, involving seemingly unrelated organs.<sup>11</sup> Several research groups have developed diagnostic criteria, which may be useful for diagnosing MCPs.<sup>8,15-17</sup>

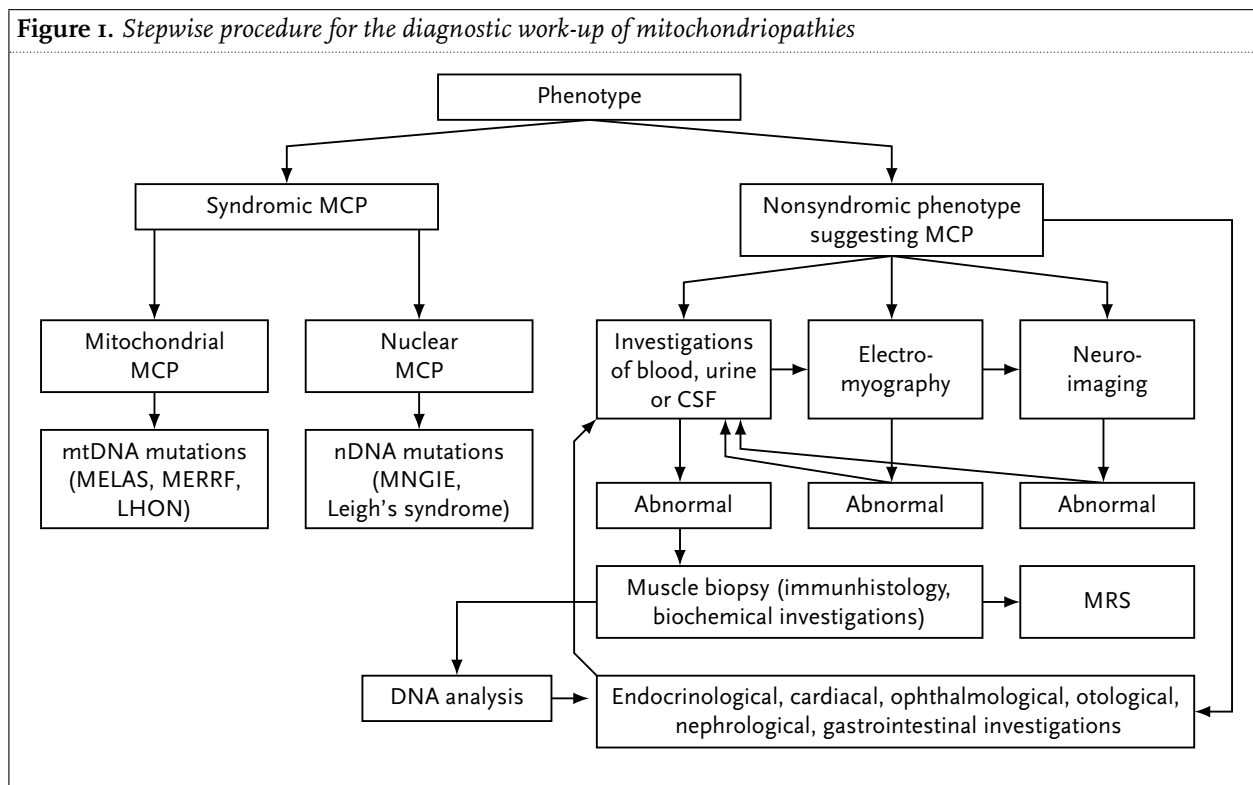
## VISCERAL MANIFESTATIONS OF MITOCHONDRIOPATHIES

Visceral manifestations of MCPs concern the endocrine organs, heart, guts, liver, the kidney, and the haematopoietic system. In addition to the classical mitochondrial syndromes, which are accompanied by visceral manifestations,<sup>18</sup> phenotypes that do not fit into one of the known mitochondrial syndromes account for the majority of MCPs with visceral manifestations.

## ENDOCRINE ORGANS

Endocrinological abnormalities represent the most frequent visceral manifestations of MCPs. Endocrine organs affected in MCPs are the pituitary gland (hypopituitarism with growth retardation, thyroid

Figure 1. Stepwise procedure for the diagnostic work-up of mitochondriopathies



dysfunction, hypocorticism, gonadal dysfunction, and abnormalities in the water homeostasis), the thyroid gland (hypothyroidism, hyperthyroidism, Hashimoto thyroiditis), the parathyroid gland (hypo- or hyperparathyroidism), the endocrine pancreas (mitochondrial diabetes mellitus), the suprarenal gland (insufficiency with hypoaldosteronism, (hyponatraemia) or Addison's syndrome (hypotension, eosinophilia)), or the gonads (impotence, infertility, spontaneous abortion). Symptoms of hypopituitarism or hypothyroidism may overlap with symptoms of skeletal muscle manifestations such as fatigue, general weakness, slowing, or hypotonia. Whether hyperlipidaemia, hyperuricaemia, osteoporosis, or hyperhidrosis, which are frequently associated with MCP, represent manifestations of an MCP, is unclear. Mitochondrial syndromes that go along with endocrinological manifestations are the MELAS, MERRF, KSS, maternally inherited diabetes and deafness (MIDD), and diabetes insipidus, diabetes mellitus, optic atrophy, deafness (DIDMOAD or Wolfram) syndrome (*table 2*).

## HEART

The heart is the visceral organ second most frequently affected in MCPs.<sup>9</sup> Cardiac involvement of MCPs either manifests as impulse generation or impulse conduction disturbances or as myocardial impairment, manifesting as either hypertrophic or dilated cardiomyopathy.<sup>19</sup> Frequent electrocardiography abnormalities are atrial fibrillation, atrioventricular (AV) block, Wolff-Parkinson-White (WPW) syndrome, bundle branch block, QT prolongation, or ST and T-wave abnormalities. A frequently overlooked myocardial manifestation of MCPs is left ventricular hypertrabeculation, also known as noncompaction. Noncompaction presents as a meshwork of interwoven myocardial strings, all lined with endocardium, distally to the papillary muscles. On echocardiography trabeculations have the same echogenicity as the myocardium, they move synchronously with it, and are perfused from the ventricular side. In single cases apical ballooning of the left ventricle (Takotsubo's phenomenon) has been associated with MCPs. Since cardiac involvement in MCP may manifest subclinically, and rhythm abnormalities, hypertrophic/dilative cardiomyopathy, or noncompaction may be the initial or even exclusive manifestation of MCP, all these patients should undergo a complete neurological investigation. Vice versa, all patients in whom MCP is suspected or diagnosed should undergo a complete cardiological investigation.<sup>19</sup> MCPs are frequently associated with arterial hypertension or orthostatic hypotension. Mitochondrial syndromes, with cardiac manifestations are the MELAS, MERRF, KSS, CPEO, LHON, NARP, and Leigh syndromes (*table 2*).

## GASTROINTESTINAL TRACT

Frequent gastrointestinal manifestations of MCPs are dysphagia, in case of smooth muscle affection, hepatopathy with steatosis hepatis and liver insufficiency, or villous atrophy of the small intestines with recurrent diarrhoea.<sup>20</sup> Rare gastrointestinal manifestations of MCPs are paradontosis, recurrent, sometimes triggerable vomiting, recurrent pancreatitis with exogen pancreas insufficiency, gastrointestinal dysmotility, gastroparesis, progressive intestinal pseudo-obstruction, abdominal pain, dilation and dysmotility of the oesophagus, stomach and the small intestines, and malabsorption with progressive malnutrition. Gastroscopy and colonoscopy often show nonspecific alterations. Gastrointestinal manifestations of MCPs are still underrecognised, most likely due to the difficult diagnostic approach. Biochemical or electron microscopic investigations of the affected organs and tissues may help to prove the impaired function or abnormal morphology of mitochondria. Mitochondrial syndromes with gastrointestinal manifestations are the MERRF, Pearson, MNGIE, DIDMOAD, Leigh, and mitochondrial depletion syndromes (MDS) (*table 2*).<sup>20</sup>

## KIDNEYS

Renal manifestations of MCPs are polycystic kidneys, nonspecific nephritis, focal, segmental glomerulosclerosis,<sup>21</sup> or tubular dysfunction, which frequently turns into chronic renal failure, requiring haemodialysis. Proximal tubular dysfunction results in a more or less complete Toni-Debre-Fanconi syndrome,<sup>3</sup> characterised by hyperphosphaturia, hyperaminoaciduria, and glucosuria.<sup>22</sup> Fanconi's syndrome may occur in an isolated form as the initial manifestation of an MCP or as part of a multisystem disease.<sup>23</sup> Only a few patients have been reported with tubular acidosis, Bartter's syndrome, chronic tubulointerstitial nephritis, or nephritic syndrome.<sup>3</sup> Bicarbonaturia, hypercalcuria, proteinuria, or a decreased glomerular filtration rate may also be present.<sup>3</sup> Mitochondrial syndromes with renal manifestations are the KSS, Pearson, DIDMOAD, and Leigh syndromes (*table 2*).

## BLOOD

Rarely, MCPs manifest in the haematopoietic system as pancreatic dysfunction or as isolated thrombocytosis or thrombopenia, or as pancytopenia. In single cases either permanent or recurrent eosinophilia can be observed, not attributable to any of the established causes. Mitochondrial syndromes accompanied by alterations of

the haematopoietic system are the KSS, Pearson, MERRF, and Leigh syndromes (*table 2*). All these manifestations are partially resistant to adequate therapy.

### **Syndromic, mitochondrial MCPs with visceral manifestations**

#### *Chronic progressive external ophthalmoplegia*

CPEO is the commonest manifestation of mtDNA rearrangements and often associated with ptosis.<sup>24</sup> Later on, cataract, retinitis pigmentosa, deafness, fatigue, ataxia, limb weakness, neuropathy, rhythm abnormalities, cardiomyopathy, or renal insufficiency may develop.<sup>14,25</sup> The clinical course is usually benign since additional organ failure is mild and with a low risk of serious disability. CPEO is due to mtDNA deletions or point mutations in the tRNA<sup>Leu</sup>, tRNA<sup>Ile</sup>, tRNA<sup>Lys</sup>, or tRNA<sup>Asn</sup> genes.<sup>18,26</sup> Point mutations in the tRNA<sup>Lys</sup> gene cause CPEO with myoclonic epilepsy. Point mutations in the tRNA<sup>Leu</sup> gene cause CPEO with multisystem involvement, CPEO with diabetes and ataxia,<sup>18</sup> or CPEO with myopathy and sudden death. CPEO with multiple-sclerosis-like features is due to tRNA<sup>Ile</sup> mutations.<sup>18</sup> CPEO with diabetes and lipoma has been reported in a patient with the A3243G mutation.<sup>27</sup>

#### *Kearns-Sayre syndrome*

KSS is characterised by CPEO, pigmentary retinopathy, cardiac conduction defects, cerebellar ataxia, raised CSF protein, and onset before the age of 20.<sup>28</sup> Proximal myopathy develops with progression of the disease. Additional features may be mental retardation, deafness, syncope, bulbar symptoms such as dysphagia, stroke-like episodes, endocrine dysfunction, such as delayed puberty, primary amenorrhoea, or diabetes, sideroblastic anaemia, or lactacidosis.<sup>25</sup> The prognosis of KSS is poor and patients rarely survive beyond the age of 30. KSS is due to sporadic, single or multiple large-scale deletions, ranging from 1.3 to 8.8 kb or from mtDNA duplications.<sup>18,25</sup>

#### *Myopathy, encephalopathy, lactacidosis, and stroke-like episodes*

The commonest of the encephalomyopathies is MELAS syndrome, characterised by stroke-like episodes with hemi-syndrome, migraine, nausea, or vomiting. Additional features may be deafness, diabetes, seizures, dementia, ataxia, cortical blindness, optic atrophy, pigmentary retinopathy, dilative cardiomyopathy, exercise intolerance, lactacidosis, or short stature.<sup>12</sup> Many 'overlap' cases have been described with additional features, such as CPEO, myocloni, or ataxia. Stroke-like episodes are usually not disabling, often associated with migraine and do not conform to vascular territories. Stroke-like episodes are assumed to be due to metabolic derangements, spreading beyond an ischaemic focus.<sup>1,12,29,30</sup> Cerebral computed tomography (CT) and magnetic resonance imaging (MRI)

scans typically show white matter and cortical lesions in the parieto-occipital region.<sup>25</sup> Uni- or bilateral basal ganglia calcifications are common. The course is slowly progressive. MELAS is due to mtDNA point mutations in tRNA, COX3, or ND5 genes or due to small-scale mtDNA deletions. A frequently detected mutation in MELAS patients is the transition A3242G. MELAS with Parkinsonism was associated with a 4bp deletion in the cytb gene.<sup>18,31</sup> MELAS with bilateral striatal necrosis was associated with an ND1 mutation and MELAS/LHON overlap syndrome resulted from an ND5 point mutation.<sup>18</sup> MELAS/MERRF overlap syndrome is due to tRNA<sup>Ser</sup> or tRNA<sup>Lys</sup> mutations.<sup>18</sup>

#### *Myoclonic epilepsy and ragged red fibres*

MERRF syndrome usually presents between childhood and early adulthood with photosensitive general tonic-clonic seizures, myopathy, including ptosis and ophthalmoparesis, cerebellar ataxia, dementia, and deafness. Myocloni occur alone or in association with generalised seizures. Additional features include stroke-like episodes, optic atrophy, dorsal column loss, cardiomyopathy, heart block, heart failure, respiratory failure, paralytic ileus, pancytopenia, lipomatosis, pes cavus, or polyneuropathy.<sup>12,25</sup> In a single case, carrying the A8344G mutation, histiocytoid cardiomyopathy was described.<sup>32</sup> Disease severity ranges from minor, nondisabling manifestations to progressive, ultimately fatal disease. MERRF is caused by mtDNA tRNA<sup>Lys</sup> point mutations or multiple mtDNA deletions resulting from nDNA mutations.<sup>33</sup> A mutation frequently found in MERRF patients is the mtDNA transition A8344G.

#### *Maternally inherited diabetes and deafness*

MIDD was first described in a family with only maternally inherited diabetes and sensorineural hearing loss.<sup>34</sup> Later on, MIDD families were described that additionally presented with features of MELAS syndrome,<sup>35</sup> including seizures, migraine, short stature, mental retardation, or stroke-like episodes.<sup>36</sup> No correlation between the heteroplasmy rate and the clinical features was found.<sup>36</sup> MIDD is caused by mutations in the tRNA<sup>Leu</sup> or tRNA<sup>Lys</sup> gene and due to large-scale tandem duplications or deletions/duplications. The most frequent mutation causing MIDD is the A3243G transition.<sup>35,37</sup> In a single patient the A3243G mutation was associated with hypertrophic cardiomyopathy and heart failure.<sup>38</sup>

#### *Leber's hereditary optic neuropathy*

LHON is the commonest cause of maternally inherited blindness in otherwise healthy young men. LHON is due to homoplasmic mtDNA mutations affecting genes, which encode for subunits of respiratory chain complex I, III, IV, or V. There are three primary LHON mutations, A3460G, A11778G, and T14484C, which account for >95%

of the cases.<sup>13,39</sup> Only 50% of males and 10% of females harbouring a primary LHON mutation actually develop LHON.<sup>39</sup> The incomplete penetrance and the predominance in males suggest that factors other than mtDNA mutations (secondary LHON mutations, nDNA mutations) play a modifying role. Onset is in late adolescence or early adulthood with subacute, painless, bilateral visual loss. Rarely, the heart (rhythm abnormalities, hypertrophic cardiomyopathy, left ventricular hypertrabeculation) or cerebrum (dystonia) are additionally affected.<sup>1,13</sup> Some female LHON patients present with a multiple sclerosis-like phenotype.<sup>40</sup> White matter lesions were also reported in a male with the A3460G mutation.<sup>19</sup>

#### *Neuropathy, ataxia, retinitis pigmentosa*

NARP syndrome is characterised by weakness due to motor neuropathy, sensory disturbances, cerebellar ataxia, and retinitis pigmentosa. Rare additional features include developmental delay, mental retardation, dementia, ataxia, cardiomyopathy, and epilepsy. NARP and NARP/maternally inherited Leigh's syndrome (MILS) overlap syndrome are due to mutations in the mtDNA ATPase6 subunit gene.<sup>12,18,41</sup>

#### *Maternally inherited Leigh's syndrome*

Leigh's syndrome, also known as subacute necrotising encephalopathy, usually presents at infancy as a multisystem disorder with brainstem and basal ganglia dysfunction, weakness, hypotonia, seizures, developmental delay, and lactic acidosis. Additional features may include pyramidal signs, dystonia, optic atrophy, nystagmus, retinitis pigmentosa, ataxia, deafness, neuropathy, CPEO, or respiratory failure.<sup>42</sup> Visceral manifestations comprise hypertrophic cardiomyopathy, fatty infiltrations of hepatocytes, recurrent vomiting, and degeneration of the renal tubular epithelial cells.<sup>42,43</sup> Typical cerebral CT or MRI abnormalities include bilateral, symmetric, high-signal alterations in the spinal cord, upper brainstem, cerebellum, midbrain, thalamus, or basal ganglia, with or without cortical changes, and basal ganglia calcifications. Infantile-onset MILS is caused by ATPase6 mutations.<sup>44</sup> Adult-onset MILS is caused by tRNAVal mutations.<sup>18</sup> MILS with spinocerebellar ataxia is associated with a tRNA<sup>Lys</sup> mutation.<sup>18</sup>

#### **Nonsyndromic, mitochondrial MCPs with visceral manifestations**

Mitochondrial MCPs with visceral manifestations that do not fit into one of the established mitochondrial syndromes comprise the following entities: myopathy associated with cardiomyopathy due to tRNA<sup>Leu</sup> mutations;<sup>18</sup> hypertrophic cardiomyopathy due to 12rRNA, tRNA<sup>Sile</sup>, tRNA<sup>Lys</sup>, tRNA<sup>Gly</sup>, or cytb mutations;<sup>18</sup> multisystem MCP with cardiomyopathy due to the A4269G, G8363A, C4320T

mutations;<sup>18</sup> encephalomyopathy associated with diabetes due to the T14709C transition;<sup>18</sup> congenital multisystem MCP due to the A15023G transition;<sup>18</sup> multisystem MCP with sudden death due to the A10044G transition;<sup>18</sup> intestinal dysfunction associated with encephalomyopathy due to the G8313A or G1644T mutations; idiopathic sideroplastic anaemia due to the G12301A, T6721C, or T6742C mutations;<sup>18,45</sup> and exercise intolerance and myoglobinuria due to point mutations in the tRNA<sup>Phe</sup>, COXIII, ND4, or cytb gene.<sup>18</sup> MtDNA deletions and insertions may cause: diabetes, deafness, or maculopathy;<sup>18</sup> diabetes, deafness, and optic atrophy;<sup>18</sup> exercise intolerance with recurrent myoglobinuria;<sup>18</sup> chronic diarrhoea with villous atrophy and multisystem involvement;<sup>18</sup> diabetes, deafness, tubulopathy, and ataxia;<sup>18</sup> or diabetes, cerebellar ataxia, hearing loss, olfactory dysfunction, CPEO, and bilateral facial nerve palsy.<sup>46</sup>

#### **Syndromic, nuclear mitochondriopathies with visceral manifestations**

##### *Nuclear Leigh's syndrome*

Nuclear Leigh's syndrome hardly differs phenotypically from MILS. Typical clinical features are vomiting, hepatopathy, cardiomyopathy, encephalopathy, and generalised weakness. Nuclear Leigh's syndrome is caused by mutations in nDNA genes encoding for subunits of the pyruvate-dehydrogenase complex or for respiratory chain components, such as NDUFS1, NDUFS4, NDUFS7, NDUFS8, NDUFV1, or SDHA (table 3) or genes encoding for proteins involved in the maintenance of respiratory chain complex function by guaranteeing the correct holoenzyme assembly.<sup>2</sup> The most frequently mutated gene of the latter type is surfeit locus protein (SURF1), encoding for a complex IV assembling protein.<sup>2</sup> A French-Canadian type of Leigh's syndrome is due to mutations in the leucine-rich pentatricopeptide motif containing protein (LRPPRC) gene, encoding for a putative mtDNA transcript-processing factor.<sup>2,47</sup>

##### *Myoneurogastrointestinal encephalopathy*

MNGIE, also termed POLIP (polyneuropathy, ophthalmoplegia, leucencephalopathy, intestinal pseudo-obstruction), is a multisystem disorder manifesting before the age of 20 as episodic nausea, vomiting, gastroparesis, progressive intestinal pseudo-obstruction, abdominal pain, dilation or dysmotility of the oesophagus, stomach, or small intestine, diarrhoea, and malabsorption with progressive malnutrition, leading to death around the age of 40. Additional features comprise myopathy, including CPEO, glaucoma-like optic neuropathy, cognitive decline due to leucencephalopathy, retinitis pigmentosa, deafness, hoarseness, dysarthria, and polyneuropathy.<sup>48</sup> Post-mortem changes include visceral neuropathy (loss of neurons and fibrosis in the celiac, mesenteric, or

Auerbach plexuses) and scleroderma-like changes.<sup>25</sup> MNGIE was recently shown to result from mutations in a gene encoding for the thymidine phosphorylase.<sup>33,49,50</sup> Thymidine phosphorylase is likely to have an important role in nucleoside metabolism by regulating the availability of thymidine for DNA synthesis.<sup>51</sup> Accordingly, patients harbour mtDNA depletions, multiple deletions, or point mutations. Additional functions of the enzyme involve angiogenesis and cell trophism.<sup>9</sup> The disorder is transmitted via an autosomal recessive trait.

#### *Diabetes insipidus, diabetes mellitus, optic atrophy, deafness (Wolfram's syndrome)*

DIDMOAD syndrome is a rare autosomal recessive neurodegenerative disorder with juvenile onset, also known as Wolfram's syndrome (WFS).<sup>52</sup> The mortality rate of WFS is about 65% before 35 years of age. Minimal diagnostic criteria include diabetes and optic atrophy, with seemingly unknown aetiology. Other less frequent features are psychiatric abnormalities, ataxia, urinary tract atony, limited joint contractures, cardiovascular and gastrointestinal autonomic neuropathy, hypergonadotropic hypogonadism, cardiac malformations, or pituitary dysfunction.<sup>52,53</sup> WFS is genetically heterogeneous, but most frequently due to mutations in the WFS1 gene on chromosome 4p16 or mutations in the WFS2 gene on chromosome 4q22-24.<sup>54,55</sup> WFS1 and WFS2 mutations secondarily result in single or multiple mtDNA deletions.<sup>56</sup>

#### *Mitochondrial depletion syndrome*

MtDNA depletion of various degrees leads to a fatal multisystem infantile disorder, characterised by weakness, muscle hypotonia, CPEO, and severe lactacidosis. Additional features include hepatopathy, Fanconi's syndrome, encephalopathy, seizures, cardiomyopathy, or cataract.<sup>12,57</sup> Total mtDNA levels in these patients are below 35% of those in controls. No mtDNA mutations are found in these patients. The underlying defect is an impaired replication or maintenance of mtDNA due to nDNA mutations in the thymidine kinase or deoxyguanosine kinase gene, causing gastrointestinal abnormalities, deoxyguanosine-kinase (DGUOK) gene, resulting in encephalomyopathy and hepatopathy, polymerase gamma (POLG) gene causing hepatopathy with lactacidosis, WFS1 or WFS2 genes, associated with DIDMOAD syndrome, or thymidine kinase 2 gene, associated with fatal infantile hepatopathy (table 3).<sup>2,19</sup>

#### *Barth's syndrome*

Barth's syndrome is a rare X-linked disease, characterised by the triad dilated cardiomyopathy, skeletal myopathy, and neutropenia. Additionally, there may be growth retardation and 3-methyl-glutaconic aciduria. The age range is 0 to 49 years.<sup>58</sup> Untreated boys die in infancy or early childhood

from septicaemia or cardiac failure.<sup>59</sup> Barth's syndrome is due to mutations in the taffazin gene on chromosome Xq28. The taffazin gene is suspected to encode for one or more acyltransferases, resulting in reduced cardiolipin synthesis and thus cardiolipin deficiency in the skeletal muscle, myocardium, and platelets.<sup>33,58,60</sup> Barth's syndrome is the first inborn error of metabolism identified, directly affecting cardiolipin, a component of the inner mitochondrial membrane, necessary for proper functioning of the electron transport chain.<sup>59</sup>

#### *Friedreich's ataxia*

Friedreich's ataxia is the most common of the inherited ataxias. Clinically, Friedreich's ataxia is characterised by cerebellar ataxia, hypertrophic cardiomyopathy, and foot deformity. Friedreich's ataxia is caused by an expansion of a GAA triplet, located within the first intron of the frataxin gene on chromosome 9q13. The mutation affects mitochondria because of its involvement in RNA processing and the intramitochondrial iron handling, leading to iron accumulation, increased sensitivity to oxidative stress, and deficient respiratory chain activity.<sup>61</sup> There are indications that the mutation results in a defect of iron/sulphur protein construction.<sup>62</sup>

#### *Mohr-Tranebjaerg syndrome*

Mohr-Tranebjaerg syndrome (MTS) is a rare disorder characterised by early-onset deafness, dystonia, cortical blindness, cataract, spasticity, dysphagia, and mental retardation.<sup>62</sup> MTS is due to mutations in the gene encoding for the deafness-dystonia protein (DDP1).<sup>63</sup> The first mutation found in this gene was the C66W missense mutation, affecting the binding of Zn(2+) via the Cys(4) motif.<sup>64,65</sup> As a consequence, the DDP1 molecule is incorrectly folded and loses its ability to assemble to a heterohexameric complex with its cognate partner Tim13. In a recently described patient MTS was due to the G38C transversion in exon 1 of the DDP1 gene, affecting the ATG start codon by changing methionine to isoleucine.<sup>66</sup> This mutation leads to the absence of DDP1 and marked reduction of Tim13. Other mutations reported were the one basepair deletion 151delT and the stop mutation E24X in the allelic Jansen's syndrome.<sup>67</sup> Muscle biopsy is structurally and biochemically normal, but MRI and positron emission tomography studies reveal hypometabolic areas in the right striatum, and parietal cortex and atrophy of the occipital lobes.

#### *Nuclear chronic progressive external ophthalmoplegia*

CPEO due to mutations in nuclear genes may also present with visceral manifestations, similar to those in mitochondrial CPEO. Mutated genes responsible for nuclear CPEO are due to mutations in the twinkle, ANTI, or POLG genes.<sup>18</sup>



### *Nuclear myoclonic epilepsy and ragged red fibres*

MERRF syndrome is not only due to mtDNA mutations but also due to mutations in the POLG gene (nuclear MERRF).<sup>68</sup> The clinical features of nuclear MERRF are the same as those of mitochondrial MERRF.

### **Nonsyndromic, nuclear mitochondriopathies with visceral manifestations**

Nonsyndromic, nuclear MCPs with visceral manifestations include fatal, multisystem complex I deficiency due to mutations in the NDUFS4 gene;<sup>19</sup> familial idiopathic cardiomyopathy due to multiple, secondary mtDNA deletions;<sup>18</sup> sideroplastic anaemia with myopathy;<sup>18</sup> CPEO with cardiomyopathy due to multiple, secondary mtDNA deletions;<sup>18</sup> thiamine-responsive megaloblastic anaemia;<sup>17</sup> mitochondrial diabetes;<sup>69</sup> pheochromocytoma and cervical paraganglioma due to SDHB mutations;<sup>2</sup> hereditary paragangliomas due to SDHC or SDHD mutations;<sup>2</sup> pyruvate dehydrogenase complex deficiency characterised by neutropenia, absent corpus callosum, absent pyramids, and ectopic inferior olives;<sup>45</sup> Luft's syndrome; X-linked ataxia with sideroblastic anaemia;<sup>2,18</sup> hepatopathy with ketoacidotic coma due to SCO1 mutations;<sup>62</sup> leucodystrophy with tubulopathy due to COX10 mutations;<sup>2</sup> and hypertrophic cardiomyopathy due to COX15 mutations.<sup>70</sup> Whether arteriosclerosis is a feature of MCPs remains speculative.

### **THERAPY**

Systematic studies on therapies for MCPs are lacking. There is no causal, only symptomatic therapy of MCPs. Symptomatic therapy comprises antidiabetic therapy in case of diabetes, hormone substitution in case of other endocrine disturbances, cardiac therapy in case of rhythm abnormalities or heart failure, antiemetic drugs if there is vomiting, substitution of pancreatic enzymes, domperidone or cisapride for gastrointestinal dysmotility, substitution of potassium and sodium in case of hypokalaemia or hyponatraemia, hormone substitution in case of hypopituitarism, and transfusions for anaemia and pancytopenia. Symptomatic measures may markedly improve quality of life and prognosis of affected individuals. Substitution of coenzyme-Q is effective only in case of confirmed coenzyme-Q-deficiency. Idebenone has a positive influence on hypertrophic cardiomyopathy in patients with Friedreich's ataxia. If dysphagia, frequent vomiting, malabsorption, or recurrent diarrhoea leads to prominent cachexia, a percutaneous gastroenterostomy should be considered. Impaired impulse propagation in KSS or other MCPs often requires the implantation of a pacemaker already at the early stages of the disease. If there is coexisting carnitine deficiency, administration of

carnitine can be helpful.<sup>1</sup> Ptosis often requires surgical reconstruction.

### **PROPHYLAXIS**

More important than the administration of certain drugs is the avoidance of certain, frequently prescribed remedies, such as biguanides (cause lactacidosis), fibrates,<sup>71</sup> or local anaesthetics such as bupivacain or articain (inhibit respiratory chain complex I),<sup>72,73</sup> statins (reduce endogenous coenzyme Q10), acetyl-salicylic-acid or sevoflurane (inhibit the respiratory chain electron transport),<sup>74,75</sup>  $\beta$ -blockers (inhibit noncompetitively the ATPase and thus stage 3 respiration),<sup>76</sup> carvedilol (inhibits complex I,<sup>77</sup>), corticosteroids (reduce the transmembrane mitochondrial potential), tetracyclines and amiodarone (inhibit the  $\beta$ -oxidation), barbiturates, chloramphenicol (reduce mitochondrial protein synthesis and number and size of mitochondria),<sup>45</sup> and valproic acid (sequesters carnitine, reduces respiratory chain activity and oxidative phosphorylation),<sup>78</sup> doxorubicine, ifosamide, and carboplatin (cause mtDNA mutations),<sup>79</sup> zidovudine (causes mtDNA depletion, reduces respiratory chain complex I and IV activity),<sup>80</sup> and interferon (impairs the mtDNA transcription). Generally, care should be taken when applying local anaesthetics and with general anaesthesia. MCP patients also should avoid exposure to ozone.

### **SUMMARY**

MCPs are usually multisystem disorders, which, in addition to the central and peripheral nervous systems, eyes, or ears, also manifest in visceral organs, such as endocrine organs, heart, gastrointestinal tract, liver, kidneys, or haematopoietic system. This is why the internal medicine specialist plays an important role in the diagnostic work-up and symptomatic therapy of these disorders. Internal medicine specialists should consider an MCP if a patient or family presents with a combination of endocrine dysfunctions, rhythm abnormalities, cardiomyopathy, arterial hypo- or hypertension, hepatopathy, gastrointestinal dysfunction, renal insufficiency, thrombocytopenia, or anaemia alone or in combination, without an explanation for any of these abnormalities. Since most MCPs are accompanied by neurological abnormalities, it is advisable to refer any patient with suspected MCP to a neurologist who is familiar with MCPs. All patients in whom MCP is suspected or diagnosed should also undergo ophthalmological, otolaryngological, endocrinological, cardiological, gastrointestinal, and haematological investigations. Although there is no causal therapy for MCPs, adequate symptomatic therapy,

particularly of the visceral manifestations, may result in a markedly improved quality of life and prognosis of these still often neglected or overlooked entities.

## REFERENCES

1. Leonard JV, Schapira AHV. Mitochondrial respiratory chain disorders I: mitochondrial DNA defects. *Lancet* 2000;355:299-304.
2. Zeviani M, Carelli V. Mitochondrial disorders. *Curr Opin Neurol* 2003;16:585-94.
3. Rotig A. Renal disease and mitochondrial genetics. *J Nephrol* 2003;16:286-92.
4. Zeviani M, Di Donato S. Mitochondrial disorders. *Brain* 2004;127:2153-72.
5. Bindoff LA. Disorders caused by mitochondrial DNA instability. *Eur J Neurol* 2004;11(suppl 2):5.
6. Zeviani M, Tiranti V, D'Adamo P, et al. Nuclear genes in mitochondrial disorders. *Eur J Neurol* 2004;11(suppl 2):5.
7. Hofmann S, Bezold R, Jaksch M, et al. Wolfram (DIDMOAD) syndrome and Leber hereditary optic neuropathy (LHON) are associated with distinct mitochondrial DNA haplotypes. *Genomics* 1997;39:8-18.
8. Bernier FP, Boneh A, Dennett X, et al. Diagnostic criteria for respiratory chain disorders in adults and children. *Neurology* 2002;59:1406-11.
9. Gillis L, Kaye E. Diagnosis and management of mitochondrial diseases. *Pediatr Clin N Am* 2002;49:203-19.
10. Chinnery PF, Turnbull DM. Clinical features, investigation, and management of patients with defects of mitochondrial DNA. *J Neurol Neurosurg Psychiatry* 1997;63:559-63.
11. Fadic R, Johns DR. Clinical spectrum of mitochondrial diseases. *Sem Neurol* 1996;16:11-22.
12. McFarland R, Taylor RW, Turnbull DM. The neurology of mitochondrial DNA disease. *Lancet Neurology* 2002;1:343-51.
13. Finsterer J, Jarius C, Eichberger H, et al. Phenotype variability in 130 adult patients with respiratory chain disorder. *J Inher Metab Dis* 2001;24:560-76.
14. Nardin RA, Johns DR. Mitochondrial dysfunction and neuromuscular disease. *Muscle Nerve* 2001;24:170-91.
15. Walker UA, Collins S, Byrne E. Respiratory chain encephalomyopathies: a diagnostic classification. *Eur Neurol* 1996;36:260-7.
16. Wolf NI, Smeitink JAM. Mitochondrial disorders. *Neurology* 2002;59:1402-5.
17. Taylor RW, Schaefer AM, et al. The diagnosis of mitochondrial muscle disease. *Neuromuscul Disord* 2004;14:237-45.
18. Servidei S. Mitochondrial encephalomyopathies: gene mutation. *Neuromuscul Disord* 2004;14:107-16.
19. Lev D, Nissenkorn A, Leshinsky-Silver E, et al. Clinical presentations of mitochondrial cardiomyopathies. *Pediatr Cardiol* 2004;25:445-50.
20. Gillis LA, Sokol RJ. Gastrointestinal manifestations of mitochondrial disease. *Gastroenterol Clin North Am* 2003;32:789-817.
21. Doleris LM, Hill GS, Chedin P, et al. Focal segmental glomerulosclerosis associated with mitochondrial cytopathy. *Kidney Int* 2000;58:1851-8.
22. Berio A, Piazzini A. Kearns-Sayre syndrome associated with de Toni-Debre-Fanconi syndrome due to cytochrome-c-oxidase (COX) deficiency. *Panminerva Med* 2001;43:211-4.
23. Kuwertz-Broking E, Koch HG, Marquardt T, et al. Renal Fanconi syndrome: first sign of partial respiratory chain complex IV deficiency. *Pediatr Nephrol* 2000;14:495-8.
24. Holt IJ, Harding AE, Cooper JM, et al. Mitochondrial myopathies: clinical and biochemical features of 30 patients with major deletions of muscle mitochondrial DNA. *Ann Neurol* 1989;26:699-708.
25. Schapira AHV, Cock HR. Mitochondrial myopathies and encephalomyopathies. *Eur J Clin Invest* 1999;29:886-98.
26. Zeviani M, Servidei S, Gellers C, et al. An autosomal dominant disorder with multiple deletions of mitochondrial DNA starting at the D-loop region. *Nature* 1989;339:309-11.
27. Suzuki Y, Nishimaki K, Taniyama M, et al. Lipoma and ophthalmoplegia in mitochondrial diabetes associated with small heteroplasmy level of 3243 tRNA(Leu(UUR)) mutation. *Diabetes Res Clin Pract* 2004;63:225-9.
28. Kearns TP, Sayre GP. Retinitis pigmentosa, external ophthalmoplegia and complete heart block. *Ophthalmology* 1958;60:280-9.
29. Hasegawa H, Matsuoka T, Goto Y, et al. Strongly succinate dehydrogenase-reactive blood vessels in muscle from patients with mitochondrial myopathy, encephalomyopathy, lactic acidosis and stroke-like episodes. *Ann Neurol* 1991;29:601-5.
30. DiMauro S. Mitochondrial myopathies: what next? *J Inher Metab Dis* 1996;19:489-503.
31. De Coo IF, Renier WO, Ruitenbeek W, et al. A 4-base pair deletion in the mitochondrial cytochrome b gene associated with parkinsonism/MELAS overlap syndrome. *Ann Neurol* 1999;45:130-3.
32. Vallance HD, Jevon G, Wallace DC, et al. A case of sporadic infantile histiocytoid cardiomyopathy caused by the A8344G (MERRF) mitochondrial DNA mutation. *Pediatr Cardiol* 2004;25:338-40.
33. DiMauro S, Schon EA. Mitochondrial respiratory-chain diseases. *N Engl J Med* 2003;348:2656-68.
34. Van den Ouweland JM, Lemkes HH, Ruitenbeek W, et al. Mutation in mitochondrial tRNA(Leu)(UUR) gene in a large pedigree with maternally transmitted type II diabetes mellitus and deafness. *Nat Genet* 1992;1:368-71.
35. Van den Ouweland JM, Lemkes HH, Gerbitz KD, et al. Maternally inherited diabetes and deafness (MIDD): a distinct subtype of diabetes associated with a mitochondrial tRNA(Leu)(UUR) gene point mutation. *Muscle Nerve* 1995;3:312-30.
36. Chen YN, Liou CW, Huang CC, et al. Maternally inherited diabetes and deafness (MIDD) syndrome: a clinical and molecular genetic study of a Taiwanese family. *Chang Gung Med J* 2004;27:66-73.
37. Chinnery PF, Elliott C, Green GR, et al. The spectrum of hearing loss due to mitochondrial DNA defects. *Brain* 2000;123:82-92.
38. Nijveldt R, Serne EH, Sepers JM, et al. A man with diabetes and heart failure. *Lancet* 2004;364:636.
39. Man PY, Turnbull DM, Chinnery PF. Leber hereditary optic neuropathy. *J Med Genet* 2002;39:162-9.
40. Harding AE, Hammans SR. Deletions of the mitochondrial genome. *J Inher Metab Dis* 1992;15:480-6.
41. Mattiazzi M, Vijayvergiya C, Gajewski CD, et al. The mtDNA T8993G (NARP) mutation results in an impairment of oxidative phosphorylation that can be improved by antioxidants. *Hum Mol Genet* 2004;13:869-79.
42. Marin-Garcia J, Ananthakrishnan R, Korson M, et al. A. Cardiac mitochondrial dysfunction in Leigh syndrome. *Pediatr Cardiol* 1996;17:387-9.
43. Agapitos E, Pavlopoulos PM, Patsouris E, et al. Subacute necrotizing encephalomyelopathy (Leigh's disease): a clinicopathologic study of ten cases. *Gen Diagn Pathol* 1997;142:335-41.
44. Chol M, Lebon S, Benit P, et al. The mitochondrial DNA G13513A MELAS mutation in the NADH dehydrogenase 5 gene is a frequent cause of Leigh-like syndrome with isolated complex I deficiency. *J Med Genet* 2003;40:188-91.
45. Finsterer J. Mitochondriopathies. *Eur J Neurol* 2004;11:163-86.
46. Suzuki Y, Suzuki S, Hinokio Y, et al. Diabetes associated with a novel 3264 mitochondrial tRNA(Leu)(UUR) mutation. *Diabetes Care* 1997;20:1138-40.
47. Leonard JV, Schapira AHV. Mitochondrial respiratory chain disorders II: neurodegenerative disorders and nuclear gene defects. *Lancet* 2000;355:389-94.

48. Hirano M, Nishigaki Y, Marti R. Mitochondrial neurogastrointestinal encephalomyopathy (MNGIE): a disease of two genomes. *Neurologist* 2004;10:8-17.
49. Nishigaki Y, Marti R, Hirano M. ND5 is a hot-spot for multiple atypical mitochondrial DNA deletions in mitochondrial neurogastrointestinal encephalomyopathy. *Hum Mol Genet* 2004;13:91-101.
50. Nishino I, Spinazzola A, Hirano M. MNGIE: from nuclear DNA to mitochondrial DNA. *Neuromuscul Disord* 2001;11:7-10.
51. Marti R, Spinazzola A, Tadesse S, et al. Definitive diagnosis of mitochondrial neurogastrointestinal encephalomyopathy by biochemical assays. *Clin Chem* 2004;50:120-4.
52. Medlej R, Wasson J, Baz P, et al. Diabetes mellitus and optic atrophy: a study of Wolfram syndrome in the Lebanese population. *J Clin Endocrinol Metab* 2004;89:1656-61.
53. Barrett TG, Bunday SE, Macleod AF. Neurodegeneration and diabetes: UK nationwide study of Wolfram (DIDMOAD) syndrome. *Lancet* 1995;346:1458-63.
54. Ajlouni K, Jarrah N, El-Khateeb M, et al. Wolfram syndrome: identification of a phenotypic and genotypic variant from Jordan. *Am J Med Genet* 2002;115:61-5.
55. Cryns K, Sivakumaran TA, van den Ouweland JM, et al. Mutational spectrum of the WFS1 gene in Wolfram syndrome, nonsyndromic hearing impairment, diabetes mellitus, and psychiatric disease. *Hum Mutat* 2003;22:275-87.
56. Barrientos A, Casademont J, Saiz A, et al. Autosomal recessive Wolfram syndrome associated with an 8.5-kb mtDNA single deletion. *Am J Hum Genet* 1996;58:963-70.
57. Moraes CT, Shanske S, Tritschler HJ, et al. MtDNA depletion with variable tissue expression: a novel genetic abnormality in mitochondrial diseases. *Am J Hum Genet* 1991;48:492-501.
58. Barth PG, Valianpour F, Bowen VM, et al. X-linked cardioskeletal myopathy and neutropenia (Barth syndrome): an update. *Am J Med Genet* 2004;126A:349-54.
59. Kuijpers TW, Maianski NA, Tool AT, et al. Neutrophils in Barth syndrome (BTSS) avidly bind annexin-V in the absence of apoptosis. *Blood* 2004;103:3915-23.
60. Pestronk A. Neuromuscular Disease Center, Washington University. 2003. <http://www.neuro.wustl.edu/neuromuscular/>.
61. Lodi R, Rajagopalan B, Bradley JL, et al. Mitochondrial dysfunction in Friedreich's ataxia: from pathogenesis to treatment perspective. *Free Radic Res* 2002;36:461-6.
62. Schapira AHV. The 'new' mitochondrial disorders. *J Neurol Neurosurg Psychiatry* 2002;72:144-9.
63. Bauer PW, Geers AE, Brenner C, et al. The effect of GJB2 allele variants on performance after cochlear implantation. *Laryngoscope* 2003;113:2135-40.
64. Hofmann S, Rothbauer U, Muhlenbein N, et al. The C66W mutation in the deafness dystonia peptide 1 (DDP1) affects the formation of functional DDP1/TIM13 complexes in the mitochondrial intermembrane space. *J Biol Chem* 2002;277:23287-93.
65. Roesch K, Curran SP, Tranebjaerg L, et al. Human deafness dystonia syndrome is caused by a defect in assembly of the DDP1/TIMM8a-TIMM13 complex. *Hum Mol Genet* 2002;11:477-86.
66. Binder J, Hofmann S, Kreisel S, et al. Clinical and molecular findings in a patient with a novel mutation in the deafness-dystonia peptide (DDP1) gene. *Brain* 2003;126:1814-20.
67. Tranebjaerg L, Elverland HH, Fagerheim T. DFNA7. *Adv Otorhinolaryngol* 2000;56:97-100.
68. Van Goethem G, Mercelis R, Lofgren A, et al. Patient homozygous for a recessive POLG mutation presents with features of MERRF. *Neurology* 2003;61:1811-3.
69. Gerbitz KD, van den Ouweland JM, Maassen JA, et al. Mitochondrial diabetes mellitus: a review. *Biochim Biophys Acta* 1995;1271:253-60.
70. Antonicka H, Mattman A, Carlson CG, et al. Mutations in COX15 produce a defect in the mitochondrial heme biosynthetic pathway, causing early-onset fatal hypertrophic cardiomyopathy. *Am J Hum Genet* 2003;72:101-14.
71. Brunmair B, Lest A, Staniek K, et al. Fenofibrate impairs rat mitochondrial function by inhibition of respiratory complex I. *J Pharmacol Exp Ther* 2004;311:109-14.
72. Finsterer J, Haberler C, Schmiedel J. Deterioration of Kearns-Sayre syndrome following articaïne administration for local anesthesia. *Clin Neuropharmacol* 2005;28:148-9.
73. Sztark F, Payen JF, Piriou V, et al. Cellular energy metabolism: physiologic and pathologic aspects. *Ann Fr Anesth Reanim* 1999;18:261-9.
74. Riess ML, Kevin LG, McCormick J, Jiang MT, Rhodes SS, Stowe DF. Anesthetic preconditioning: the role of free radicals in sevoflurane-induced attenuation of mitochondrial electron transport in Guinea pig isolated hearts. *Anesth Analg* 2005;100:46-53.
75. Riess ML, Eells JT, Kevin LG, Camara AK, Henry MM, Stowe DF. Attenuation of mitochondrial respiration by sevoflurane in isolated cardiac mitochondria is mediated in part by reactive oxygen species. *Anesthesiology* 2004;100:498-5.
76. Wei YH, Lin TN, Hong CY, Chiang BN. Inhibition of the mitochondrial Mg<sup>2+</sup>-ATPase by propranolol. *Biochem Pharmacol* 1985;34:911-7.
77. Cocco T, Cucecchia G, Montedoro G, Lorusso M. The antihypertensive drug carvedilol inhibits the activity of mitochondrial NADH-ubiquinone oxidoreductase. *J Bioenerg Biomembr* 2002;34:251-8.
78. Silva MF, Ruiter JP, Illst L, et al. Valproate inhibits the mitochondrial pyruvate-driven oxidative phosphorylation in vitro. *J Inherit Metab Dis* 1997;20:397-400.
79. Agostino A, Valletta L, Chinnery PF, et al. Mutations of ANTI, Twinkle, and POLG1 in sporadic progressive external ophthalmoplegia (PEO). *Neurology* 2003;60:1354-6.
80. Walker UA. Inherited and acquired disorders of mitochondrial DNA. *Schweiz Rundsch Med Prax* 2002;91:2129-38.
81. Walker UA, Bauerle J, Laguno M, et al. Depletion of mitochondrial DNA in liver under antiretroviral therapy with didanosine, stavudine, or zalcitabine. *Hepatology* 2004;39:311-7.
82. De Lonlay P, Valnot I, Barrientos A, et al. A mutant mitochondrial respiratory chain assembly protein causes complex III deficiency in patients with tubulopathy, encephalopathy and liver failure. *Nat Genet* 2001;29:57-60.