

Yellow nail syndrome with complete triad

N. Kuwahara*, T. Homma, H. Sagara

Division of Allergology and Respiratory Medicine, Department of Internal Medicine, Showa University School of Medicine, Shinagawa-ku, Tokyo, Japan. *Corresponding author: kuwhrnaota@gmail.com

Figure 1. Visual inspection of the patient's hands

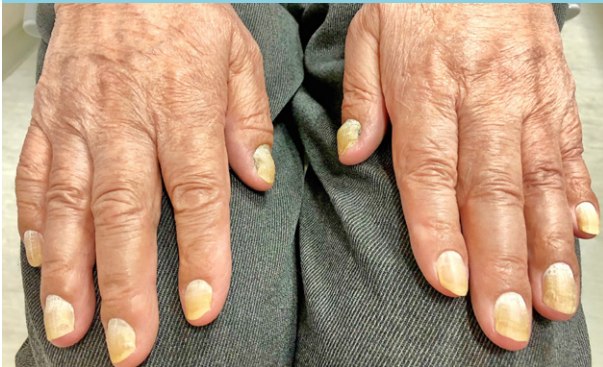
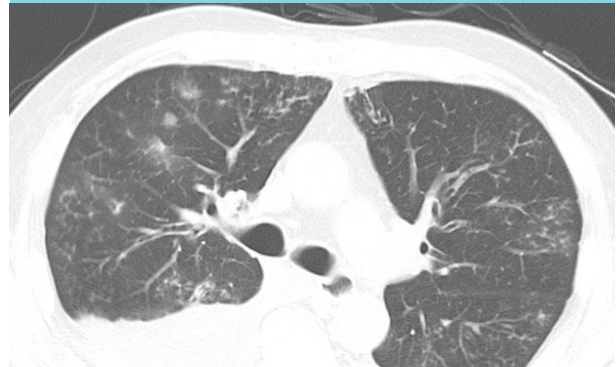

Figure 2. Chest computed tomography scan



CASE REPORT

A 77-year old man presented with a month history of edema on both legs. Diffuse panbronchiolitis (DPB) was diagnosed a year prior to his current symptoms and was treated with erythromycin, but the treatment was discontinued due to poor adherence. He had no sinus manifestations and did not recognize discoloration of his nails until he visited our hospital. He had non-pitting edema on both of his legs with Stemmer's sign, and auscultation revealed decreased breath sounds in both lower lung fields. Additionally, the color of his finger and toe nails were yellow (*figure 1*). Chest computed tomography scan showed newly developed bilateral pleural effusion with previous diffuse micronodules in bilateral lung fields.

(*figure 2*). Blood laboratory testing was normal, including interferon- γ release assay, and pleural effusion was exudative with lymphocyte dominant exudates, while adenosine deaminase was within the normal range. Echocardiography was normal. He was not taking any drugs where side effects could relate to yellow nails, and trial antifungal therapy (efinaconazole) did not alter discoloration of his nail.

WHAT IS YOUR DIAGNOSIS?

See page 87 for the answer to this photo quiz.