

Female urothelial cell carcinoma in a failed kidney graft of a male recipient

H.J.J. de Jongh^{1*}, E.M. van Duijnhoven², A. Rüländ³, M.M.A. Abdul Hamid³, E.J.M. Speel³, K. van de Beek⁴

¹Department of Internal Medicine, Division of Nephrology, VU Medical Center, Amsterdam, the Netherlands, ²Department of Internal Medicine, Division of Nephrology, Maastricht University Medical Centre, Maastricht, the Netherlands, ³Department of Pathology, GROW-School for Oncology and Developmental Biology, Maastricht University Medical Centre, Maastricht, the Netherlands, ⁴Department of Urology, Maastricht University Medical Centre, Maastricht, the Netherlands, *corresponding author: h.dejongh@vumc.nl

ABSTRACT

We present a case of a male kidney transplant patient harbouring two kidney grafts of which one is functional. In the failed graft, he developed urothelial cell carcinoma with cells containing XX-chromosome, and female tumour cells were also found in the bladder. The patient underwent donor nephrectomy, was treated with epirubicin bladder instillations, and immunosuppression was tapered. Less than a year before re-transplantation a CT scan showed no abnormalities of the first graft. Transplantectomy before a second kidney transplantation is debated.

KEYWORDS

Donor-derived tumour, kidney transplantation, FISH, cancer, nephrectomy.

INTRODUCTION

After kidney transplantation, there is an increased risk for development of urothelial cell carcinomas including graft tumours.¹ We present a case of a male recipient with two consecutive kidney grafts in which a donor-derived urothelial cell carcinoma in the first graft and in the bladder was found harbouring a XX genotype, as detected by FISH, thus indicating that the tumour originated from the maternal donor.

Apart from a report identifying Y-chromosome status in female post-transplant non-small cell lung carcinoma patients² and two cases of sex chromosome discrepancy in kidney transplantation patients with urothelial

What was known on this topic?

There are several reports of malignancies in renal transplant grafts. In this case report a malignancy is described in a failed graft shortly after re-transplantation.

What does this add?

This case report describes the relevance of interphase cytogenetics in identifying the origin of a urothelial cell carcinoma originating from a failed kidney graft many years after transplantation. It may add to the discussion about screening protocols for malignancy after transplantation since a CT scan without IV contrast less than a year before re-transplantation showed no abnormalities.

carcinoma,^{3,4} to our knowledge, there are no other reports after organ re-transplantation about late-onset tumours where the origin of the tumours from donor cells was proven.

CASE REPORT

Nine months after kidney transplantation from a 59-year-old female, a 47-year-old man was seen in our outpatient nephrology clinic for a regular check-up. In the last few days, the patient had developed macroscopic haematuria. His medication consisted of tacrolimus, mycophenolate, metoprolol, felodipine, enalapril, and atorvastatin. The patient used no alcohol or illicit drugs and had smoked 20 cigarettes a day for the last 17 years.

Medical history included end-stage renal disease probably due to hypertension in 2006, followed by transplantation of a kidney donated by his then 70-year-old mother with immediate graft function. In 2012 graft function deteriorated due to membranous glomerulonephritis. In January 2013, the patient was re-transplanted pre-emptively with a kidney from another living donor. Prior to re-transplantation, computed tomography (CT) scanning of the first kidney graft showed no abnormalities.

The patient had no other symptoms besides haematuria. There was no dysuria, no fever and no weight loss. Physical examination revealed no abnormalities. The urine showed > 200 erythrocytes/ μl without dysmorphic erythrocytes, 51-140/ μl leucocytes and a 24-hour urine collection showed 0.24 g/l protein with a creatinine of 11.1 mmol/l. A urine culture showed no bacterial growth. The serum creatinine was stable at 136 $\mu\text{mol/l}$.

The patient was referred to a urologist. A cystoscopy was performed and showed a papillary lesion on the left posterior bladder wall, without lesions around any of the four ureteral ostia. CT-intravenous pyelogram showed shrunken native kidneys and a tumour in the renal pelvis of the first kidney graft without lymph node metastasis. The functioning graft showed no abnormalities.

The patient underwent transplantectomy of the failed first kidney graft. The kidney graft showed a high-grade pT3 papillary urothelial cell carcinoma of the renal pelvis with infiltration into the kidney, however not in the ureter.

Because of the malignancy, immunosuppression was tapered to tacrolimus monotherapy, after a biopsy of the functioning kidney graft was performed and showed no signs of rejection. A transurethral bladder resection (TUR) showed a pTaG2 papillary urothelial cell carcinoma of the right posterior bladder wall.

Chromosome copy number analysis of the explanted graft and bladder tumour by FISH using a chromosome X and Y probe mixture (Aneuvysion Multicolor DNA Probe Kit, Abbott Molecular, Hoofddorp, NL)⁵ showed malignant cells with a XX genotype and no Y chromosome, indicating that not only the graft tumour, but also the bladder tumour originated from cells of the maternal donor kidney (figure 1). Subsequent screening of the donor was negative for urothelial carcinoma.

The patient was treated with epirubicin instillations of the bladder. Two months later, a cystoscopy showed no abnormalities. Six months later, ten small papillary urothelial cell carcinomas were removed from the bladder wall, again with XX genotype, followed by new prophylactic epirubicin instillations. During the next year, the patient received multiple epirubicin instillations and underwent regular cystoscopies, which showed no recurrences. The patient remained on tacrolimus monotherapy with stable kidney graft function (creatinine 130 $\mu\text{mol/l}$).

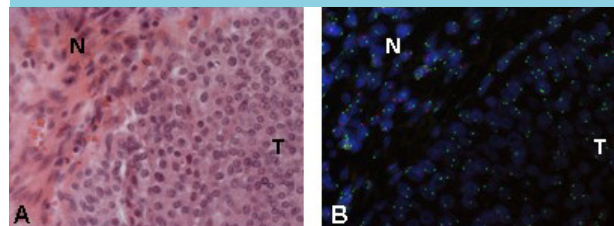
In March 2016, the patient developed painful pathological inguinal lymph nodes. MRI of the lower abdomen and pelvis revealed enlarged inguinal, iliac and aortic lymph nodes and thickening of the bladder wall, suspect for tumour infiltration. A new TUR of the bladder wall was performed and a lymph node was removed, showing metastasis of urothelial cell carcinoma, again with XX genotype. A CT scan showed multiple millimetric nodules in the lungs and one lesion in the liver. A diagnosis of metastasised urothelial cell carcinoma was made. The patient was referred to an oncologist, who started palliative chemotherapy consisting of six cycles of gemcitabine/carboplatin.

DISCUSSION

This case shows a patient who received a living related donor kidney from his mother and subsequently developed urothelial cell carcinoma in that graft kidney and in the bladder, after he had already undergone a second transplantation because of graft failure. We provided evidence, using XY-specific FISH analysis of the malignant cells, that both the original tumour and the recurrent bladder tumours originated from cells from the maternal graft.

Current literature does not recommend standard imaging⁶ or transplantectomy without a clinical indication after graft failure,⁷ which might have improved the prognosis of this patient. The decision regarding transplantectomy before a re-transplantation is complicated. Careful consideration of the advantages and disadvantages for the individual patient is needed. Our patient was re-transplanted pre-emptively. It was decided not to perform transplantectomy, because this would have led to a period of dialysis and possibly more operative risks and also possible HLA immunisation against the new donor.

Figure 1. Representative images of A) a haematoxylin-eosin stained formalin fixed, paraffin embedded tissue section of the urothelial cell carcinoma (T) and flanking normal stromal cells (N), and B) FISH analysis showing the XX genotype (two gene signals/cell nucleus) of the female tumour cells and the XY genotype (a green and a red signal per nucleus, respectively) of the host stromal cells



Screening for tumours in a failed graft and transplantectomy of a first graft before re-transplantation remains a difficult issue. In our clinic, CT scanning of the abdomen without IV contrast in the preparation before re-transplantation is a standard procedure. The CT scan without IV contrast preceding re-transplantation showed no abnormalities of the first kidney graft. IV contrast is relatively contraindicated for many patients with a kidney graft. The relevance of regular screening with ultrasound and/or PET-CT in early detection of renal graft tumours is also unclear. In our centre, we generally remove failed kidney grafts when patients are dependent on dialysis and have oliguria. In other centres, the failed graft remains in situ. Hence, with regard to transplantectomy of failed kidney grafts, there is also no consensus.

In conclusion, we have proven the relevance of interphase cytogenetics to identify the origin of a tumour in organ transplant recipients, especially after re-transplantation with two donor organs in situ. At this time, the value of screening for graft tumours is unproven.

DISCLOSURES

All authors declare no conflict of interest. No funding or financial support was received.

REFERENCES

1. Viart L, Surga N, Collon S, Jaureguy M, Elalouf V, Tillou X. The high rate of de novo graft carcinomas in renal transplant recipients. *Am J Nephrol.* 2013;37:91-6.
2. Chen W, Brodsky SV, Zhao W, et al. Y-chromosome status identification suggests a recipient origin of posttransplant non-small cell lung carcinomas: chromogenic in situ hybridization analysis. *Hum Pathol.* 2014;45: 1065-70.
3. Michel Ortega RM, Wolff DJ, Schandl CA, Drabkin HA. Urothelial carcinoma of donor origin in a kidney transplant patient. *J Immunother Cancer.* 2016 18;4:63.
4. Takaoka E, Miyazaki J, Kimura T, et al. Concurrent urothelial carcinoma in the renal pelvis of an allograft kidney and native recipient bladder: evidence of donor origin. *Jpn J Clin Oncol.* 2014;44:366-9.
5. Hopman AHN, Kamps MAF, Speel EJM, Schapers RFM, Sauter G, Ramaekers FCS. Identification of chromosome 9 alterations and p53 accumulation in isolated carcinoma in situ of the urinary bladder versus carcinoma in situ associated with carcinoma. *Am J Pathol.* 2002;161:1119-25.
6. Wong G, Li MW, Howard K, et al. Screening for renal cancer in recipients of kidney transplantation. *Nephrol Dial Transplant.* 2011;26:1729-39.
7. Dinis P, Nunes P. Kidney Retransplantation: Removal or Persistence of the Previous Failed Allograft? *Transpl Proc.* 2014;46:1730-4.