

A 73-year-old male with jaundice and acute kidney injury

H. van der Wijngaart^{1*}, B. van Dam¹, J.G. van den Berg², Y.H.M. Krul-Poel¹, M. Klemm-Kropp³, W.A. Bax¹

Department of ¹Internal Medicine and ³Gastroenterology, Medical Center Alkmaar, the Netherlands, ²Symbiant Pathology Expert Centre, Zaandam, the Netherlands, *corresponding author: e-mail: h.vander.wijngaart@mca.nl

A 73-year-old male was admitted with jaundice, mild abdominal pain, dark-coloured urine and light-coloured stools. His medical history included a cholecystectomy 13 years earlier and prostate carcinoma, which was treated with radiotherapy and was in remission with no current medication.

On physical examination severe jaundice was observed. His blood pressure was 104/60 mmHg with tachycardia of 104 beats/min. He had no fever. Examination of the abdomen revealed no abnormalities.

Laboratory tests included an elevation of total bilirubin of 678 $\mu\text{mol/l}$ (conjugated bilirubin 512 $\mu\text{mol/l}$) with elevated alkaline phosphatase, a serum creatinine of 650 $\mu\text{mol/l}$, but no electrolyte abnormalities. Cell counter indices showed leucocytosis ($25.2 \times 10^9/l$) and thrombocytopenia ($86 \times 10^9/l$). Haemoglobin was 8.7 mmol/l. No biochemical signs of haemolysis were found. Schistocytes were not seen in a peripheral blood smear. A urine sample showed no erythrocytes, and no proteinuria or microalbuminuria. The sodium concentration in the urine was 51 mmol/l. Ultrasonography of the abdomen revealed normal liver parenchyma, but multiple gallstones in the common bile duct, with associated bile duct dilation. Kidney size was normal with no signs of urinary tract obstruction. An endoscopic retrograde cholangiopancreatography (ERCP) was performed. Because of fibrosis due to earlier ulceration, the ampulla of Vater was in an unfavourable location. Therefore it was decided to ensure proper drainage of bile by positioning a drain in the common bile duct. Despite hyperhydration and proper drainage of bile with normalisation of hyperbilirubinaemia and clinical improvement, kidney function did not recover. The patient was therefore treated with haemodialysis and a kidney biopsy was obtained (*figure 1 and 2*).

Figure 1. Casts are located in the tubules. There are no glomerular abnormalities (Pas-D staining was used)

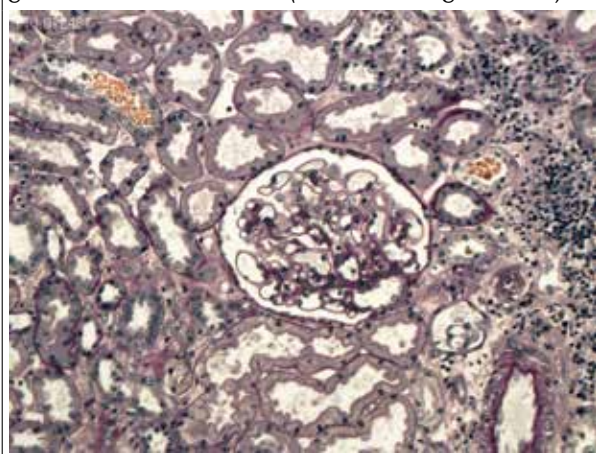
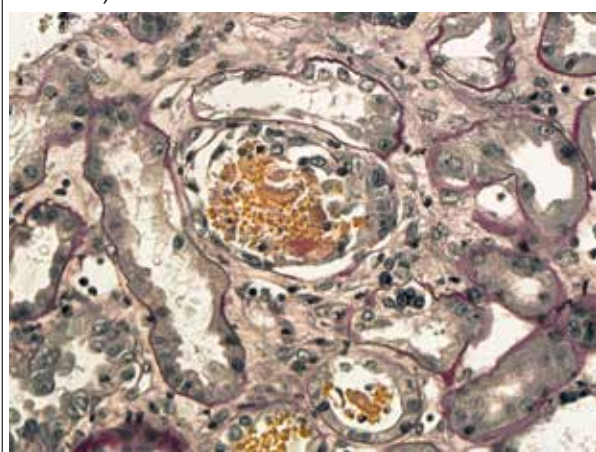


Figure 2. Tubular obstruction by casts. Tubular epithelial cells show reactive changes (Pas-D staining was used)



WHAT IS YOUR DIAGNOSIS?

See page 99 for the answer to this photo quiz.

ANSWER TO PHOTO QUIZ (PAGE 95)

A 73-YEAR-OLD MALE WITH JAUNDICE AND ACUTE KIDNEY INJURY

DIAGNOSIS

The kidney biopsy showed bile casts in the tubules, which strongly suggests bile cast nephropathy as the cause of acute renal failure.

Bile cast nephropathy, or cholaemic nephrosis, is a rare cause of renal injury. Only a few cases of bile cast nephropathy have been reported over the past decade.^{1,5} The exact pathophysiological mechanism of bile cast nephropathy is as yet unknown. It is believed that hyperbilirubinaemia causes damage to the kidney in several ways: first, bile casts cause tubular obstruction (as was seen in this patient) and, second, the presence of high concentrations of bile in the renal tubules may be toxic to tubular cells, resulting in impairment of tubular function.² Hypertrophy of the tubular cells is observed in patients with bile cast nephropathy.¹ Also in our patient, tubular epithelial cells revealed pronounced reactive changes (*figure 2*). It must be emphasised, however, that it is often difficult to completely rule out involvement of an additional pre-renal cause of renal insufficiency. On the other hand, in this case the sodium concentration in the urine at presentation and remaining renal failure after complete normalisation of blood pressure would make this less likely. The diagnosis bile cast nephropathy can be suspected when extreme hyperbilirubinaemia and acute kidney failure coincide. It may be confirmed by the observing bile casts in a kidney

biopsy and suggested by observing bile crystals in a urine sample. Bile crystals (which were not seen in our patient) may sometimes be observed in urine although their role in pathophysiology remains unclear.⁵ Bile cast nephropathy is treated by reversing the liver injury.¹ Recovery of renal function may take several weeks.

In this patient, the liver injury was treated by placing a drain in the common bile duct. Serum bilirubin levels normalised within a few weeks. He remained on haemodialysis for 5 weeks, after which kidney function recovered.

REFERENCES

1. van Slambrouck CM, Salem F, Meeham SM, Chang A. Bile cast nephropathy is a common pathologic finding for kidney injury associated with severe liver dysfunction. *Kidney Int.* 2013;84:192-7.
2. Betjes MG, Bajema I. The pathology of jaundice-related renal insufficiency: cholemic nephrosis revisited. *J. Nephrol.* 2006;19:229-33.
3. Bredewold OW, de Fijter JW, Rabelink T. A case of mononucleosis infectiosa presenting with cholemic nephrosis. *NDT Plus.* 2011;4:170-2.
4. Song J, Chang A. Jaundice-associated acute kidney injury. *NDT Plus.* 2009;2:82-3.
5. Olde Bekkink M, Verhave JC, Vervoort G. Een icterische patiënt met acute nierinsufficiëntie. *Ned Tijdschr Geneeskd.* 2012;156: A4153.