

A case of multiple aortic thrombi

R.L. Braam¹, C.A.J.M. Gaillard^{1*}, B.W. Ike², E.C. Hagen¹

¹Department of Internal Medicine, e-mail: c.gaillard@meandermc.nl, ²Department of Radiology, Meander Medical Centre, PO Box 1502, 3800 BM Amersfoort, the Netherlands,

*corresponding author

CASE REPORT

A 50-year-old woman was admitted to our hospital with a ten-day history of fever, vomiting and dehydration. Her medical history revealed hypertension, hypercholesterolaemia, pyelonephritis and renal insufficiency for which peritoneal dialysis had been started seven months earlier. On physical examination no further clues as to the cause of her illness could be found. Chest X-ray showed no abnormalities. After blood cultures were taken antibiotic treatment was started with cefuroxim and gentamicin. Because of progressive jaundice abdominal ultrasonography was performed, which showed no abnormalities. A CT scan of the abdomen showed a large thrombus in the right ventricle (*figure 1*), which was confirmed by echocardiography. Also two sites of thrombi were found in the aorta: at the height of the renal arteries and just above the aortic bifurcation (*figure 2*). The last thrombus appeared to contain gas.

WHAT IS YOUR DIFFERENTIAL DIAGNOSIS?

See page 306 for the answer to this photo quiz.

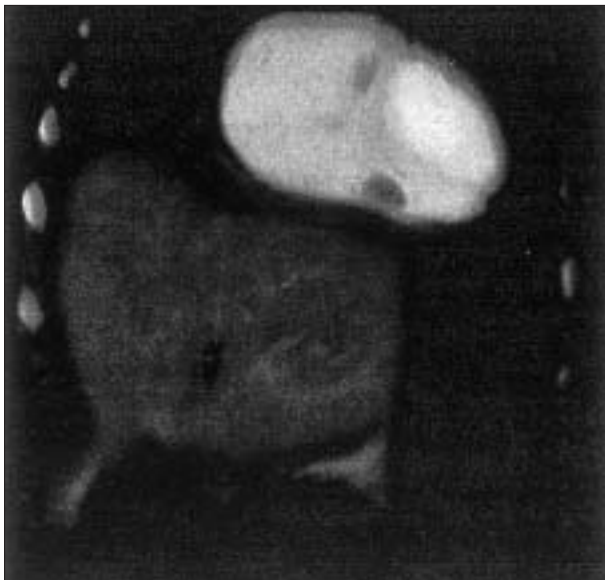


Figure 1
Abnormality in the right ventricular cavity suggestive of thrombus, which was later also confirmed by echocardiography

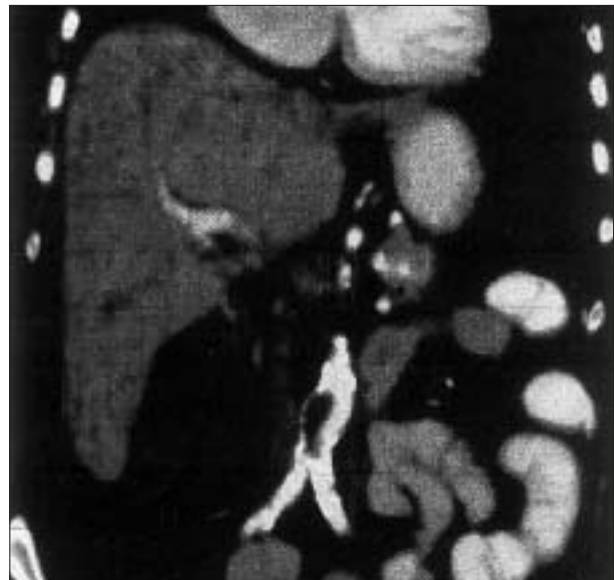

Figure 2
Gas-containing thrombus, localised at the aortic bifurcation

A colour version of these figures is available on www.njmonline.nl