

# An Aruban man with fever, abdominal mass and eosinophilia

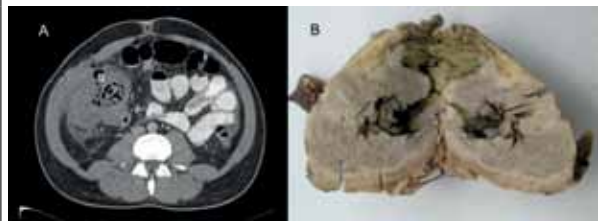
G.J. Westland<sup>1</sup>, T. Peterson<sup>2</sup>, J.A. van Raalte<sup>4</sup>, R.M.H.G. Huits<sup>3\*</sup>

<sup>1</sup>VU University, Amsterdam, the Netherlands, Departments of <sup>2</sup>Surgery, <sup>3</sup>Internal Medicine, Dr. Horacio E. Oduber Hospitaal, <sup>4</sup>Department of Pathology, Landslaboratorium, \*corresponding author: tel.: +29 7 5824749, fax: +29 7 5826163, e-mail: ralph.huits@gmail.com

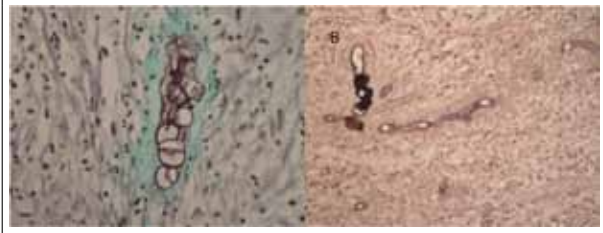
## CASE REPORT

A 30-year-old Aruban man with a history of diabetes presented with abdominal pain and fever, six weeks after a laparoscopic appendectomy for acute appendicitis. Ultrasound of the abdomen showed abscess formation in the right lower quadrant. A drain was percutaneously inserted into the mass and intravenous antibiotic treatment with piperacillin-tazobactam was initiated. The following day, computed tomography of the abdomen (*figure 1A*) showed a thick-walled cavity, filled with air and fluid and with unclear anatomical relation to the ascending colon. The patient did not improve: inflammatory parameters persisted and marked eosinophilia was present (7000 cells/ $\mu$ l). A fistula developed to the appendectomy scar. Ten days after admission a laparotomy was performed and the infiltrate, which involved the coecum and part of the ascending colon, was removed by right hemicolectomy.

**Figure 1 (A and B).** A) Computed tomography showing a thick-walled infiltrate in the right lower abdomen after insertion of a drain. The anatomical relation to the ascending colon is not clear. B) Hemicolectomy specimen, opened in longitudinal direction viewing coecum and ascending colon. On the left side the terminal ileum.



**Figure 2 (A and B).** Grocott's methenamine silver stain. A) A cluster of zygosporae. The surrounding eosinophilic material (Splendore-Hoeppli phenomenon) stains green. B) Spores germinating into hyphae and a branching hyphen.



On macroscopic examination the coecum and ascending colon showed a 15 x 9 x 7 cm solid white lesion surrounding the colon (*figure 1B*). Histopathological examination showed fibrous tissue with necrosis extending towards the intestinal lumen. Using Grocott's methenamine silver stain, thin-walled, broad septate hyphae were found in this tissue. The hyphae surrounded by an eosinophilic sheath constitute the so-called Splendore-Hoeppli phenomenon. Large clusters of zygosporae were also present (*figure 2A and 2B*). In retrospect, a sporadic zygosporae was present in the removed appendix.

## WHAT IS YOUR DIAGNOSIS?

See page 88 for the answer to the photo quiz

## DIAGNOSIS

A diagnosis of intestinal *Basidiobolus ranarum* infection was made. Although this fungus can be cultured, the diagnosis of intestinal basidiobolomycosis is frequently established histologically by the presence of its thin-walled broad hyphae and large zygospores. These characteristic fungal elements are surrounded by eosinophilic material, the morphologically unique Splendore-Hoeppli phenomenon.<sup>1</sup>

*Basidiobolus ranarum* is a fungus of the class *Zygomycetes*, order *Entomophthorales*, which is encountered worldwide. It is frequently isolated from faecal material of amphibians and reptiles. As a human pathogen, it is known for its association with subcutaneous fat tissue infections, which may occur after traumatic inoculation.<sup>2</sup> Over the last decades, cases of intestinal basidiobolomycosis are reported with increasing frequency in both children and adults.<sup>3</sup> An association with consumption of reptile meat is postulated; in our case, the patient had eaten poached iguana. Clinically, intestinal basidiobolomycosis often mimics inflammatory bowel disease or colon carcinoma. It rarely presents with an acute condition such as appendicitis.

Unfamiliarity with this fungal infection leads to diagnostic delay and failure to include it in the differential diagnosis of fever, abdominal mass and marked eosinophilia. The outcome of intestinal basidiobolomycosis is often fatal.<sup>4</sup> Our patient made an uneventful recovery after surgery and treatment with ketoconazole 200 mg once daily for six weeks. He remains without relapse during 12 months of follow-up.

## REFERENCES

1. Geramizadeh B, Modjalal M, Nabai S, Banani A, Forootan HR, Hooshdaran F, et al. Gastrointestinal zygomycosis: a report of three cases. *Mycopathologia*. 2007;164(1):35-8.
2. Gughani HC. A review of zygomycosis due to *Basidiobolus ranarum*. *Eur J Epidemiol*. 1999; 15(10):923-9.
3. El-Shaba MH, Kamal NM. Gastrointestinal basidiobolomycosis in children: an overlooked emerging infection? *J Med Microbiol*. 2011;60(7):871-0.
4. van den Berk GE, Noorduyn LA, van Ketel RJ, van Leeuwen J, Bemelman WA, Prins JM. A fatal pseudo-tumour: disseminated basidiobolomycosis. *BMC Infect Dis*. 2006;6:140.