

# False-negative tests in breast cancer management

A. Coolen<sup>1</sup>, K. Leunen<sup>1</sup>, J. Menten<sup>2</sup>, W. van Steenbergen<sup>3</sup>, P. Neven<sup>1\*</sup>

Departments of <sup>1</sup>Gynaecology and Obstetrics, <sup>2</sup>Radiotherapy/Oncology, <sup>3</sup>Internal Medicine/Hepatology, Multidisciplinary Breast Centre (MBC), University Hospital Gasthuisberg, Leuven, Belgium, \*corresponding author: tel.: +32 16 34 46 34, fax: +32 16 34 42 05, e-mail: patrick.neven@uz.kuleuven.ac.be

## ABSTRACT

We review the sensitivity of different diagnostic tests for breast cancer management based on recent experience in a 34-year-old patient. False-negative tests at diagnosis of early disease and of relapse resulted in diagnostic and therapeutic delays.

Initial mammography and breast ultrasonography were falsely negative despite a palpable breast lump. Clinical examination and axillary ultrasound missed macroscopically involved lymph nodes. At relapse, metastatic lesions were missed despite symptoms, three years after primary treatment. CA 15-3 was normal; bone and liver metastases were missed by standard and more advanced imaging techniques including liver ultrasonography, nuclear bone scan and PET-CT scan. Worsening of clinical symptoms, lab results and abnormal tissue biopsies finally led to the diagnosis of extensive metastatic disease. Genetic screening showed an abnormality within the BRCA-1 region of unknown clinical importance.

This review highlights 1) that diagnostic tests managing symptomatic breast cancer patients may have a low sensitivity, 2) the importance of clinical findings and other markers for disease, such as lactate dehydrogenase and 3) the need for diagnostic biopsies for clinically suspect symptoms despite normal imaging and biochemistry.

## KEYWORDS

Breast cancer, investigations, metastases, sensitivity

## INTRODUCTION

In women, breast cancer is common and leads to significant morbidity and mortality. Early diagnosis of the disease and accurate recognition of life-threatening

relapses affect disease outcome. Under the age of 40, breast cancer is mostly symptomatic with a palpable lump as the most frequent presenting symptom. The diagnosis is then confirmed by a diagnostic mammography, breast ultrasound and image-guided core biopsy. If staging excludes metastases, local and systemic therapies follow. Follow-up is advised with clinical examination at regular intervals and a yearly mammogram. Appropriate technical and biochemical tests are done when suspect symptoms arise.<sup>1</sup> Routine diagnostic investigations in general are sensitive enough to confirm/reject the initial diagnosis or relapse. We critically review this sensitivity following the case of a recent patient who died of metastatic breast cancer with false-negative tests both at primary diagnosis and relapse.

## PATIENT

A 34-year-old healthy parous woman presented with a palpable lump in the left breast. In the family history, her mother was premenopausal when diagnosed with ovarian cancer and she died at the age of 50 years. The sister of her maternal grandmother had postmenopausal breast cancer and her father was treated for prostate cancer.

Four months before referral to the hospital, the same breast lump was evaluated by her general practitioner as non-suspect because the mammogram and breast ultrasound were normal; the lump was attributed to residual breast congestion due to recently stopped breastfeeding. Since the lump became firmer, she was referred to our breast unit. Clinical examination revealed a suspicious left breast lump of 35 x 30 mm in the upper inner quadrant without palpable lymph nodes (cT2N0). The repeated mammography remained normal; there was no architectural distortion or asymmetrical density. Breast ultrasound, however, showed a hyperechoic solid mass and

magnetic resonance imaging (MRI) was suspicious for a unifocal cancer. Lymph nodes were considered normal at imaging. An ultrasound-guided core biopsy revealed a grade 3 invasive and *in situ* ductal adenocarcinoma. There were no clinical signs of metastatic disease and this was confirmed by all preoperative biochemical (liver tests, serum calcium and CA 15.3) and imaging tests (chest X-ray, ultrasound of the liver and nuclear bone scan). A modified radical mastectomy with axillary clearance was performed. Pathology confirmed the malignancy, section margins were clear, the lympho-vascular space was involved and five of 14 axillary lymph nodes contained macrometastatic deposits (pT2N2). Oestrogen and progesterone receptors were moderately positive, HER-2-Neu was completely absent. Six courses of adjuvant chemotherapy (3x FEC q3w and 3x Taxotere 100 q3w) were given, followed by loco-regional radiotherapy with a total dose of 50 Gy in 25 daily fractions to the chest wall and median subclavian and parasternal lymph node area. Hormonal treatment was started during radiotherapy with monthly injections of the luteinising hormone-releasing hormone (LHRH)-agonist gosereline (Zoladex®) and a daily tablet of 20 mg of tamoxifen (Nolvadex D®). BRCA 1/2 mutation testing showed a mutation in exon 18 of the BRCA1 gene, a rare variant of unknown significance.

She was well for almost three years, but then started complaining of bone pain located in the pelvis and neck, temporarily improving with physiotherapy; biochemical markers were normal. Two months later, she was referred because of more symptoms (anorexia, bone pain, uncontrollable weight loss) and a doubled but almost normal tumour marker level: CA 15.3: 31 kU/l (normal: <30 kU/l). A bone scintigraphy and CT scan of chest and abdomen were normal. Six weeks later, CA 15.3 had risen to 81 kU/l. Lactate dehydrogenase (LDH), which had not been measured for six months, mounted to 1122 U/l (normal: 240-480 U/l), alanine aminotransferase and aspartate aminotransferase were 59 U/l and 77 U/l respectively (normal <31 U/l), whereas alkaline phosphatase was normal. A FDG-PET-CT scan at this stage was completely negative. Based on the clinical complaints and the increased CA 15.3 and LDH levels, tamoxifen was switched to the oral aromatase inhibitor anastrozole (Arimidex®) while the goserelin implants were continued. Given the discordance between the negative imaging and the patient's symptoms and biochemistry suggesting disease progression, an at random liver biopsy was performed. Frozen section of the biopsies was normal. The biopsy was complicated by severe intra-abdominal bleeding enhanced by an isolated thrombocytopenia ( $32 \times 10^9/l$ ; normal range: 150 to  $450 \times 10^9/l$ ). A platelet count had been done before the biopsy but unfortunately the result had been unnoticed. Blood platelets further dropped and levels of liver function tests were mounting. A hypovolaemic shock had to be

stabilised with colloids, packed cells, platelet transfusion and intensive care management. The final pathology report of the liver biopsy stated necrotic hepatitis, most likely 'drug-related'.

All current medication (anastrozole, mirtazapin, antioxidants, zolpidem) and mistletoe, which she informed us she was using as complementary therapy to affect disease progression, were immediately stopped. The platelet count did not improve. A bone marrow aspiration and bone biopsy were performed, both confirming metastatic disease. Additional immuno-histochemical stainings on the earlier liver biopsy revealed tumour cells. Chemotherapy with paclitaxel ( $80 \text{ mg/m}^2$ ) was given every two out of three weeks because of haematological intolerance. The patient improved temporarily with normalising biochemistry. A CT scan after six courses showed diffuse blastic bone metastases that remained stable on CT following the 18th course. Bone scintigraphy and liver ultrasound remained negative for metastases. Shortly after interruption of the chemotherapy, again, an important elevation of liver tests and LDH occurred (*figure 1*). Her condition deteriorated and comfort therapy was started with the help of the palliative support team. She died 10 months after the diagnosis of metastatic breast cancer.

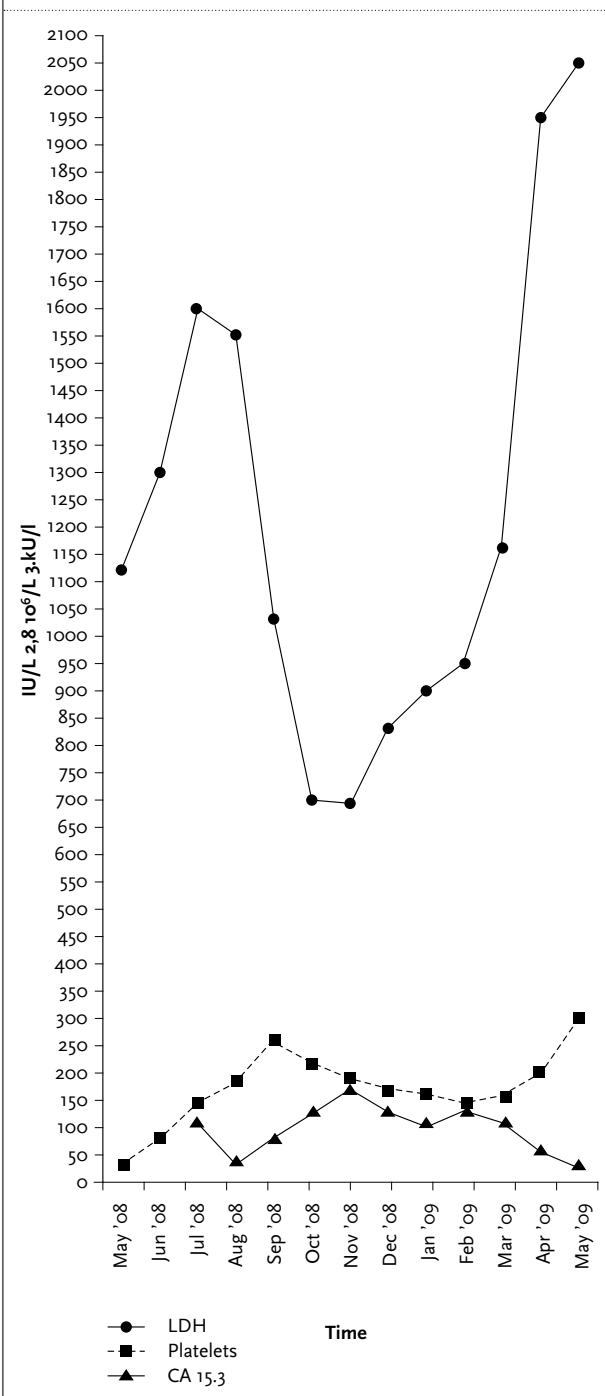
## REVIEW OF THE LITERATURE

Standard diagnostic tests in managing breast cancer may sometimes fail in detecting loco-regional or metastatic disease, as was seen in our patient. Therefore we have reviewed the frequency of false-negative tests in breast cancer management and their impact on treatment and outcome. *Table 1* reviews the frequency each test is falsely negative.

### Tests at diagnosis

1. Breast lump: An early compared with late diagnosis of breast cancer ensures a more favourable outcome.<sup>1</sup> Delay in diagnosis can occur at different phases during the diagnostic process.<sup>2</sup> Any breast lump requires a clinical examination, imaging of the breast and breast biopsy, also known as 'triple diagnosis'.<sup>3-7</sup> Normal imaging and a hypothesis of 'residual milk retention' were the reason why our patient did not undergo a breast biopsy, which undoubtedly delayed diagnosis. Delay in diagnosis is the commonest basis for litigation in breast cancer management, but the effect of delay in diagnosis on survival remains controversial once a breast lump is palpable.<sup>8</sup> The adverse impact of delay in presentation on survival of breast cancer is mainly seen if delay leads to a more advanced stage of disease.<sup>9-11</sup> Furthermore, the impact of a false-negative mammogram on breast cancer

**Figure 1.** Change of lactate dehydrogenase (LDH), platelets and CA 15.3 from diagnosis of metastatic disease until death



**Table 1.** Overview of false-negative tests

Problem	False-negative test	Discussion
<b>Primary diagnosis</b>		
Palpable malignant breast lump	Mammography/ultrasound	Sensitivity variable (30-90%), improving with addition of ultrasound (94-97%) <sup>3-7</sup> More difficult in premenopausal women and in case of dense breasts
	MRI	Indicated if other tests are inconclusive, search for occult tumours, lobular cancers, monitoring response to neoadjuvant therapy, women with implants, suspected lesions in a scar, screening high risk patients. No place as routine preoperative imaging <sup>14,15</sup>
Positive lymph node involvement	Clinical investigation	Involvement can be estimated by several risk factors. False-negative in 30-60%, false-positive in 30-40% <sup>17-19</sup>
	Ultrasound	In expert hands moderately sensitive 26-87%, fairly specific 56-98% <sup>20</sup>
<b>Progressive disease</b>		
Liver metastases	Ultrasound of liver	General complaints Rising CA 15.3, LDH, deteriorating liver function and thrombocytopenia (see table 2)
	CT scan	Considered appropriate, limitations due to operator variability, body habitus, patient compliance, evaluation of subcostal area. Small lesions within fatty/necrotic liver difficult to depict <sup>1</sup>
	PET/CT scan	Identified in porto-venous phase. Hypervascular lesions can be missed. Sensitivity 92% <sup>1</sup>
	PET/CT scan	FDG uptake in many lesions as high as in healthy liver tissue. Small lesions can be missed. Sensitivity 76%. Superior to conventional imaging, performance comparable with CT scan <sup>1,25</sup>
	Liver biopsy	Necrotic hepatitis, most likely toxic in origin. Tamoxifen, anastrozole and mistletoe are described to cause hepatotoxicity and were stopped immediately. <sup>36-41</sup> Extra assessment with cytokeratin 7 immunostain was necessary to detect metastatic cells
Bone metastases	Bone scintigraphy	Sensitivity 67-92%, specificity 80-99%, especially for osteoblastic or mixed metastases <sup>1,24</sup>
	CT scan	Sensitivity only 67% <sup>1</sup>
	PET/CT-scan	Relatively low detection rate, especially those of osteoblastic type. Sensitivity 87-92%, specificity 92%. <sup>1,24,26</sup> ! Bone core biopsy was necessary for obtaining diagnosis of osteoblastic metastases

survival, in symptomatic breast cancer, may therefore be of less importance than when this happens in asymptomatic disease.<sup>12</sup>

Mammograms have an overall sensitivity of 30 to 90%.<sup>3,7,13</sup> The largest study of false-negative mammograms in women with a malignant symptomatic breast lump has shown that mammograms in this population are negative in 10%. Of these false-negative results, 42%

are considered to be potentially avoidable oversights.<sup>13</sup> Patients with false-negative mammograms are likely to be younger, usually with denser breast tissue, smaller tumours and more tumours located in the upper outer quadrant. Although some studies recognise a high rate (24%) of a simultaneous false-negative ultrasound with a false-negative mammogram, ultrasound has been reported to significantly raise the sensitivity of breast cancer

imaging to 94 to 97% and may become a very valuable adjunctive diagnostic tool.<sup>13</sup> MRI has sensitivity rates of approximately 90%, but low specificity rates and high cost, and is of most use in select cases (*table 1*).<sup>14,15</sup>

Overall, young age as a poor prognostic factor might have been more important in our case than delay in diagnosis. In a multivariate model with stage and adjuvant therapy amongst different prognostic variants, young age remained a bad prognostic factor for breast cancer specific survival, especially in case of triple negative and HER-2 positive breast cancers.<sup>16</sup> Although the overall sensitivity of breast cancer imaging is high (up to 94%), it should be emphasised that a negative mammogram and ultrasound should not influence the management of a suspect clinical lesion.

**Lymph nodes:** The preoperative detection of nodal and systemic metastases in those most likely to have disseminated disease affects patient management and prognosis. In our case, the preoperative evaluation of the axilla was falsely negative. A normal clinical assessment of the axilla is of little value.<sup>17-19</sup> Axillary ultrasound is more sensitive and specific to select patients eligible for the sentinel lymph node procedure.<sup>20</sup> Since the sentinel lymph node procedure was not considered in our case, this false-negative finding did not affect management of our patient.

There have been many published reports and models on the correlation between patient and tumour characteristics and lymph node status. Tumour size seems to be the most powerful predictor of axillary node involvement.<sup>19,21-23</sup> Voogd *et al.* showed an odds ratio for node positivity of 3.53 with tumours >3 cm.<sup>19</sup> On the other hand it has been found that 1 to 15% of patients with a negative sentinel node biopsy still have other affected lymph nodes in the same node region.<sup>20</sup>

#### Tests at relapse

In our patient, when progressive disease was suspected based on clinical symptoms and haematological changes, several imaging tests were again falsely negative (see also *table 1*). CA 15.3 was increasing over time, although remaining within reference values until two months before the start of palliative chemotherapy. An increase in LDH, a deteriorating liver function and thrombocytopenia all pointed towards systemic disease whilst bone scintigraphy and both ultrasound and CT scan of the liver remained normal. Although there is no consensus on the most sensitive imaging method, conventional imaging procedures to screen for metastatic disease are chest X-ray, abdominal ultrasound and bone scintigraphy. The last-mentioned is widely accepted for detection of osteoblastic or mixed osteolytic-osteoblastic bone metastases (sensitivity 67 to 92%; specificity 80 to 99%), knowing that additional imaging procedures

are not uncommonly needed to determine the nature of such lesions.<sup>1,24</sup> Contrast-enhanced CT scan has a high sensitivity in the detection of visceral metastases, but small lesions may be missed. Generally, liver metastases from breast cancer are readily identified in the porto-venous phase on CT, although hypervascular lesions can potentially be missed. Sensitivity of CT for the detection of liver metastases is 92%; for bone metastases it is only 67%.<sup>1</sup> While ultrasound of the liver is considered appropriate, its limitations are mainly due to operator expertise, body habitus, patient compliance, and the evaluation of the subcostal area. Small lesions within a fatty or necrotic liver are difficult to depict.<sup>1</sup> Other investigations that are used in oncology are PET and PET/CT scan. Characterisation of malignant liver lesions is hampered by the fact that 18F-fluorodeoxyglucose (FDG) uptake in most lesions is as high as in healthy liver tissue. Therefore, small metastases, as well as lesions with low metabolic activity, can potentially be missed.<sup>25</sup> Sensitivity for detecting liver metastases is about 76%.<sup>1</sup> PET scan also has a relative low detection rate for bone metastases, especially those of the osteoblastic type.<sup>26</sup> Reported sensitivity to detect bone metastases is 87 to 92%, with a specificity of 92%.<sup>1,24</sup> Overall PET scan is superior to conventional imaging for detection of distant breast cancer metastases and its diagnostic performance is comparable with that of contrast-enhanced CT scan.<sup>1</sup> PET scan lacks precise anatomical localisation and morphological characterisation of metastases. This problem can be overcome by using a contrast-enhanced PET/CT scan. Another advantage of this combined investigation is that the entire patient is analysed during a single non-invasive total body investigation.<sup>1</sup>

In breast cancer, tumour-associated markers can reflect the total tumour cell load. They may help in determining prognosis and in monitoring response or resistance to specific therapies.<sup>27</sup> See *table 2* for more detailed discussion on the markers that were important in our patient.<sup>28-36</sup>

Oestrogen receptor expression is important for the behaviour of breast cancer cells and is reflected in gene expression patterns of breast tumours.<sup>37</sup>

The current, first-generation genomic prognostic markers, which were developed from combined analysis of all breast cancer subtypes, appear to classify almost all oestrogen receptor negative or grade 3 patients as high risk and therefore have limited value to risk stratify this clinical group. However, these molecular markers can subdivide oestrogen receptor positive breast cancers (with or without endocrine therapy) into lower- and higher-risk groups, and therefore if clinical variables are equivocal, they may provide some clinical value. Some recent data suggest that multivariate prognostic models including oestrogen receptor, HER2, and Ki-67, with or without tumour size and nodal status, determined in a central pathology

**Table 2. Haematological changes**

Marker	Discussion
LDH	Potential as marker of breast cancer activity. Involved in anaerobic glycolysis; tumour hypoxic environment with anaerobic metabolism. Serum levels 2-3 fold higher with localised disease, >5 fold with distant metastases. Level correlates well with tumour load. Increase is linked to poorer prognosis and survival rates. <sup>28-30</sup>
CA 15.3	Detect expression of MUC-1 antigen. Serial measurement can result in early detection of recurrent disease and indicate efficacy of therapy. Limited sensitivity and specificity. Concentrations are increased in about 10% of patients with stage I disease, 20% with stage II, 40% with stage III, and 75% with stage IV disease, but can also be increased in benign conditions; limiting its use for early stage breast cancer. <sup>27,31,32</sup> In 25-30% of metastatic disease no increase. Levels can increase before radiological or clinical evidence of disease relapse, but the contrary can also be true, especially in case of bone metastases. Unclear if introduction of early treatment improves overall survival or quality of life in case of metastatic disease. <sup>33,35</sup> Routine surveillance after primary surgery not recommend by most guidelines. <sup>27,32</sup>
Thrombocytopenia	Metastatic breast cancer with bone marrow involvement and pronounced thrombocytopenia as sole haematological abnormality is not often seen, although platelet depression can be the only finding of bone marrow metastases. Often accompanied by signs of suppressed erythropoiesis and leucopoiesis, elevated alkaline phosphatase and/or hypercalcaemia, but can be absent as in our case. <sup>36</sup>

laboratory could yield prognostic information very similar to the 21-Gene Recurrence Score assay.<sup>38,39</sup>

Another investigation that was false-negative at first was the pathology of the liver biopsy. The histopathology of biopsy tissue can provide otherwise unobtainable qualitative information regarding the structural integrity of the liver and the type and degree of injury and/or fibrosis.<sup>40</sup> There are several methods for procuring liver tissue: percutaneous, transjugular, laparoscopic, or ultrasound or CT-guided fine needle aspiration (FNA). It is common practice to obtain a prothrombin time, platelet count and a complete blood count prior to biopsy. In our patient, the thrombocytopenia was noticed too late. Significant intra-peritoneal haemorrhage is a serious complication of liver biopsy. Normally the risk is less than 0.1%. The biopsy specimen showed a necrotic hepatitis, most likely toxic in origin. It was only after an extra assessment with a cytokeratin 7 immunostain, a basic cytokeratin found on glandular and transitional epithelia and usually present in adenocarcinomas such as that of the breast and useful in discriminating primary from metastatic adenocarcinoma, that metastatic cells in the liver were also diagnosed. Hepatotoxicity can occur with a variety of drugs and other products,<sup>41-44</sup> such as those used in alternative medicine or in soft herbal remedies. Most adverse reactions take

place following a short exposure period, although they sometimes only become manifest after a longer period.<sup>41-</sup> Finally, a last item that has to be emphasised in this patient is that she had a mutation in exon 18 of the BRCA 1 gene. Several mutations are reported in the highly penetrating BRCA 1 and 2 genes (normally being involved in DNA repair). Although a positive family history is reported by 15 to 20% of women with breast cancer, only 5 to 6% of all breast cancers are associated with an inherited gene mutation.<sup>45</sup> Mutations are rare, occurring in approximately 0.3% of the general population, resulting in a tenfold increased risk of developing breast cancer. Somatic mutations in these genes or their expression products can also be involved in sporadic breast cancers. The clinical implication of the mutation retained in this patient is unknown for the moment, although the family history (ovarian cancer, breast and pancreatic cancer in first and second degree relatives) is very suggestive. As BRCA-related breast cancers are often early-onset breast cancers, detection rate in dense and dysplastic young breast tissue is challenging. Moreover, BRCA-associated breast cancers tend to exhibit histological and histochemical evidence of aggressive biological behaviour and to be highly proliferative leading to more interval cancers in comparison with the sporadic breast cancers. An expansive growth pattern with pushing borders seems a feature characterising the BRCA phenotype, which can sometimes make these tumours indistinguishable from fibroadenomas, appearing as well-defined, roundish, hypoechoic masses without acoustic shadowing on ultrasound, without associated microcalcifications on mammography and with strong wash-out phenomenon on breast MRI.<sup>46</sup> It is not known if there is an association between BRCA mutations and false-negative tests. In contrast to many BRCA 1 related breast cancers, our patient's breast cancer was not triple negative. In the future, further investigations of these 'unclassified variants are warranted.

## CONCLUSION

Our literature review highlights the relative sensitivity of the diagnostic tests we encounter in our daily practice managing breast cancer patients.

An explanation or reason for a specific diagnostic test being false-negative is not always clear, often multi-factorial, test-related or specific and clearly inherent to each particular test.

We believe that, if a patient is clinically suspect for a primary breast cancer or progressive disease, but imaging and biochemistry are not (yet) confirming this suspicion, the clinical status of the patient has to guide the physician for further diagnostic work-up. A suspect clinical sign is far more important than a negative technical result.

REFERENCES

1. Mahner S, Schirrmacher S, Brenner W, et al. Comparison between position emission tomography using 2-[fluorine-18]fluoro-2-deoxy-D-glucose, conventional imaging and computed tomography for staging of breast cancer. *Ann Oncol.* 2008;19:1249-54.
2. Nichols S, Waters WE, Fraser JD, Wheeler MJ, Ingham SK. Delay in the presentation of breast symptoms for consultant investigation. *Commun Med.* 1981;3:217-5.
3. Berg WA, Blume JD, Cormack JB, et al. Combined Screening with Ultrasound and Mammography vs Mammography alone in Women at Elevated Risk of Breast Cancer. *JAMA.* 2008;299:2151-63.
4. Kolb Tm, Lichy J, Newhouse JH. Comparison of the performance of screening mammography, physical examination, and breast US and evaluation of factors that influence them: an analysis of 27,825 patient evaluations. *Radiology.* 2002;225:165-75.
5. Wang JM, Chang KJ, Kuo WH, Lee HT, Ting-Fang Shih T. Efficacy of Mammographic Evaluation of Breast Cancer in Women less than 40 years of Age: Experience from a Single Medical Center in Taiwan. *J Formos Med Assoc.* 2007;106:736-47.
6. Houssami N, Irwig L, Simpson JM, et al. Sydney Breast Imaging Accuracy Study- comparative sensitivity and specificity of mammography and sonography in young women with symptoms. *Am J Roentgenol.* 2003;180:935-40.
7. Flobbe K, Bosch AM, Kessels AG, et al. The additional diagnostic value of ultrasonography in the diagnosis of breast cancer. *Arch Intern Med.* 2003;163:1194.
8. Macleod U, Mitchell ED, Burgess C, Macdonald S, Ramirez AJ. Risk factors for delayed presentation and referral of symptomatic cancer: evidence for common cancers. *Br J Cancer.* 2009;101(Suppl 2):S92-S101.
9. Richards MA, Smith P, Ramirez AJ, Fentiman IS, Rubens RD. The influence on survival of delay in the presentation and treatment of symptomatic breast cancer. *Br J Cancer.* 1999;79:858-64.
10. Richards MA, Westcombe AM, Love SB, Littlejohns P, Ramirez AJ. Influence of delay on survival in patients with breast cancer: a systematic review. *Lancet.* 1999;353:1119-26.
11. Joensuu H, Asola R, Holli K, Kumpulainen E, Nikkanen V, Parvinen LM. Delayed diagnosis and large size of breast cancer after a false negative mammogram. *Eur J Cancer.* 1994;30A(9):1299-302.
12. Kavanagh AM, Giles GG, Mitchell H, Cawson JN. The sensitivity, specificity, and positive predictive value of screening mammography and symptomatic status. *J Med Screen.* 2000;7(2):105-10.
13. Murphy [fill in reference]
14. Bluemke DA, Gatsonis CA, Chen MH, et al. Magnetic resonance imaging of the breast prior to biopsy. *JAMA.* 2004;292:2735-42.
15. Peters NH, Borel Rinkes IH, Zuithoff NP, et al. Meta-analysis of MR imaging in the diagnosis of breast lesions. *Radiology.* 2008;246:116-24.
16. Fredholm H, Eaker S, Frisell J, Holmberg L, Fredriksson I, Lindman H. Breast cancer in young women: poor survival despite intensive treatment. *PLoS One.* 2009;4(11):e7695.
17. Lanng C, Hoffmann J, Galatius H, Engel U. Assessment of clinical palpation of the axilla as a criterion for performing the sentinel node procedure in breast cancer. *ESJO.* 2007;33:281-4.
18. Specht MC, Fey JV, Borgen PI, Cody III HS. Is the clinically positive axial in breast cancer really a contraindication to sentinel lymph node biopsy? *J Am Coll Surg.* 2005;200:10-4.
19. Voogd AC, Coebergh J-WW, Repelaer van Driel OJ, et al. The risk of nodal metastases in breast cancer patients with clinically negative lymph nodes: a population-based analysis. *Breast Cancer Res Treat.* 2000;62:63-9.
20. Alvarez S, Anorbe E, Alcorta P, Lopez F, Alonso I, Cortés J. Role of sonography in the diagnosis of axillary lymph node metastases in breast cancer: a systematic review. *Am J Radiol.* 2006;186:1342-8.
21. Barranger E, Coutant C, Flahault A, Delpech Y, Darai E, Uzan S. An axilla scoring system to predict non-sentinel lymph node status in breast cancer patients with sentinel lymph node involvement. *Breast Cancer Res Treat.* 2005;91(2):113-9.
22. Fein DA, Fowble BL, Hanlon AL, et al. Identification of women with T1-T2 breast cancer at low risk of positive axillary nodes. *Surg Oncol.* 1997;65(1):34-9.
23. Ravdin PM, De Laurentis M, Vendely T, Clark GM. Prediction of axillary lymph node status in breast cancer patients by use of prognostic indicators. *J Nat Cancer Inst.* 1994;86:1771-5.
24. Gallowitsch HJ, Kresnik E, Gasser J, et al. F-18 fluorodeoxyglucose positron-emission tomography in the diagnosis of tumor recurrence and metastases in the follow-up of patients with breast carcinoma: a comparison to conventional imaging. *Invest Radiol.* 2003;38:250-6.
25. Brix G, Ziegler SI, Bellemann ME, et al. Quantification of [18F]FDG uptake in the normal liver using dynamic PET: impact and modelling of the dual hepatic blood supply. *J Nucl Med.* 2001;42:1265-73.
26. Cook GJ, Houston S, Rubens R, et al. Detection of bone metastases in breast cancer by 18FDG PET: differing metabolic activity in osteoblastic and osteolytic lesions. *J Clin Oncol.* 1998;16:3375-9.
27. Duffy MJ. Serum tumor markers in breast cancer: Are they of clinical value? *Clin Chem.* 2006;52:345-51.
28. Harris AL. Hypoxia: a key regulatory factor in tumour growth. *Nat Rev Cancer.* 2002;2:38-47.
29. Seth RK, Kharb S, Kharb DP. Serum biochemical markers in carcinoma breast. *Ind J Med Sol.* 2003;57:350-4.
30. Lee YT. Biochemical and haematological tests in patients with breast carcinoma: correlations with extent of disease, site of relapse, and prognosis. *J Surg Oncol.* 1985;29:242-8.
31. Sturgeon CM, Lai LC, Duffy MJ. Serum tumour markers: how to order and interpret them. *BMJ.* 2009;339:b3527.
32. Harris L, Fritsche H, Mennel R, et al. American Society of Clinical Oncology 2007. Update of Recommendations for the Use of Tumor Markers in Breast Cancer. *J Clin Oncol.* 2007;25:5287-312.
33. Nicolini A, Carpi A, Michelassi C, et al. Tumor marker guided salvage treatment prolongs survival of breast cancer patients: final report of a 7-year study. *Biomed Pharmacother.* 2003;57:452-9.
34. Kovner F, Merimsky O, Hareuveni M, et al. Treatment of disease negative but mucin like carcinoma associated antigen positive breast cancer patients with tamoxifen: preliminary results of a prospective controlled randomized trial. *Cancer Chemother Pharmacol.* 1994;35:80-3.
35. Chourin S, Veyret C, Chevier A, et al. Routine Use of serial plasmatic CA 15-3 determinations during the follow-up of patients treated for breast cancer. Evaluation as factor of early diagnosis of recurrence. *Ann Biol Clin (Paris).* 2008;66:385-92.
36. Sar R, Aydogdu I, Ozen S, et al. Metastatic bone marrow tumours: a report of six cases and review of the literature. *Hematologia (Budap).* 2001;31:215-23.
37. Kok M, Linn SC. Gene expression profiles of the oestrogen receptor in breast cancer. *Neth Med J.* 2010;68:291-302.
38. Bueno-de-Mesquita JM, van Harten WH, Retel VP, et al. Use of 70-gene signature to predict prognosis of patients with node-negative breast cancer: a prospective community-based feasibility study (RASTER). *Lancet Oncol.* 2007; 8:1079-87.
39. Goldstein LJ, Gray R, Badve S, et al. Prognostic utility of the 21-gene assay in hormone receptor-positive operable breast cancer compared with classical clinicopathologic features. *J Clin Oncol* 2008;26:4063-71.
40. Bravo AA, Sheth SG, Chopra S. Liver biopsy. *N Engl J Med.* 2001;344:495-500.
41. Zapata E, Zubiaurre L, Bujanda L, Pierola A. Anastrozole-induced hepatotoxicity. *Eur J Gastroenterol Hepat.* 2006;18:1233-4.
42. Harvey J, Colin-Jones DG. Mistletoe hepatitis. *Br Med J. (Clin Res Ed).* 1981;282:186-7.
43. Lasso De La Vega MC, Zapater P, Such J, et al. Toxic hepatitis associated with tamoxifen use. A case report and literature review. *Gastroenterol Hepatol.* 2002;25:247-50.
44. Murata Y, Ogawa Y, Saibara T, et al. Tamoxifen induced non-alcoholic steatohepatitis in patients with breast cancer: determination of a suitable biopsy for diagnosis. *Oncol Rep.* 2003;10:97-100.
45. Malone KE, Daling JR, Thompson JD, et al. BRCA1 mutations and breast cancer in the general population: Analyses in women before age 35 years and in women before age 45 years with first-degree family history. *JAMA.* 1998;279:922-9.
46. Kuhl CK. Familial breast cancer: what the radiologist needs to know. *Breast.* 2005;14:480-6.

Coolen, et al. False-negative tests in breast cancer management.